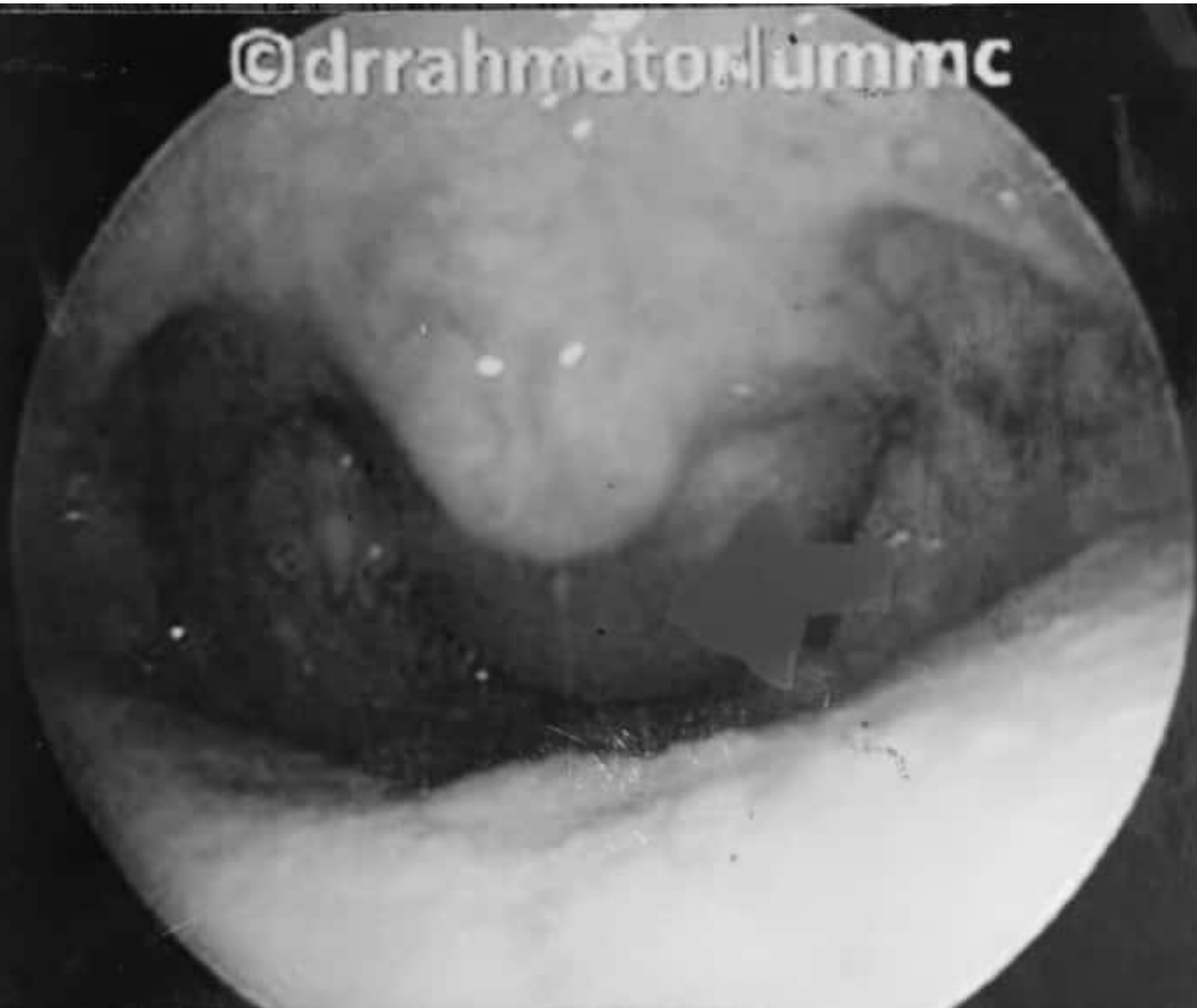
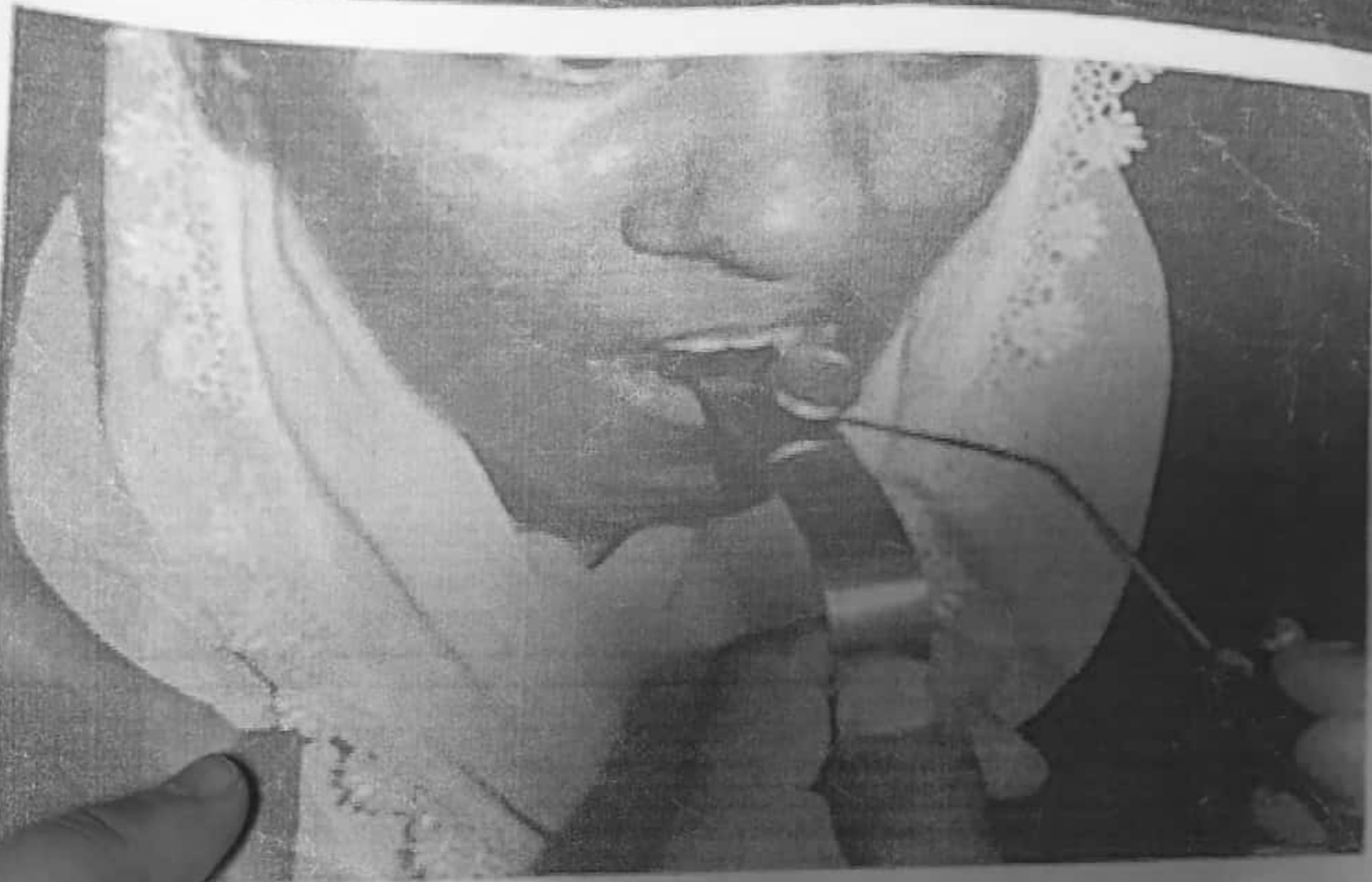
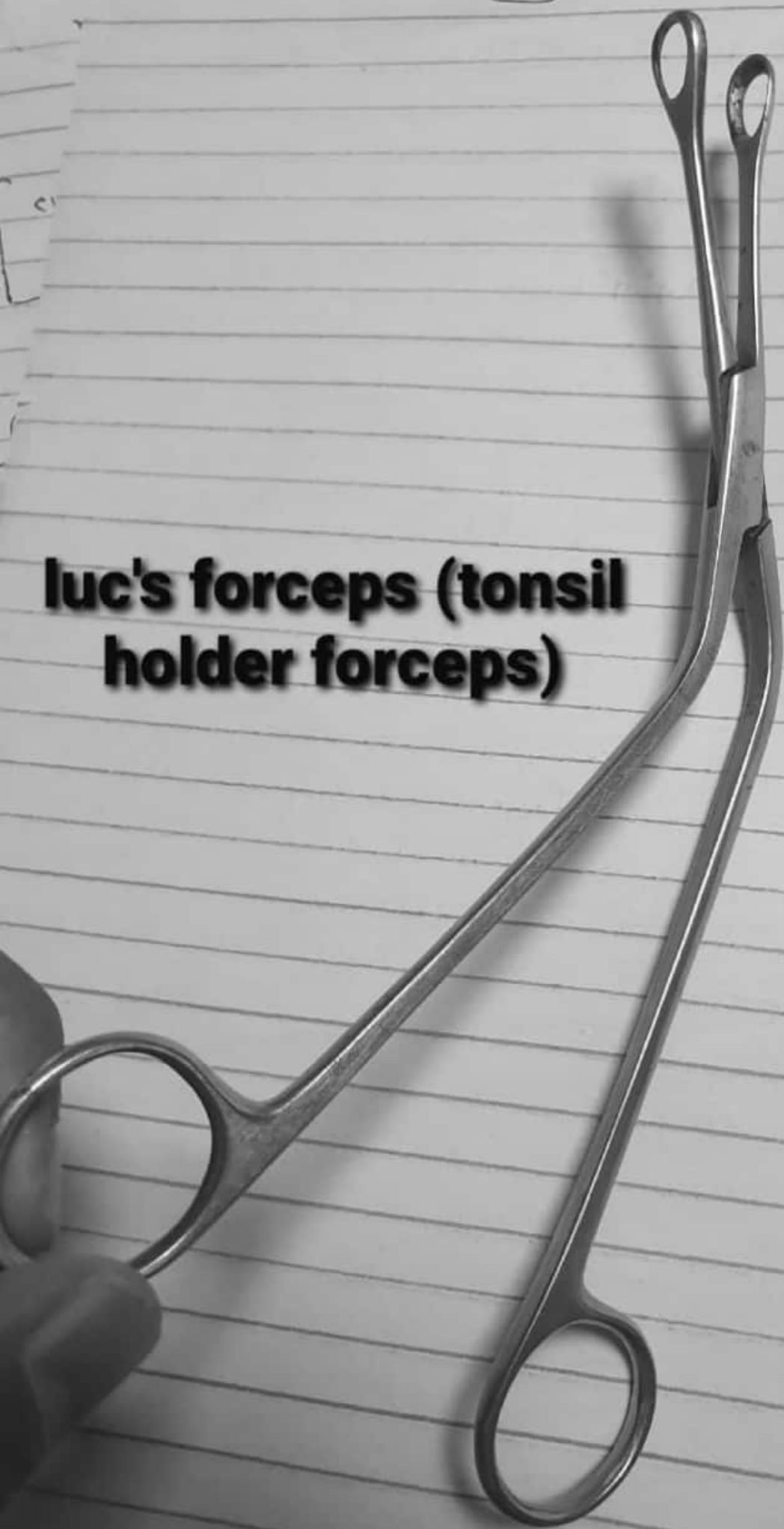©drrahmatonlummc



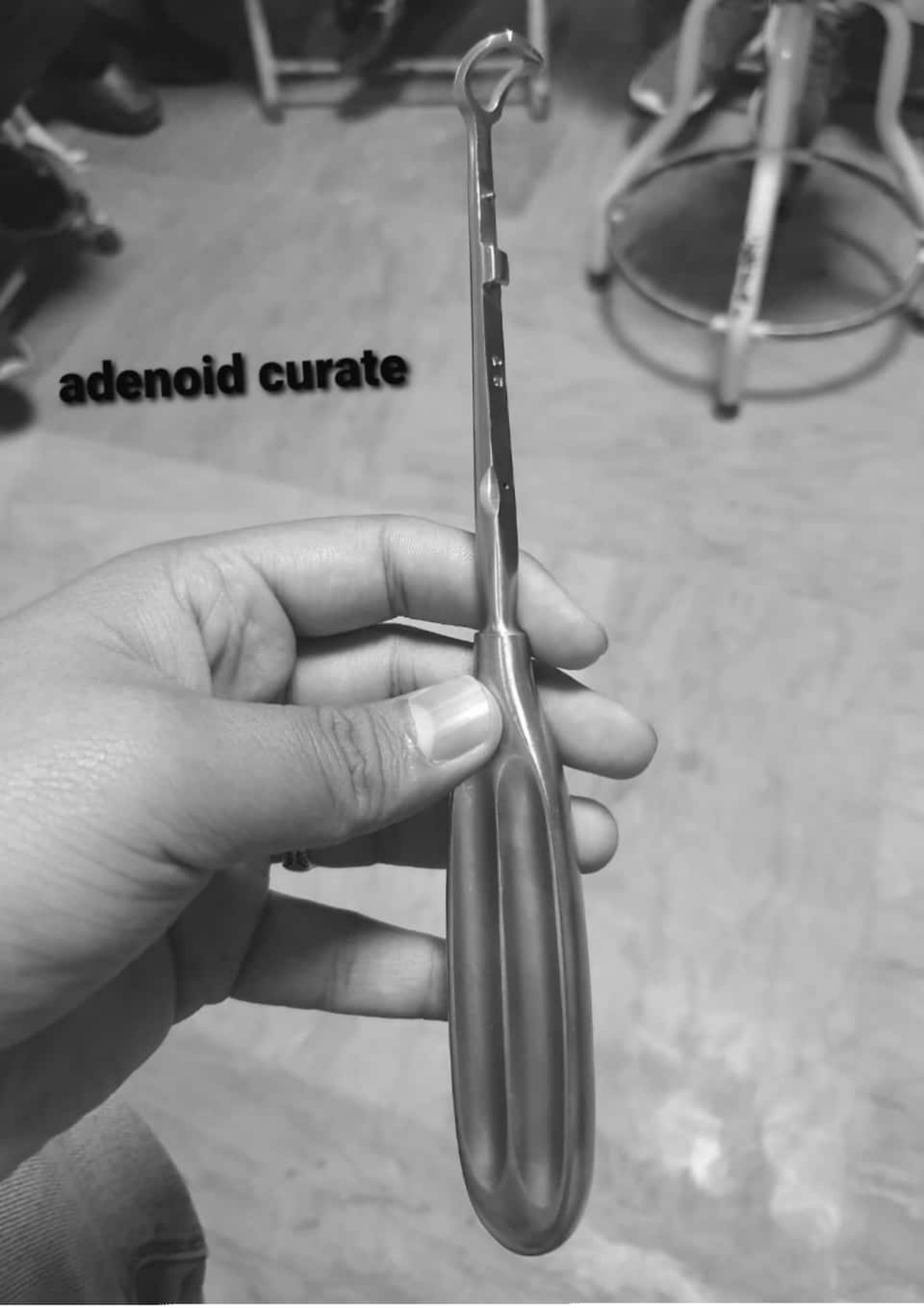posterior rhinoscopy



**luc's forceps (tonsil
holder forceps)**



adenoid curate



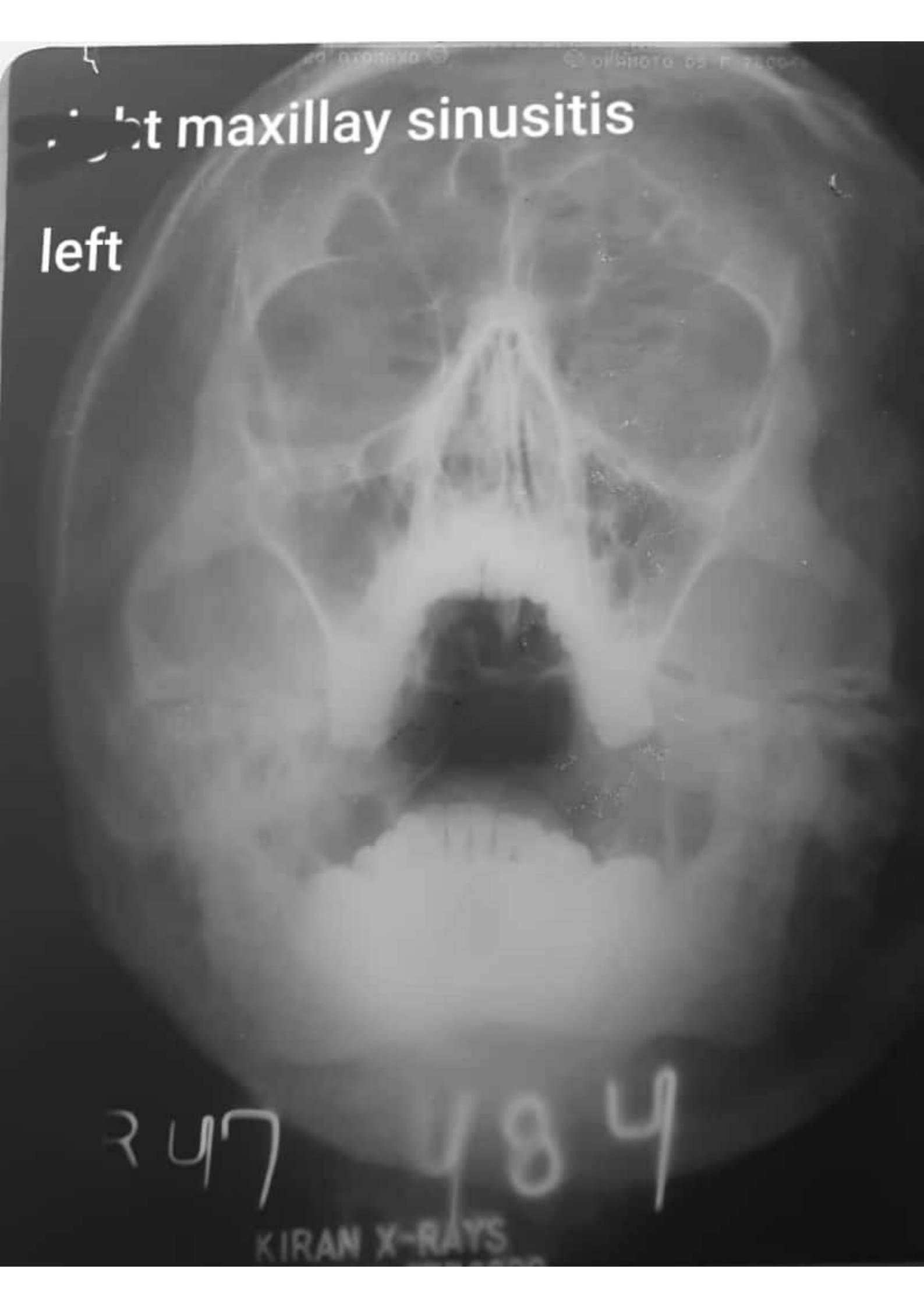right maxillary sinusitis

left

R 47

484

KIRAN X-RAYS

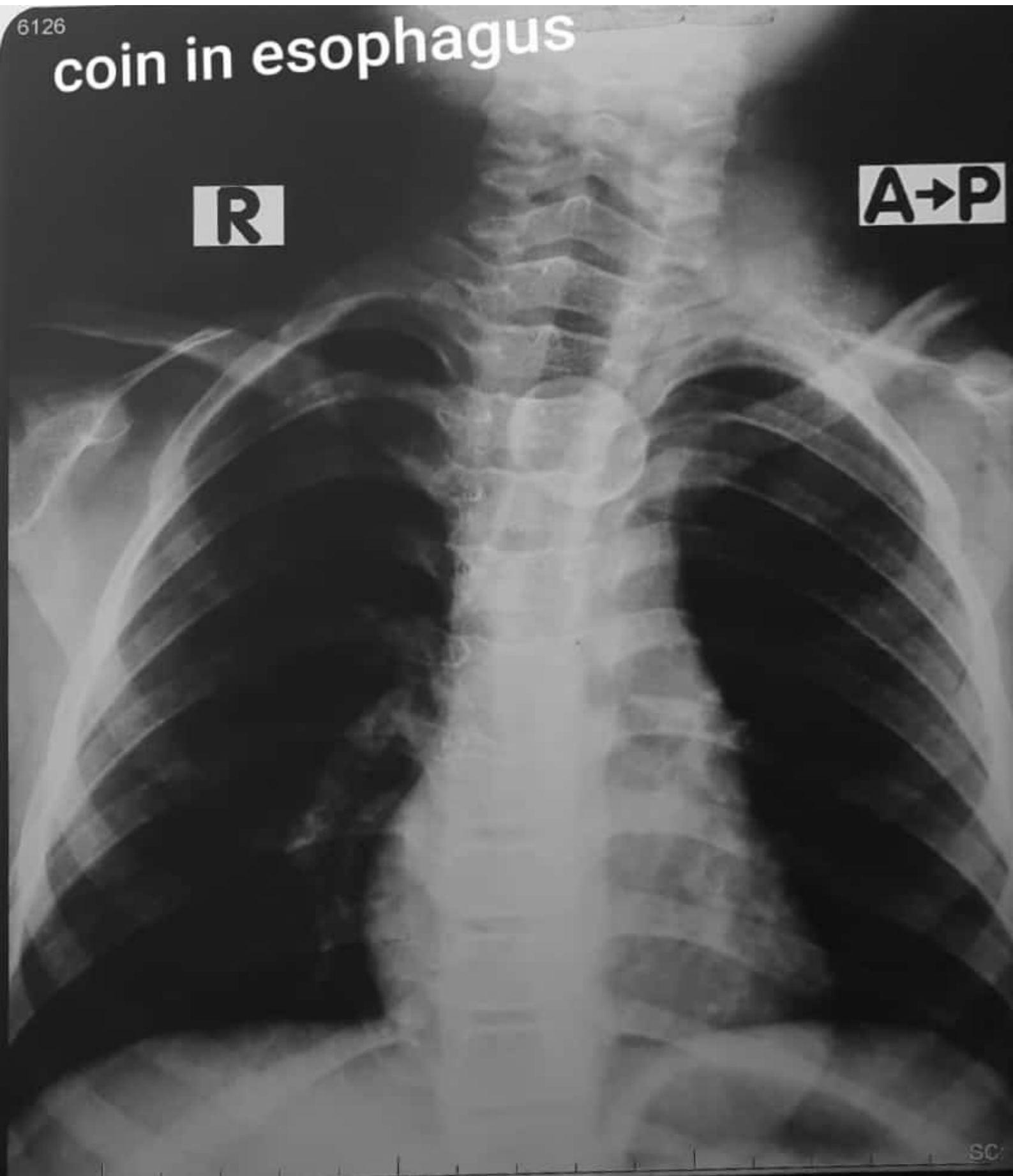

6126

coin in esophagus

R

A→P

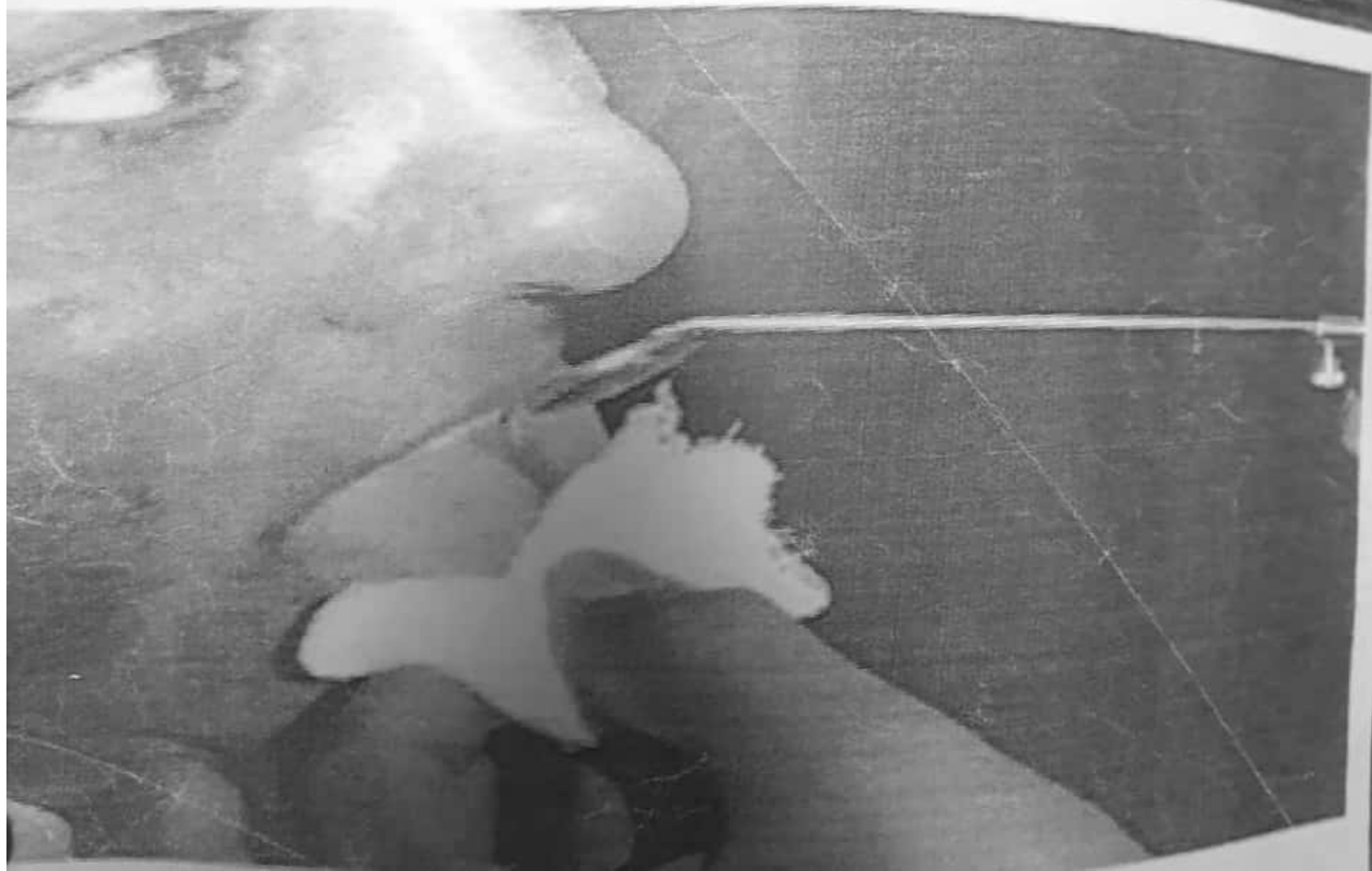


SC

canula

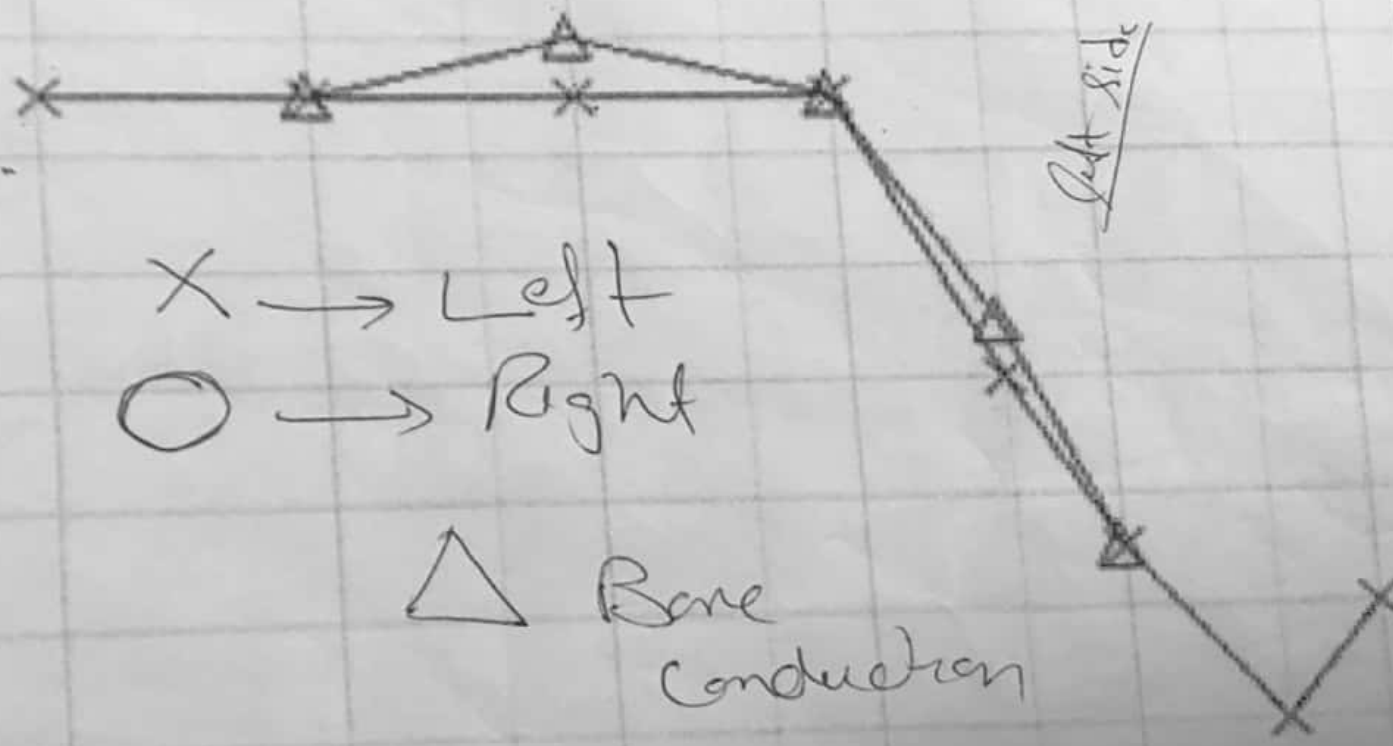


indirect laryngoscopy



0
10
20
30
40
50
60
70
80
90
100
110

~~Sensory~~ Conductive Hearing Loss



x → Left

o → Right

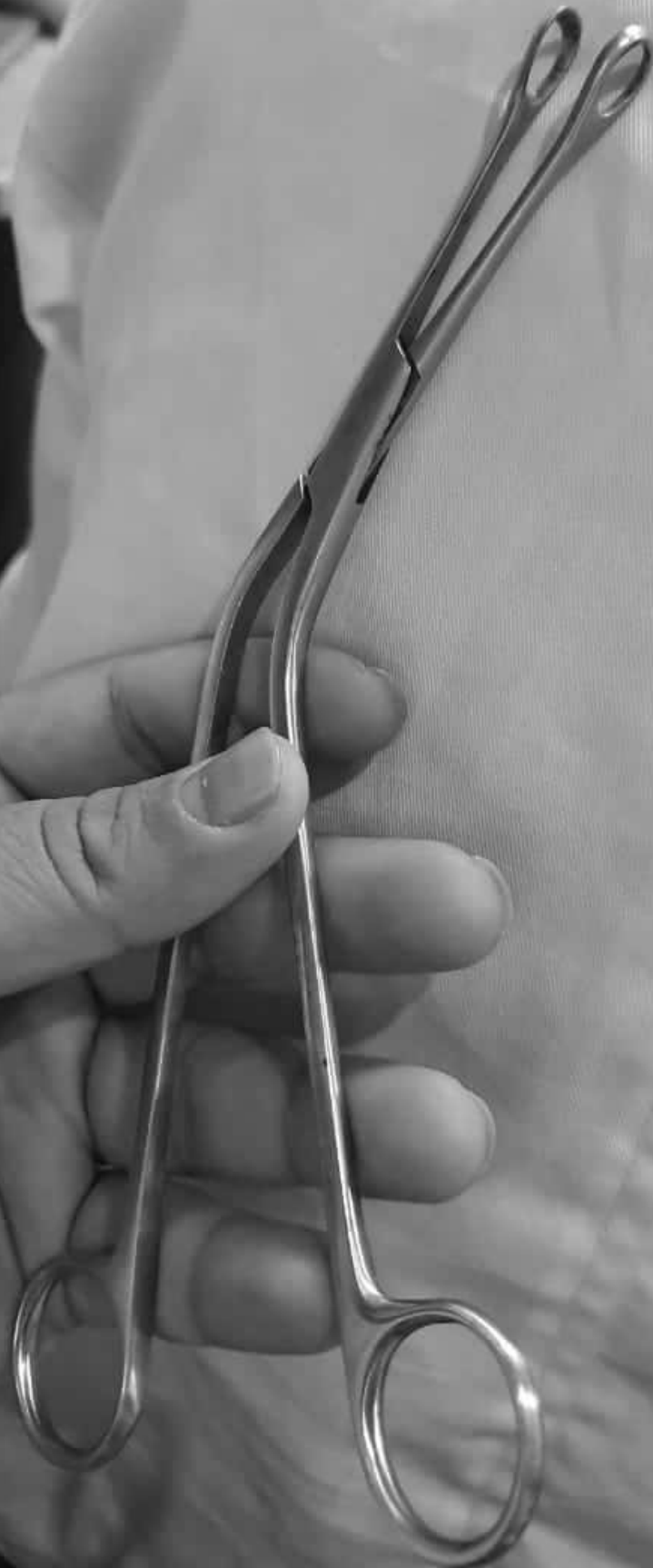△ Bone Conduction

left side



Child endotracheal tube

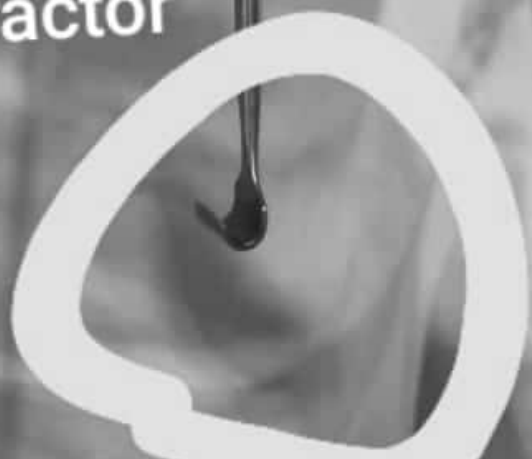luck's forceps(tonsils holder
forceps)



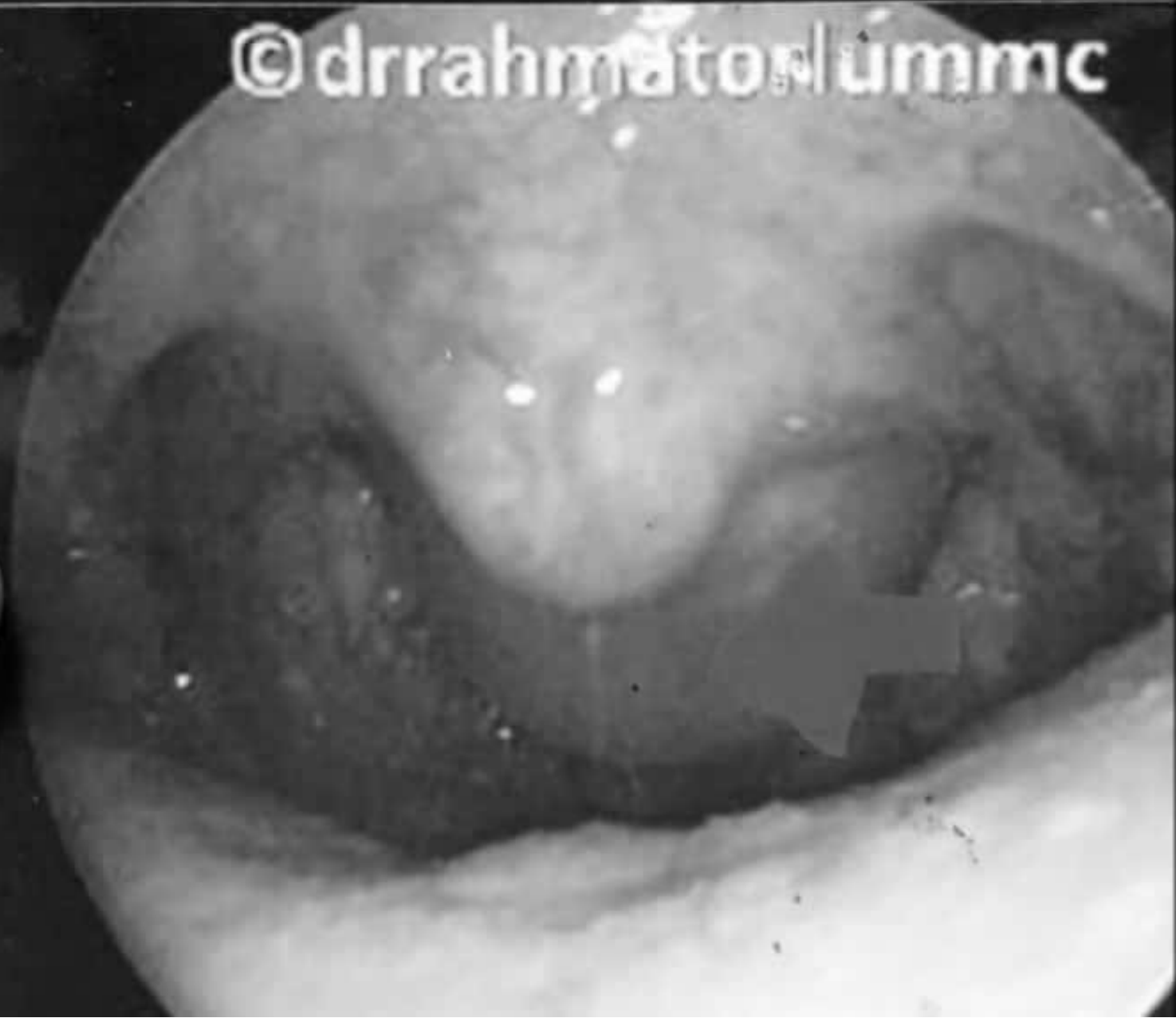tonsillar pillar disector



tonsillar pillar retractor



©drrahmatonlummc



Peritonsillar abscess

A black and white photograph of a white, L-shaped airway tube inside its clear plastic packaging. The tube has a curved end and a straight end. The packaging is crinkled and partially open. A hand is visible at the bottom, holding the tube. Three horizontal black bars with white text are overlaid on the image.

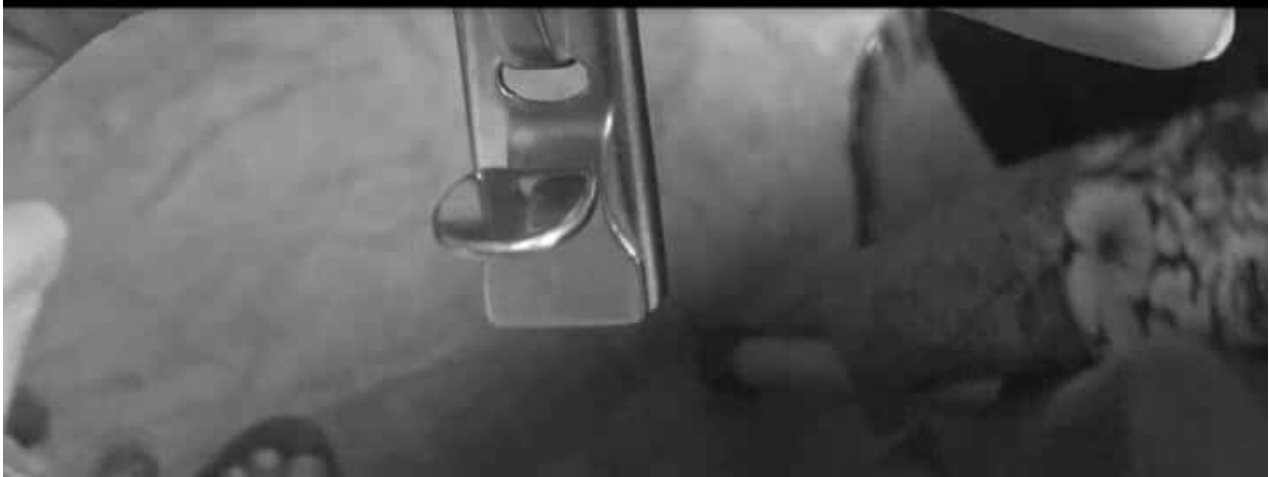Airway tube

Airway maintain

Tongue bite tongue fall



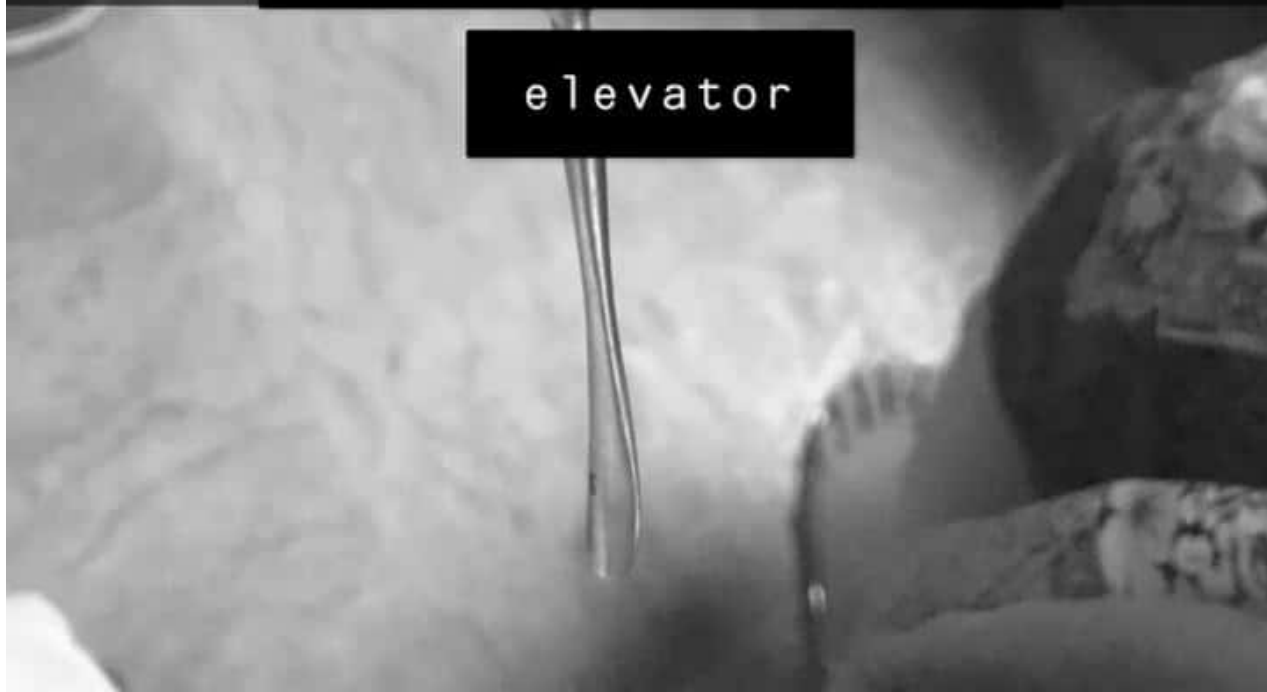Boyle devis mouth gag





Freer's double ended

elevator



Tilley's forcep



***Nasal packing, ear dressing,
removal of foreign bodies
from nose***

Topodignostic
test-Shrimer
test
taste test
submandibula
r flow rate
stepedial
reflex

Treatment-
Reassurance
to patient
care of eye
physiotherapy
fascial
muscles
massage
steroids
fascial nerve
decompressio
n

Causes-Bells
palsy
trauma
ramsay hunt
syndrome
tumors
infections
central
causes
mysthenia
gravis

Complication
s-crocodile
tears
incomplete
recovery
tics nd
spasms
exposure
keratitis
synkinesis
freys
syndrome

right facial nerve paralysis



Topodignostic
test-Shrimer
test
taste test
submandibula
r flow rate
stepedial
reflex

Treatment-
Reassurance
to patient
care of eye
physiotherapy
facial
muscles
massage
steroids
facial nerve
decompressio
n

Causes-Bells
palsy
trauma
ramsay hunt
syndrome
tumors
infections
central
causes
mysthenia
gravis

Complication
s-crocodile
tears
incomplete
recovery
tics nd
spasms
exposure
keratitis



Facial Nerve Paralysis

synkinesis
freys
syndrome

Complications:

- Crocodile tears
- Incomplete recovery
- Spasm

right facial nerve paralysis

- Keratitis
- Frey's Syndrome

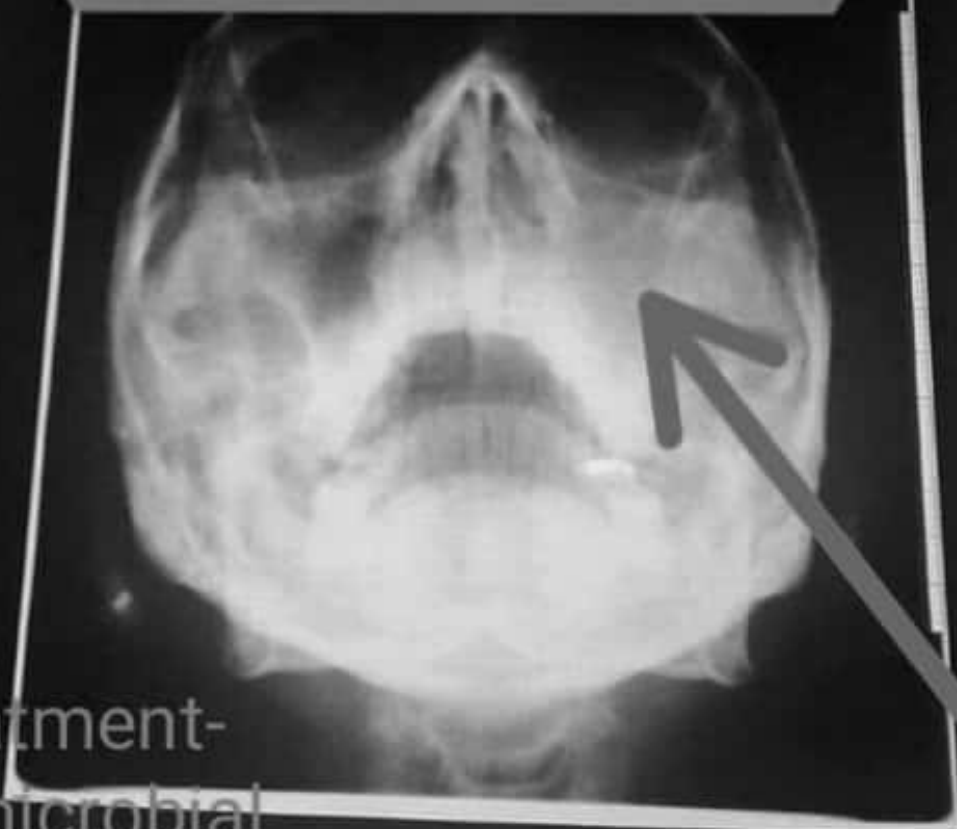LUC'S forceps

Use in caldwell luc
operation



Cause-Viral rhinitis
Diving and swimming in
contaminated water

Maxillary sinusitis



Treatment-
Antimicrobial

Nasal
decongestants

drops

steam inhalation


analgesics

hot fomentations

Antral lavage

Complication-
Chronic sinusitis
Orbital cellulitis
Osteomyelitis

First Digital Dental Imaging © Cardex Hospital, Jail Road Lahore, Opp. Kinnaird
SHAMOON.SHAMOON-05.05.1980 01XC 19.07.2012 10:47:34 10501184.TIF



عمر خان علی

Slide: anterior rhinoscopy

Follow

0 DE HL

Figure

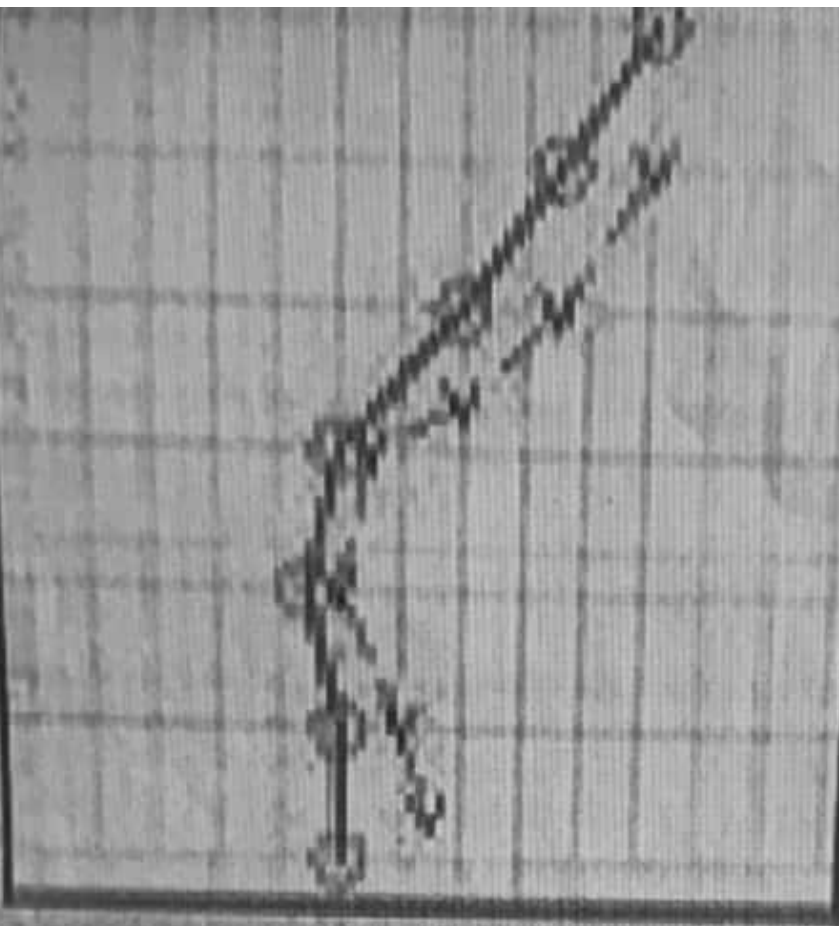
250 Hz

01

10 20 30 40 50 60 70 80 90 100

Progress

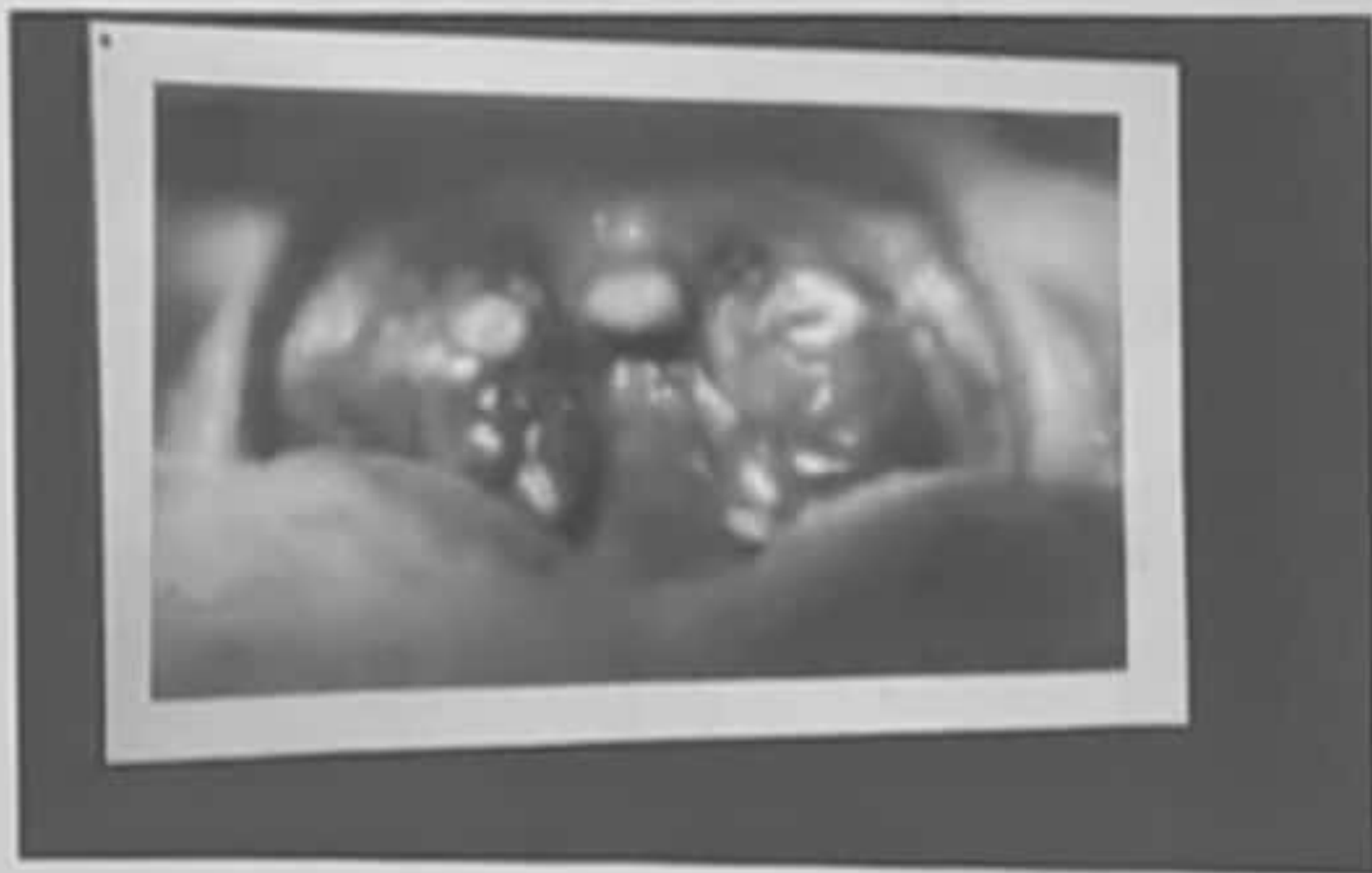
20 30 40 50 60 70 80 90 100



Mixed SNHL



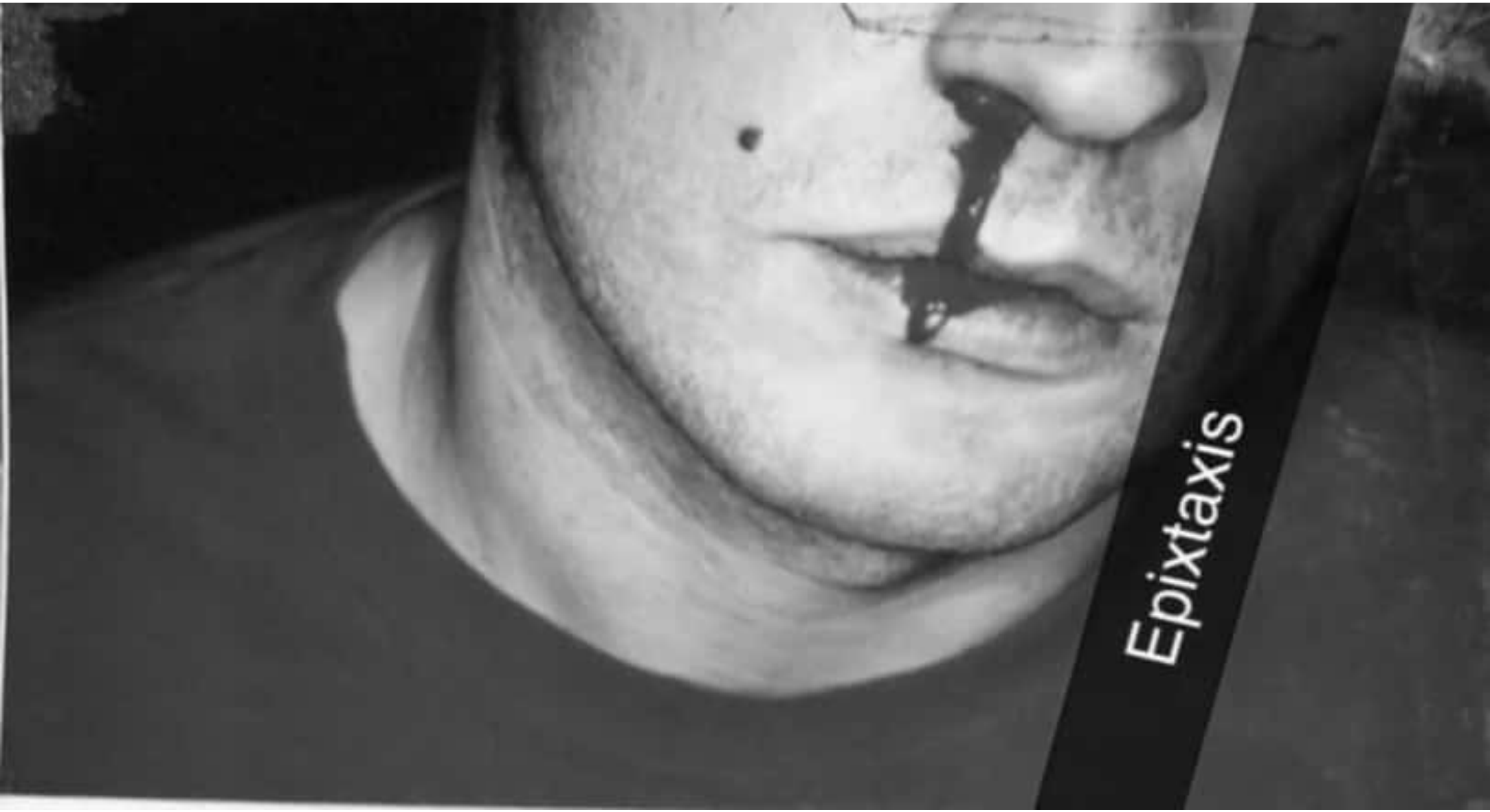Slide: acute follicular tonsillitis



عمر خان

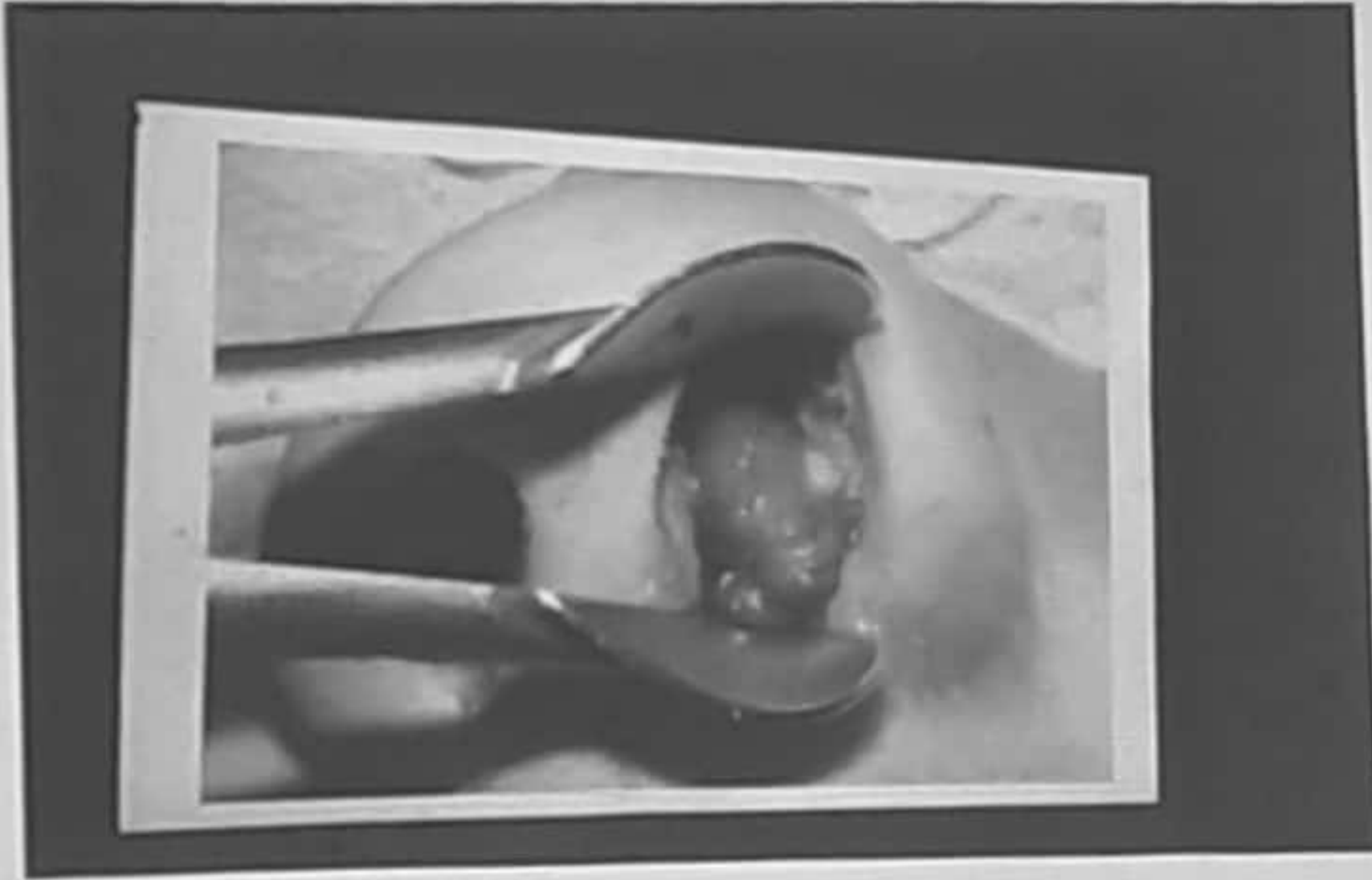Slide: Endotracheal tube

Follow

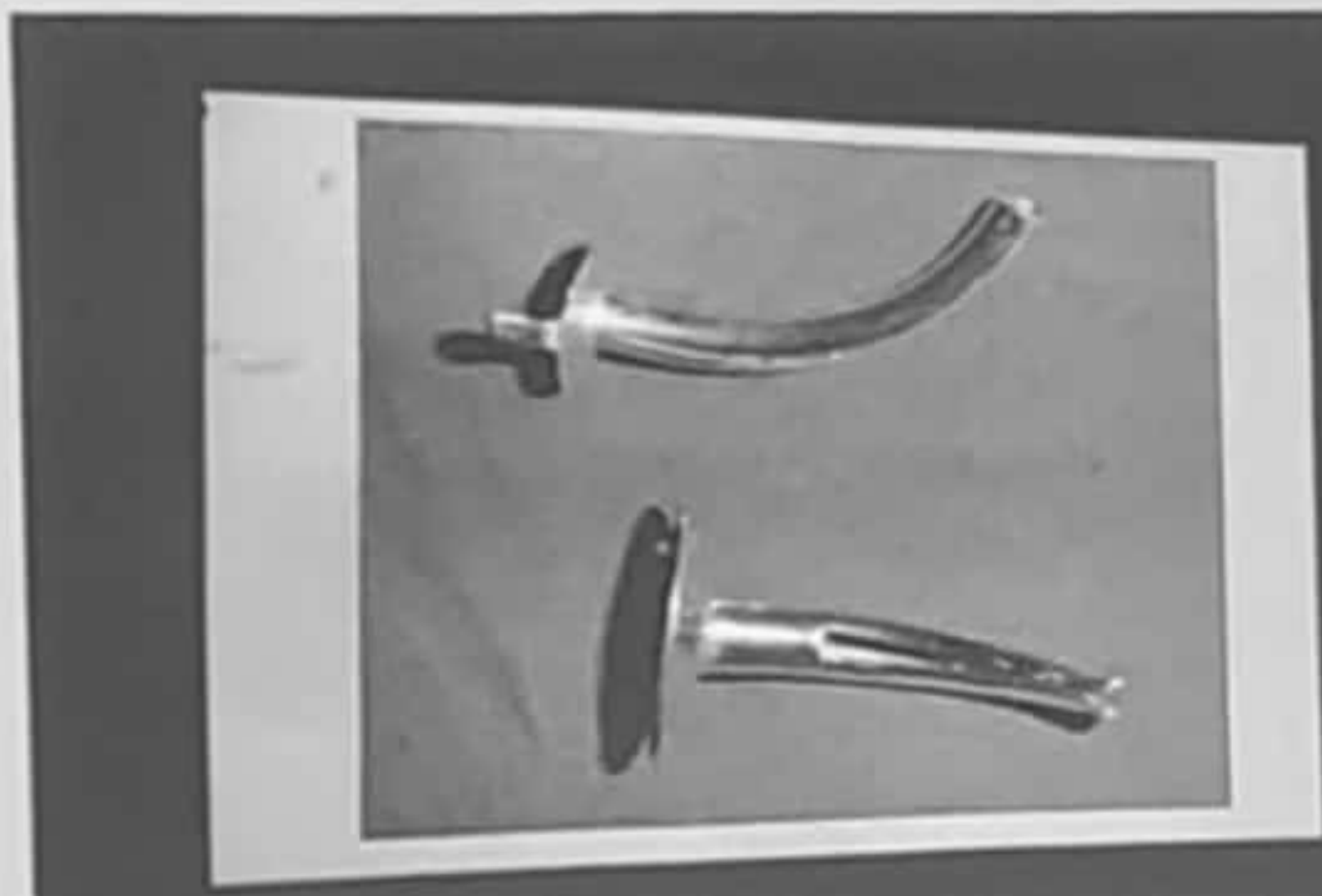


Epixtaxis


Slide: posterior rhinoscopy Nasal polyp



Slide: tracheostomy tube .. metallic



Slide: mass at glottis



عمر ماں خیر

class.



Myringotomy

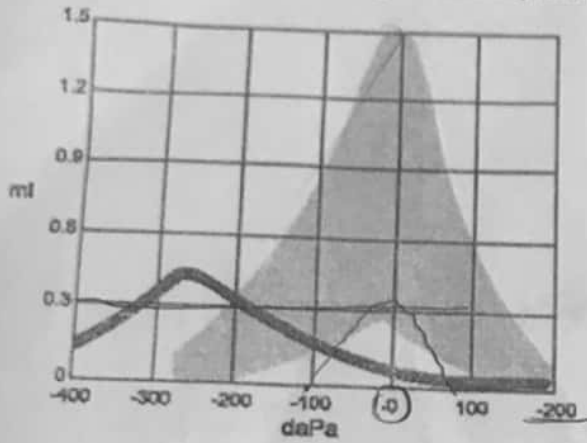
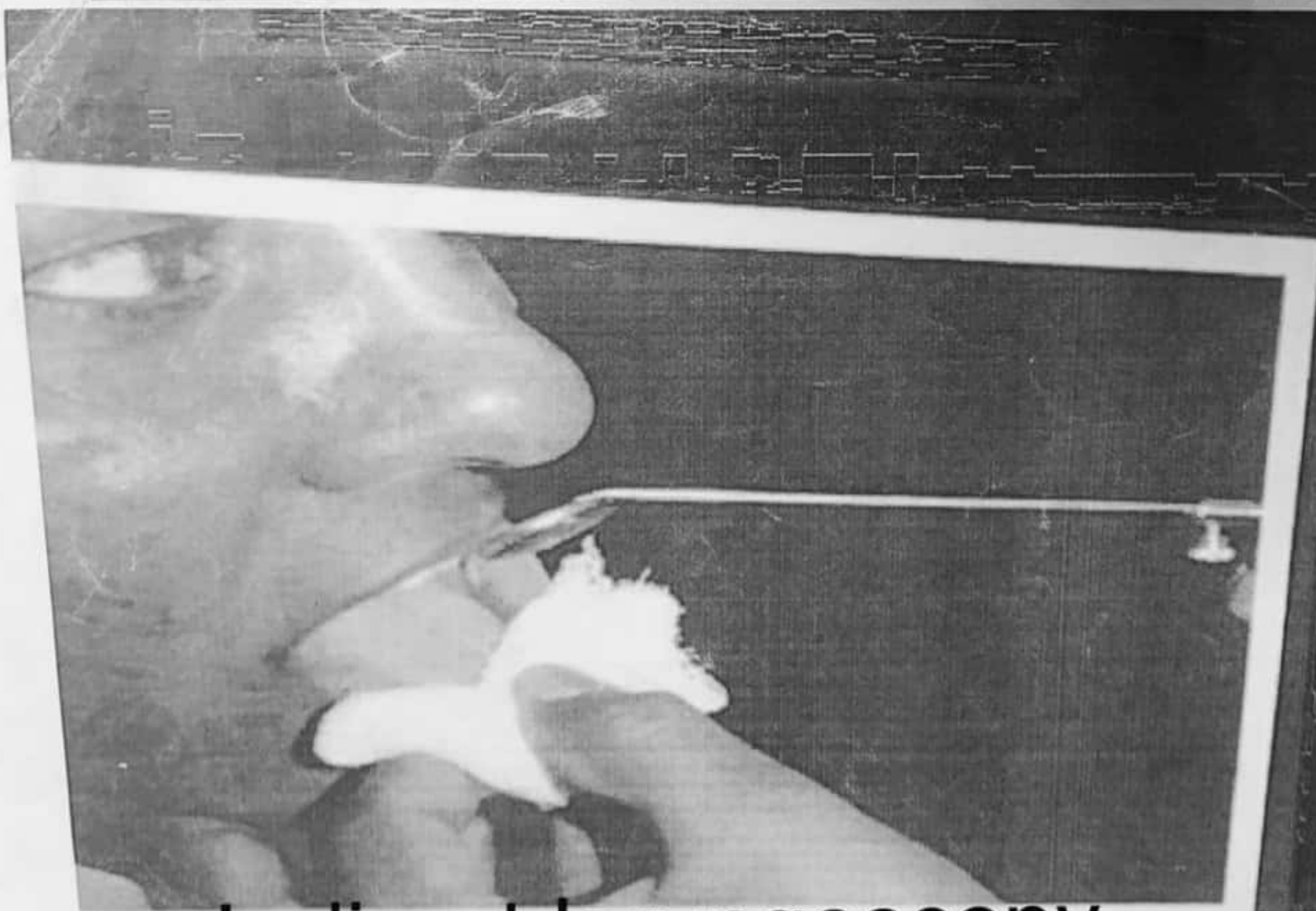


Figure 3. Type C tympanogram

References

- Jerger, J.F. (1970). Clinical experience with impedance audiometry. *Archives of Otolaryngology*, 92, 311-324.
- Liden, G. (1969). The scope and application of current audiometric tests. *Journal of Laryngology and Otology*, 83, 507-520.
- Jen Duffey, M.S., CCC-A has been an audiologist for Maico-Diagnostics (www.maico-diagnostics.com) for three years. She provides audiological support and education, input for new product design and function, and technical assistance. Previously, she worked for three years as an educational audiologist providing clinical services to students, ages 2 to 21 years old.

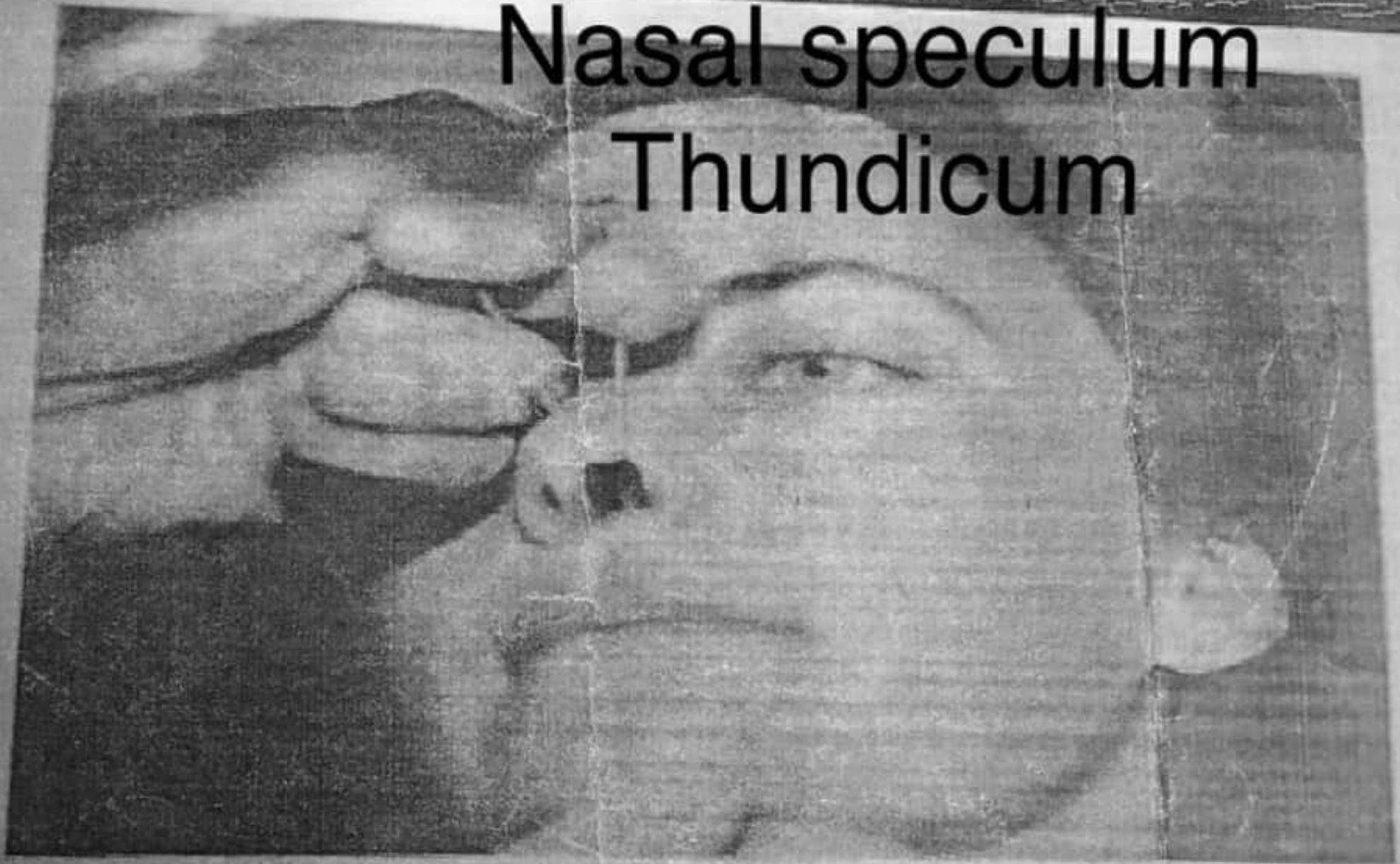


Indirect laryngoscopy

Anterior rhinoscopy

Nasal speculum

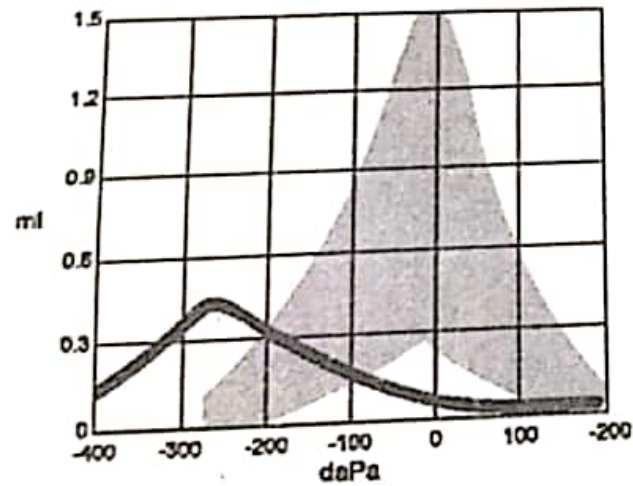
Thundicum

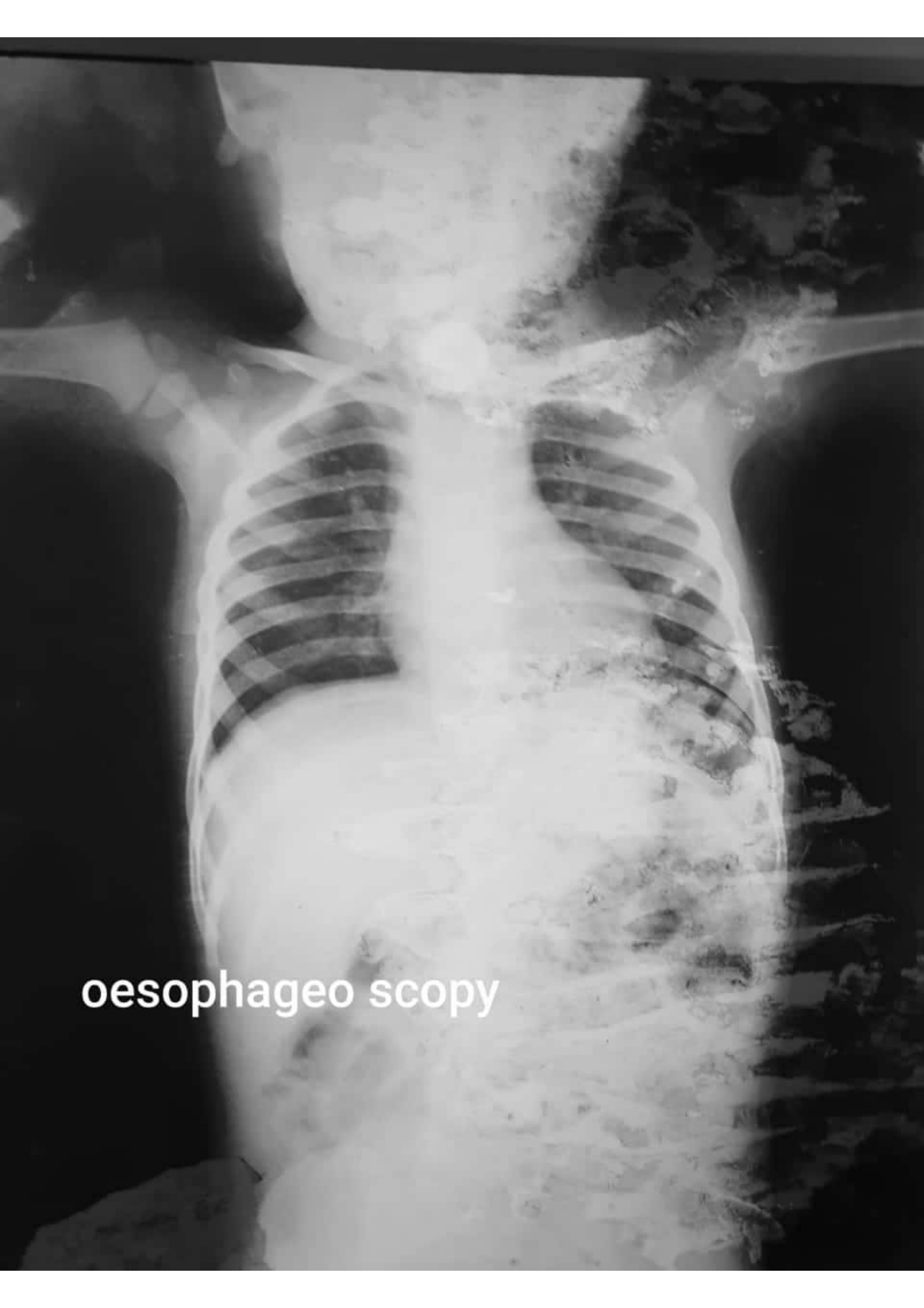

Station *2*

A-IDENTIFY THE GRAPH

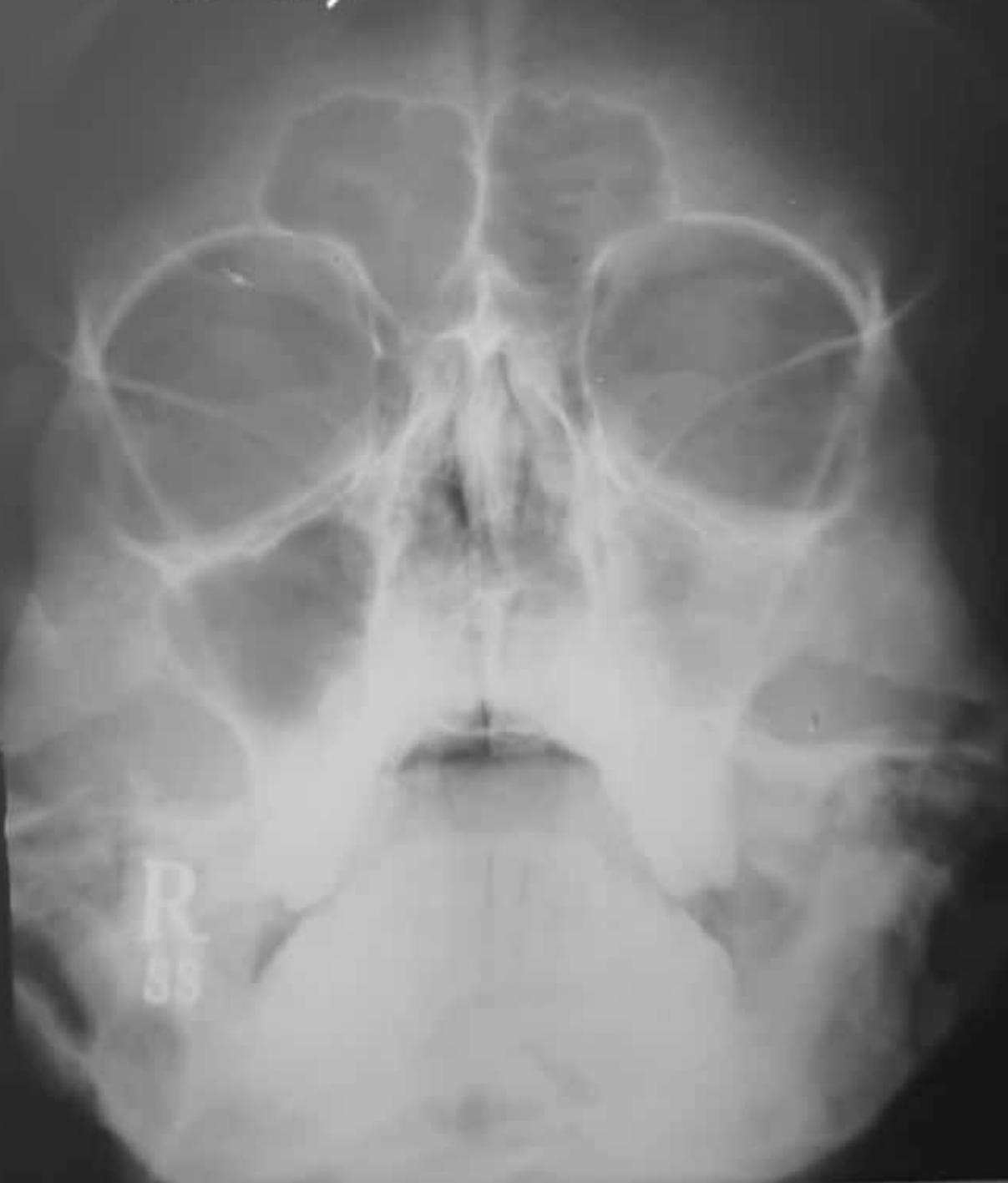B-WRITE DOWN TREATMENT





oesophagoscopy

xray of paranasal sinus
pus in left maxillary sinus
occipitofrontal view(waters
view) OM View



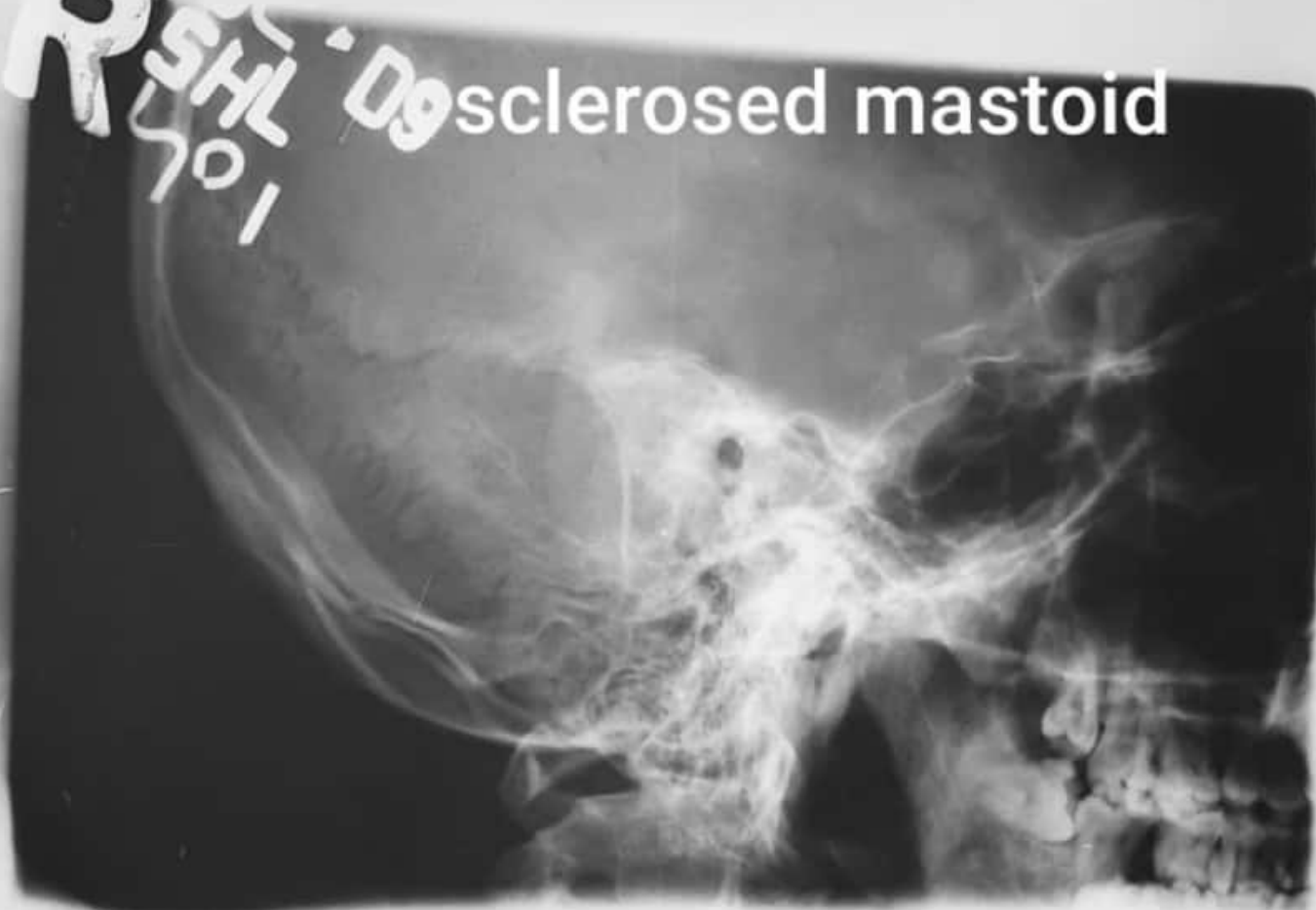Dr. Ziauddin Hospita
No. 1000
10.10.04
Room 102

R
58

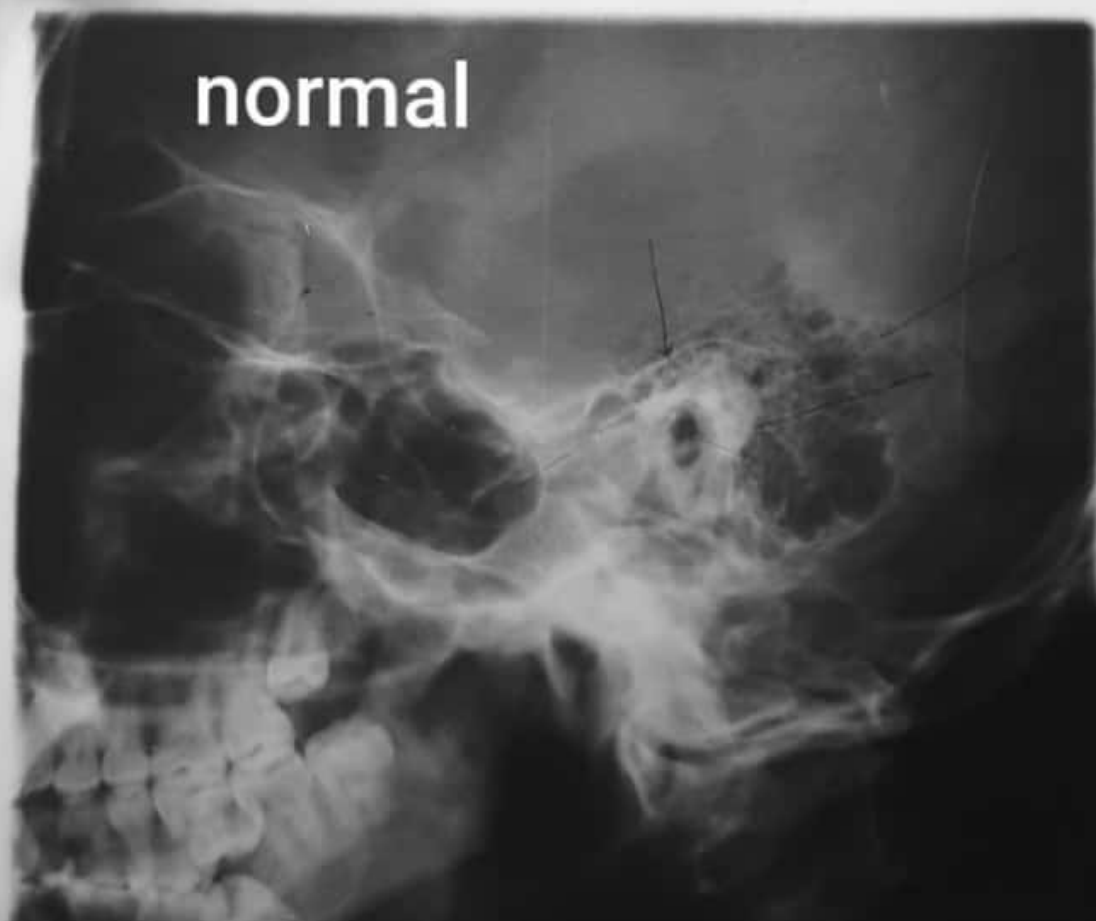
xray mastoid

R
SHL
501

sclerosed mastoid



normal



right ear

Surgeons poly clinic

Audiograph

Dr Zafar Iqbal ENT Consultant (FCPS)

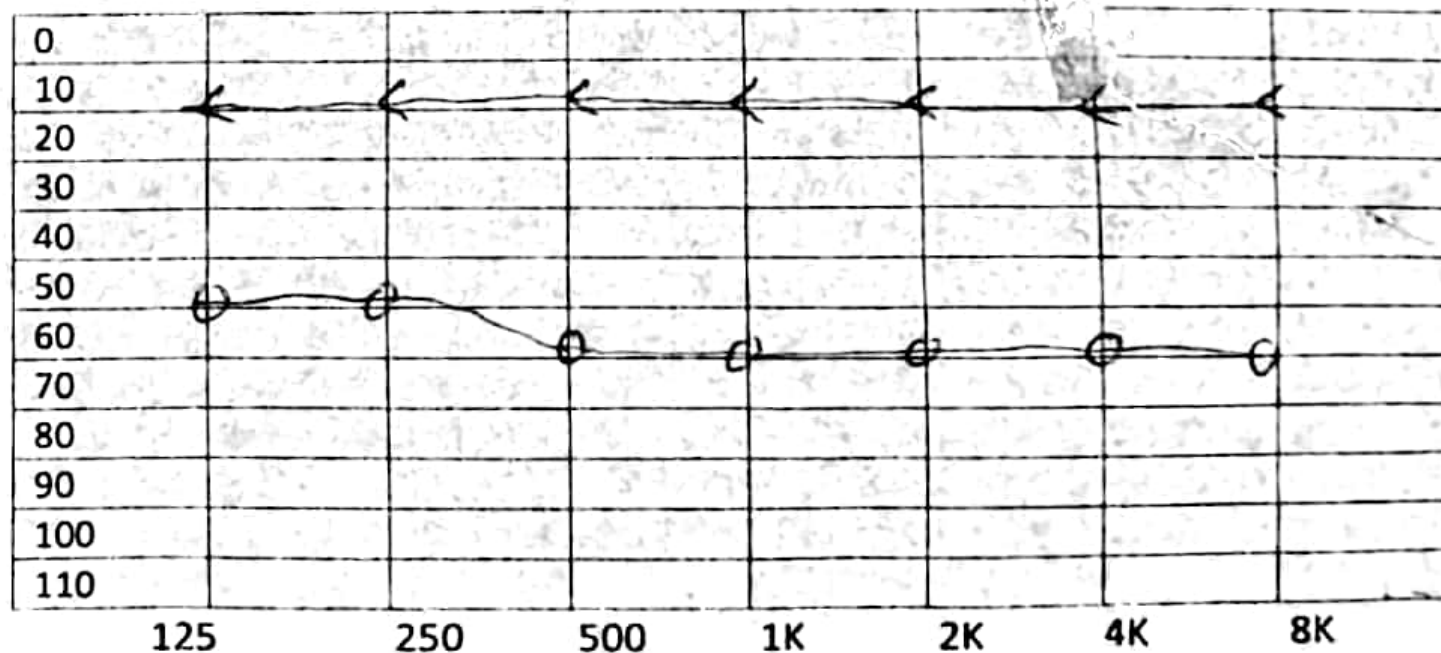
422 Q BLOCK MODEL TOWN LAHORE

PH 0308-4213201.

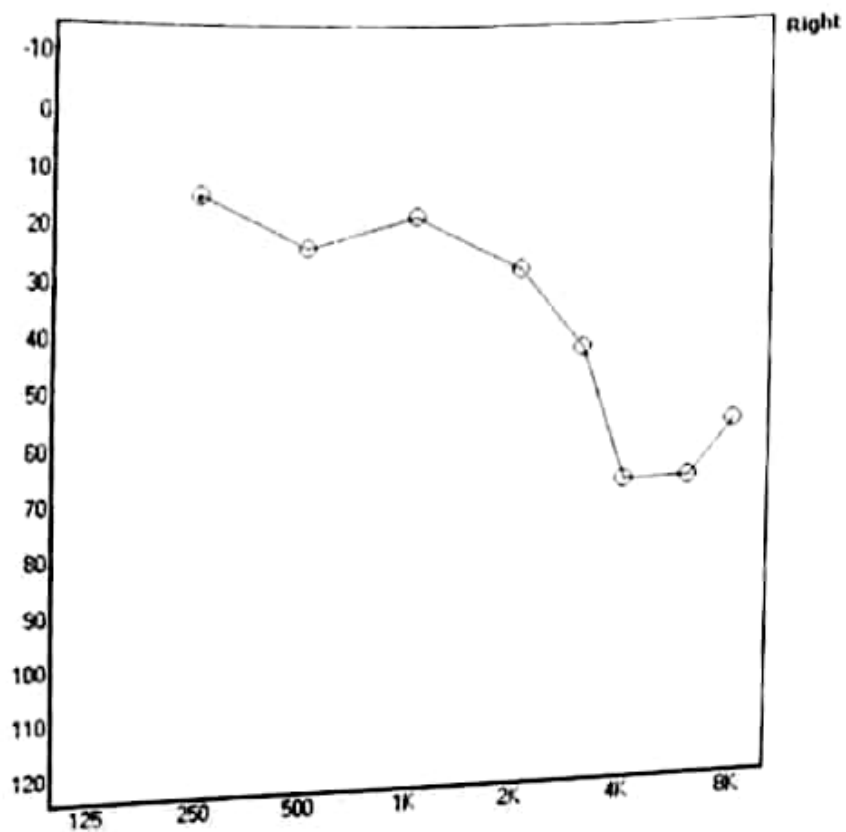
pt name--- age----- sex----- address-----

Diagnosis-----

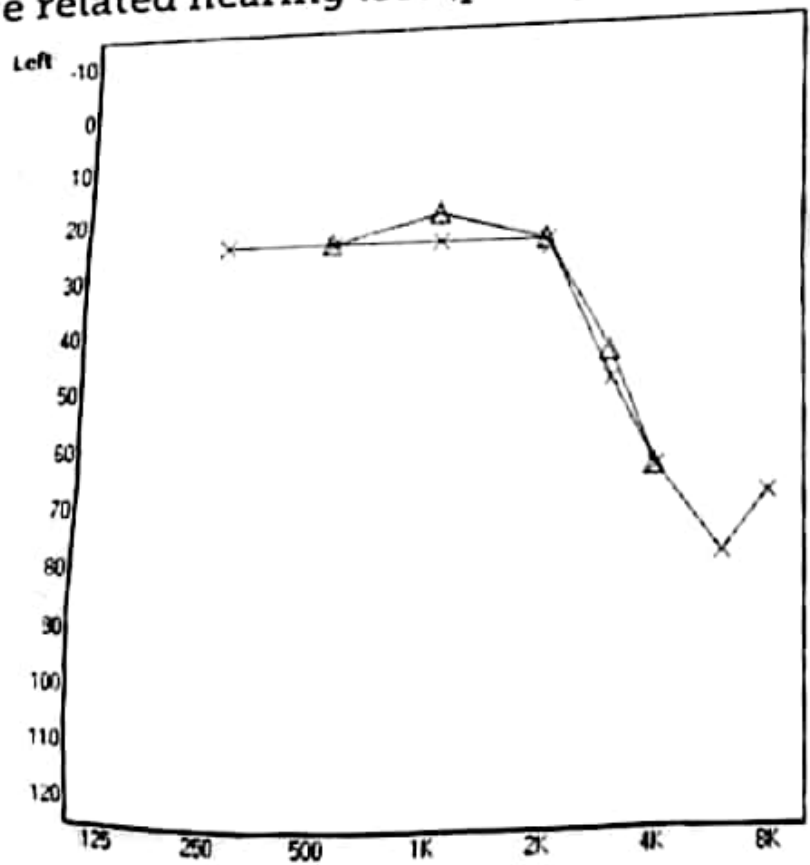
Loudness(db) Right Ear

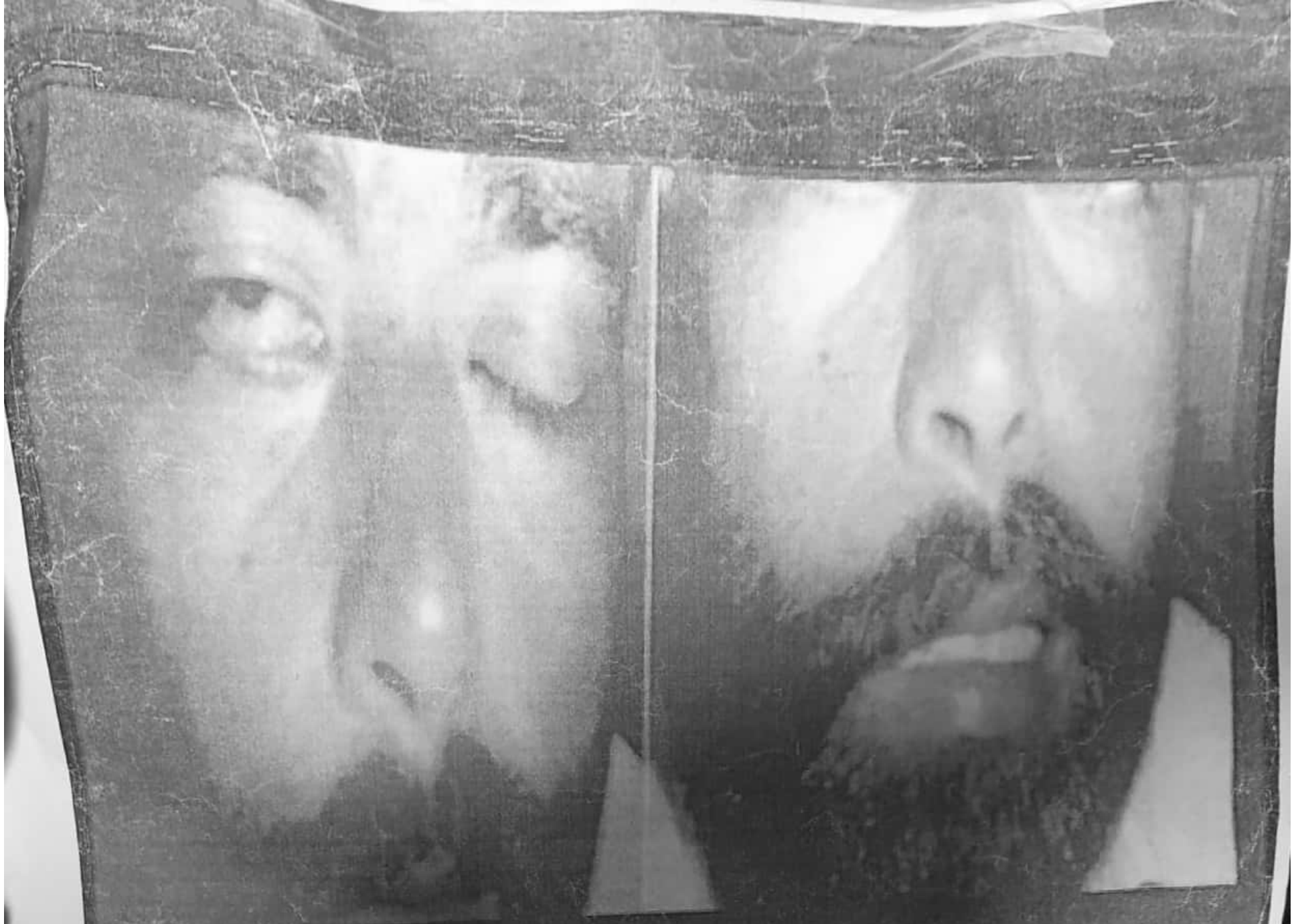

Frequency (HZ)



(b) Left sided age related hearing loss (presbycusis)






facial nerve paralysis

POSTERIOR

ANTERIOR



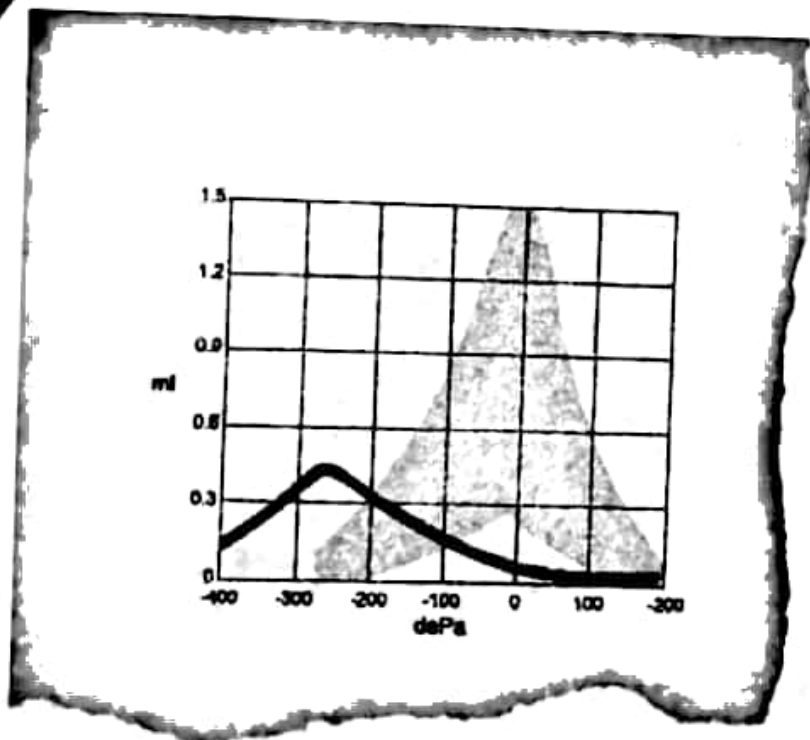
Auriscopic (Lateral) View

Station

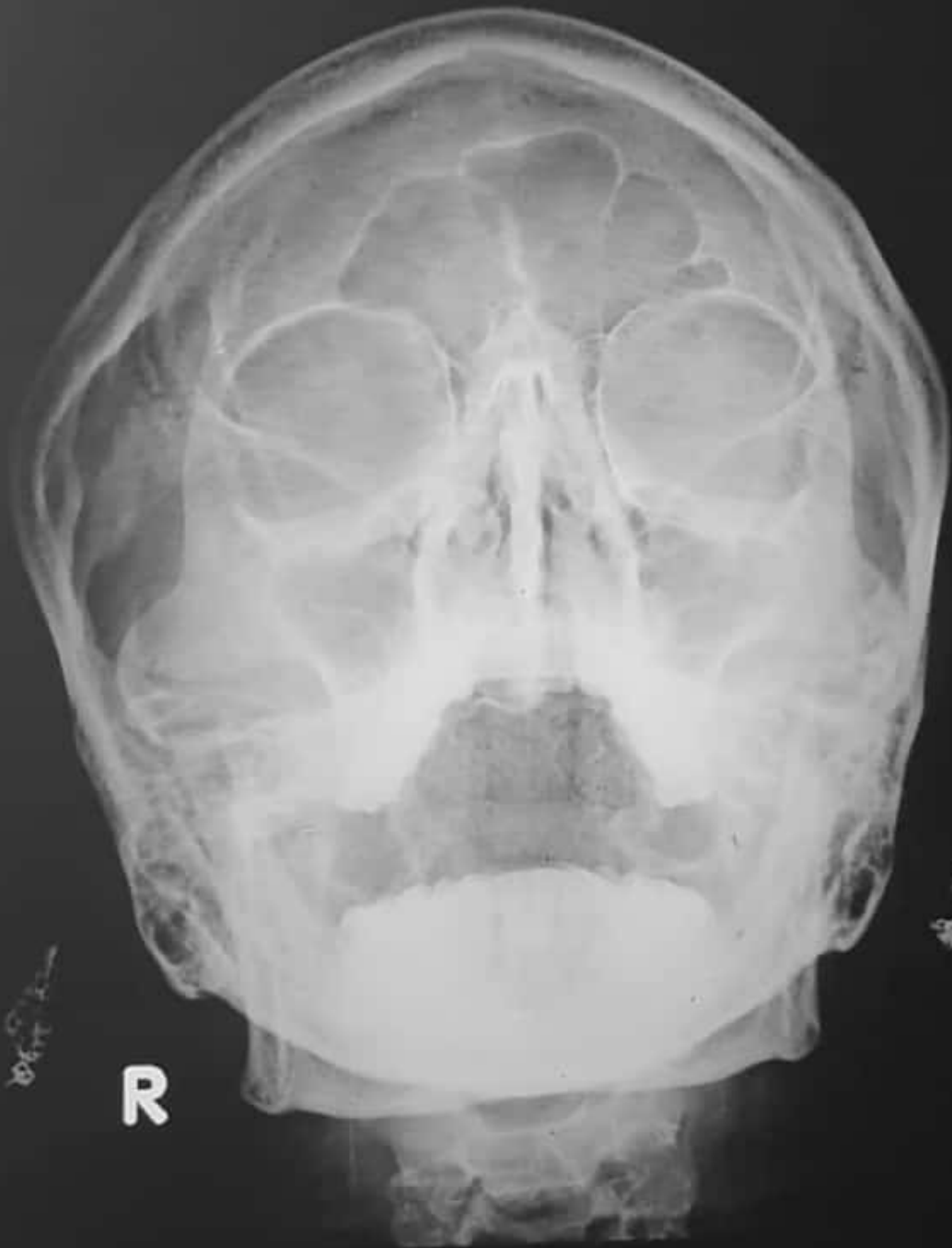typanogram type C

A-IDENTIFY THE GRAPH

B-WRITE DOWN TREATMENT



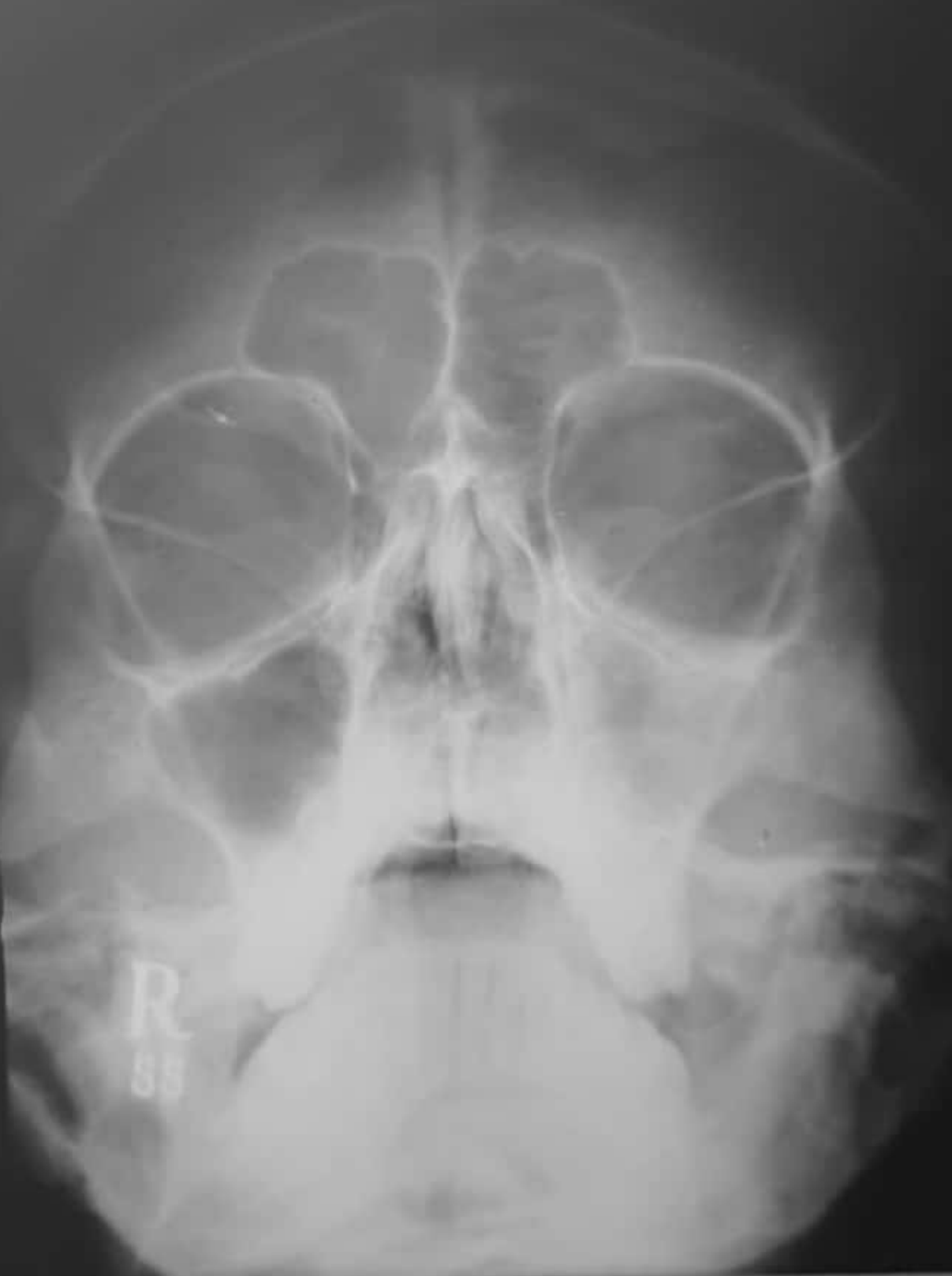normal sinuses

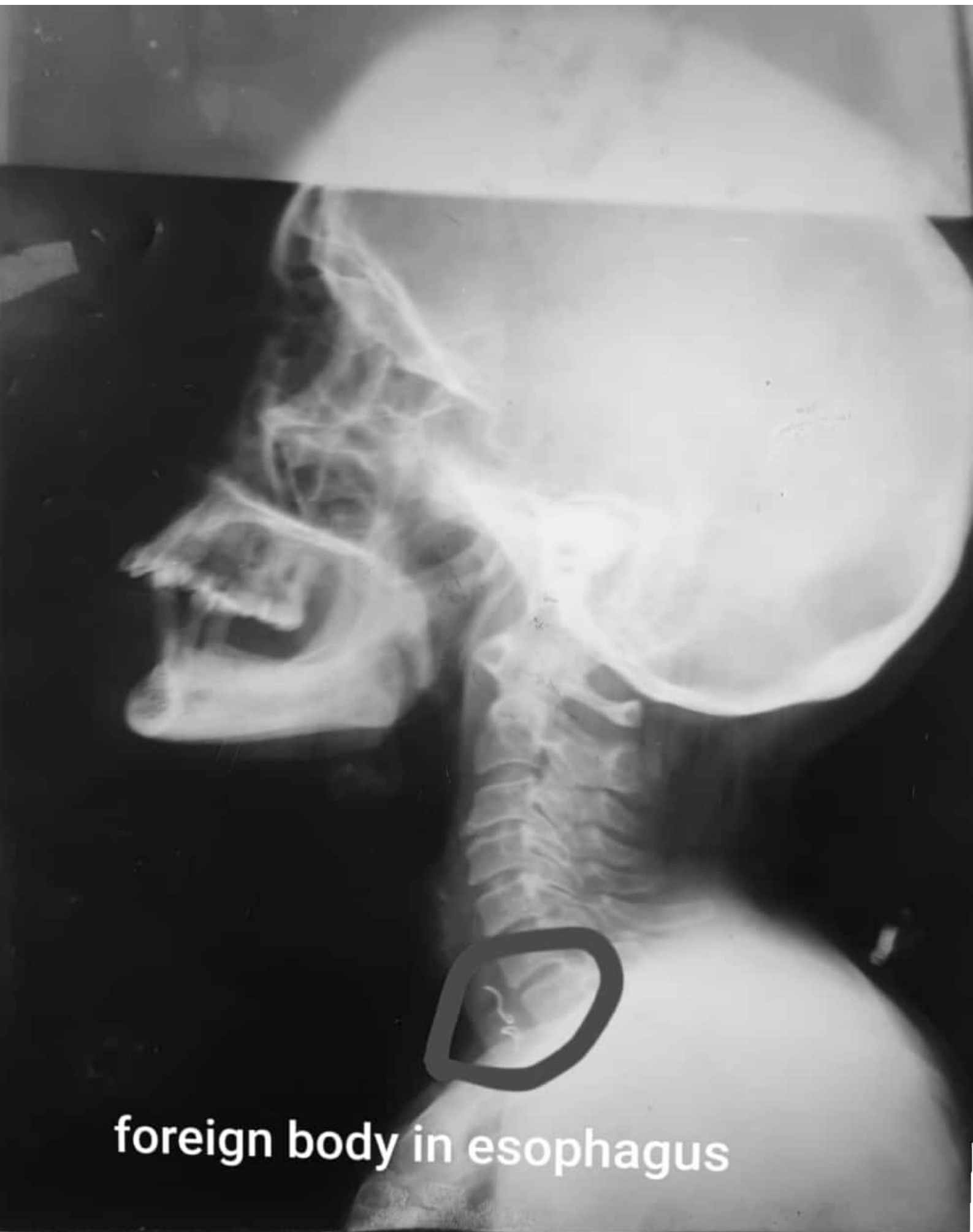

R

xray of paranasal sinus

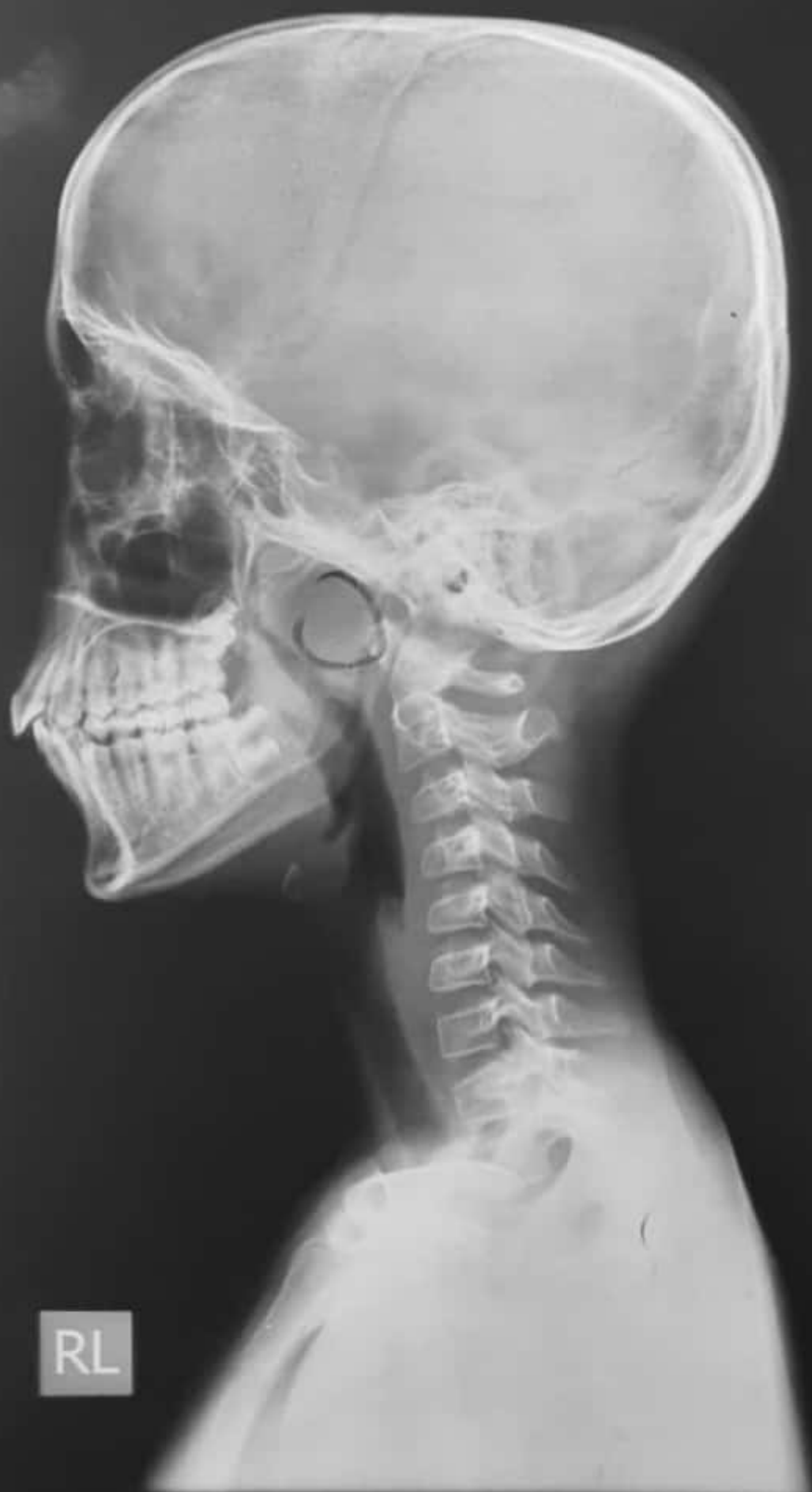Dr. Ziauddin Hospital
16.6.04
Room 92



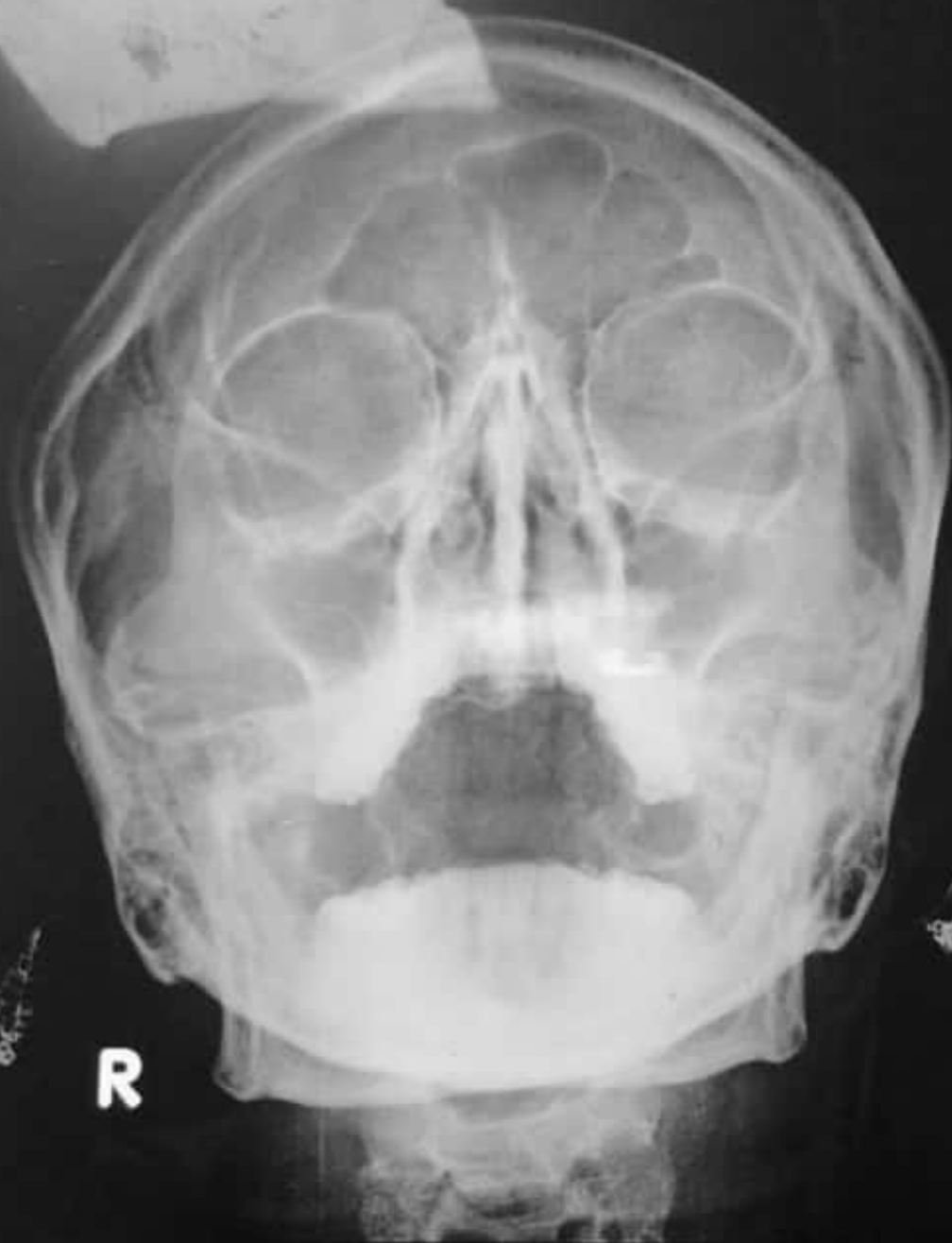

foreign body in esophagus

adenoids



RL



R

Pan sinusitis

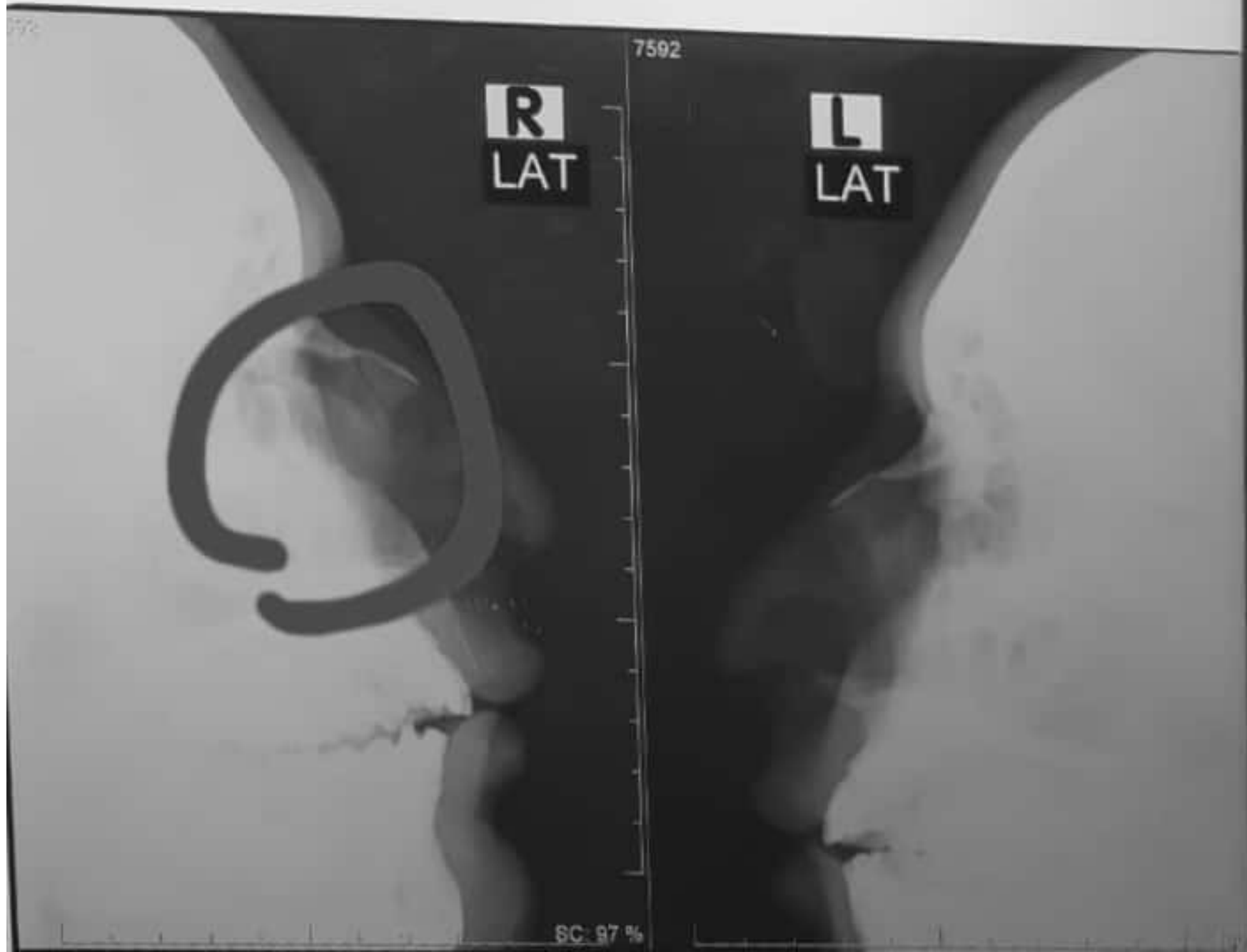
6911 SOBIA 30YRS F

2016.FEB.22

Hi-Vision Digital X-Ray Oppsite Jinnah Hospital LHR.

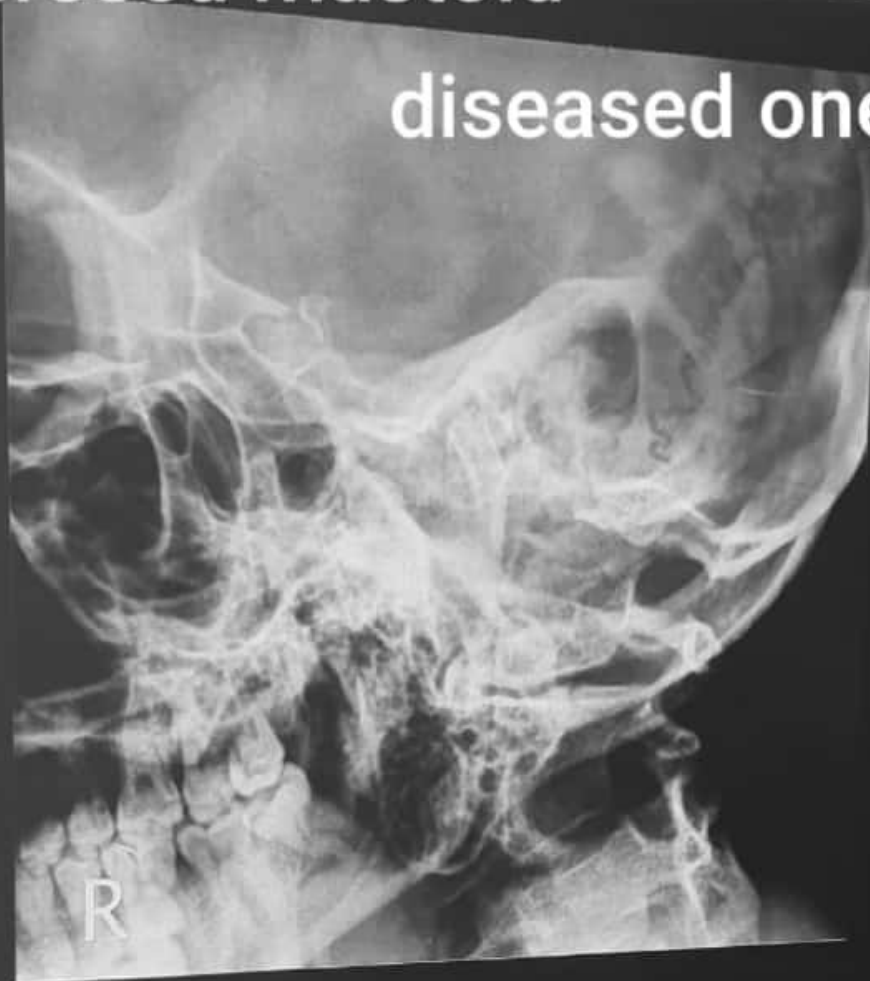SC: 93 %

fracture of nose



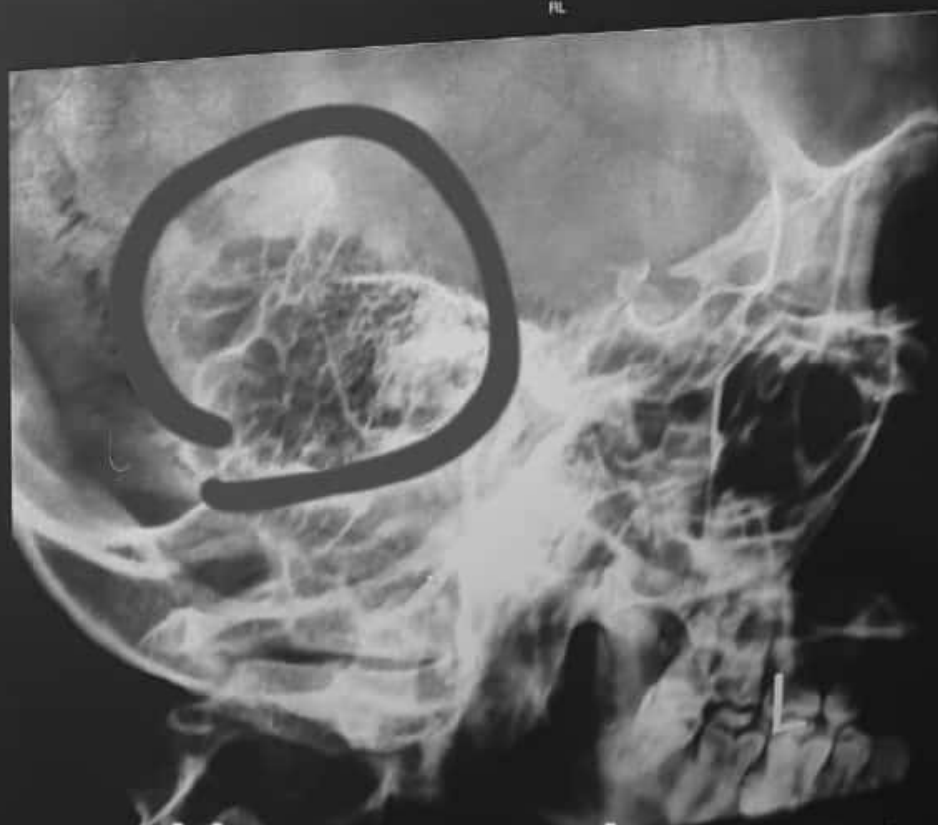sclerosed mastoid

diseased one



R

RL

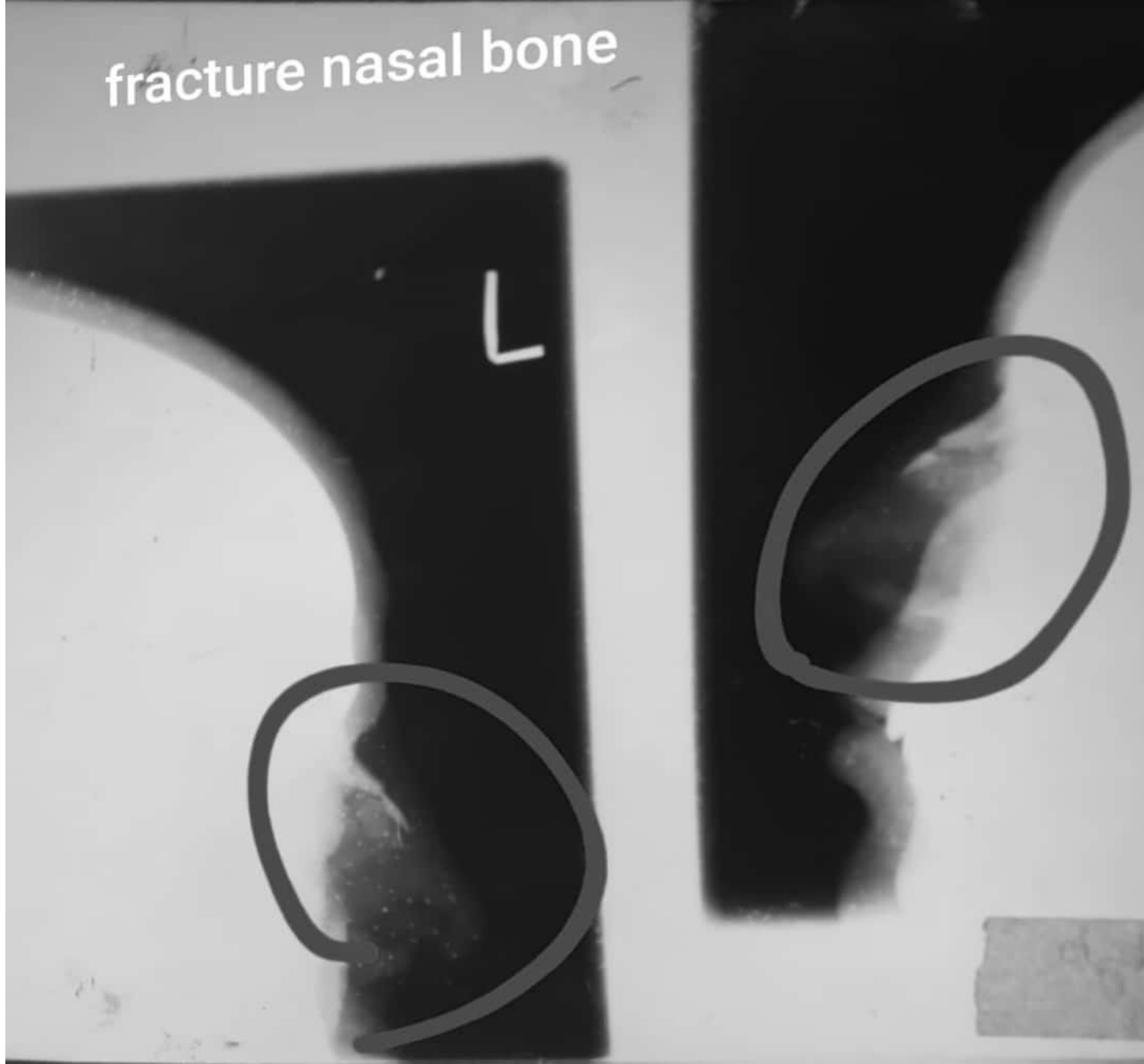


normal honey comb appearance

SKULL

17Y/F

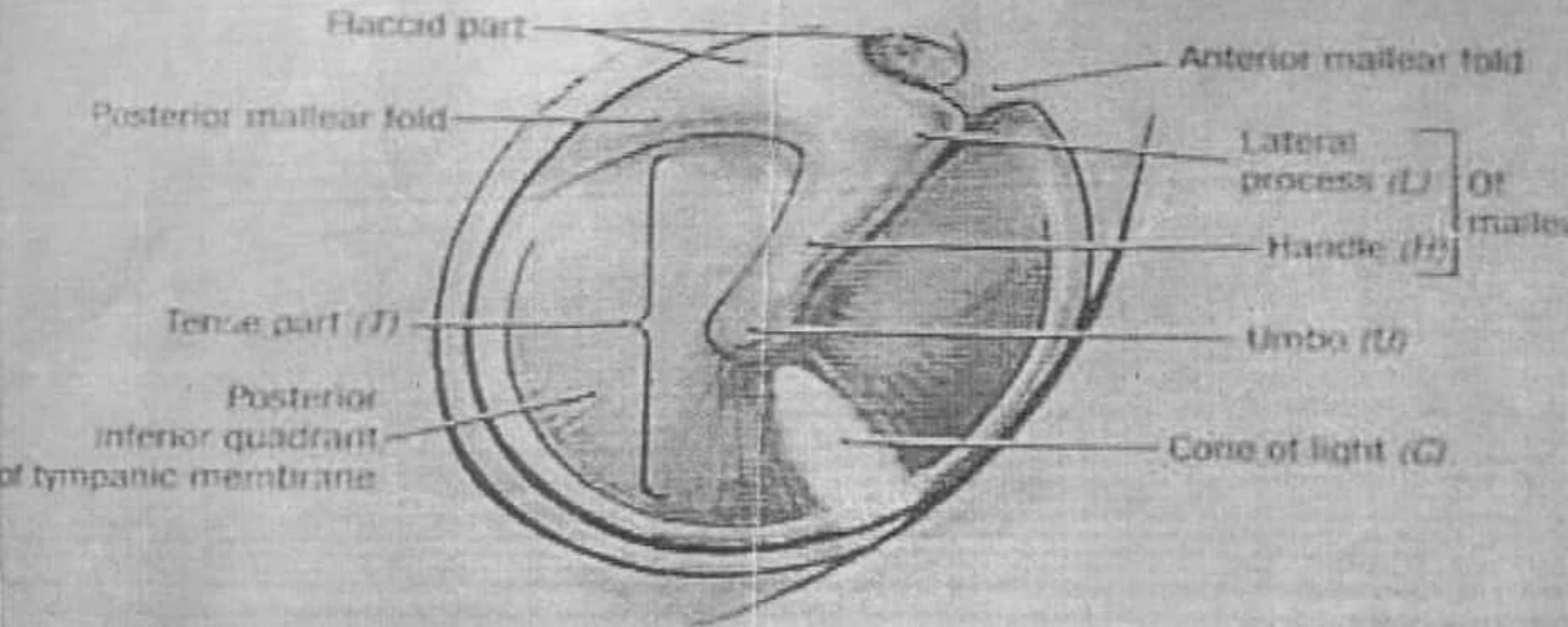
fracture nasal bone



Tympanic membrane

POSTERIOR


ANTERIOR

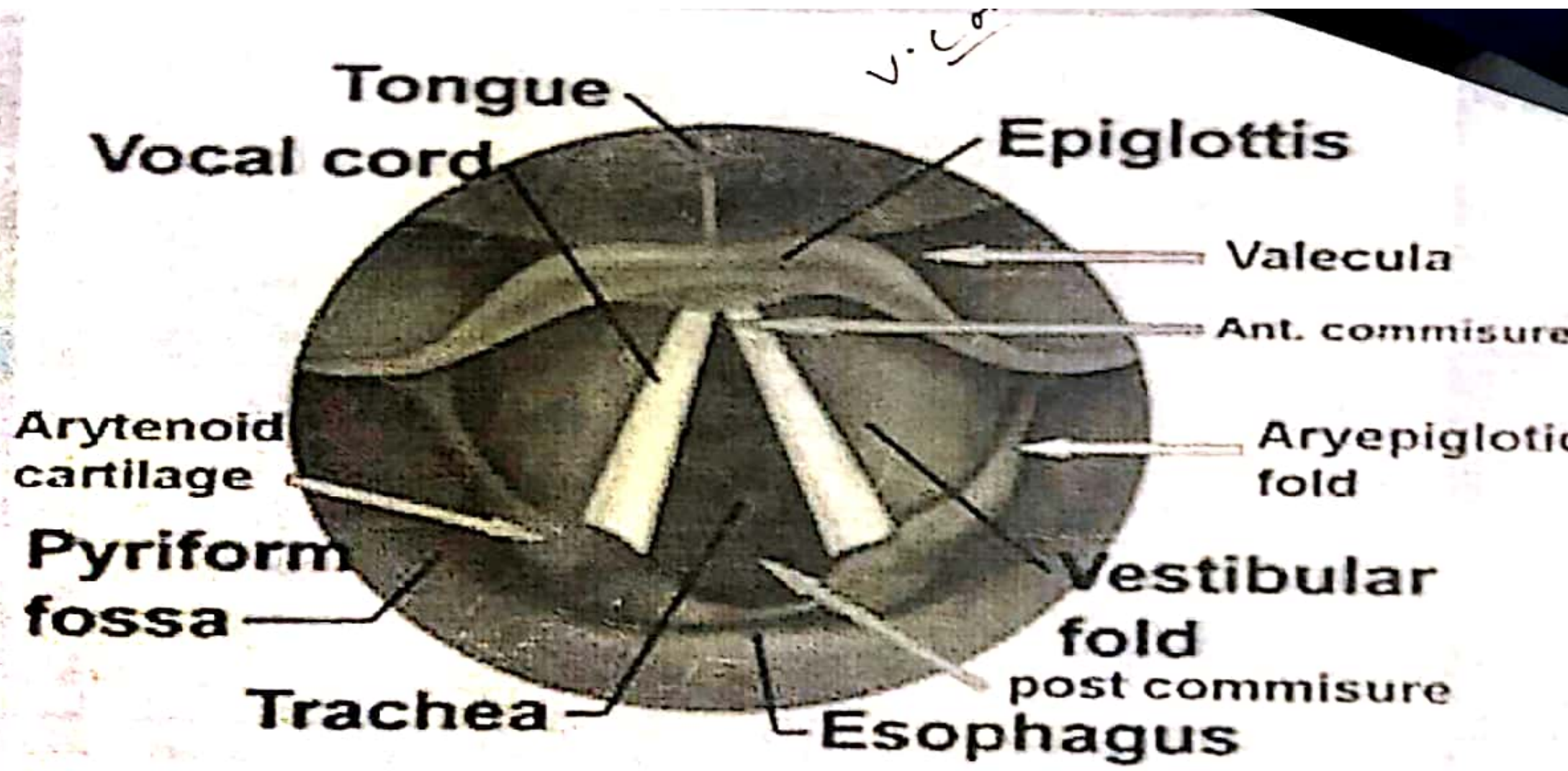


Auriscopic (Lateral) View

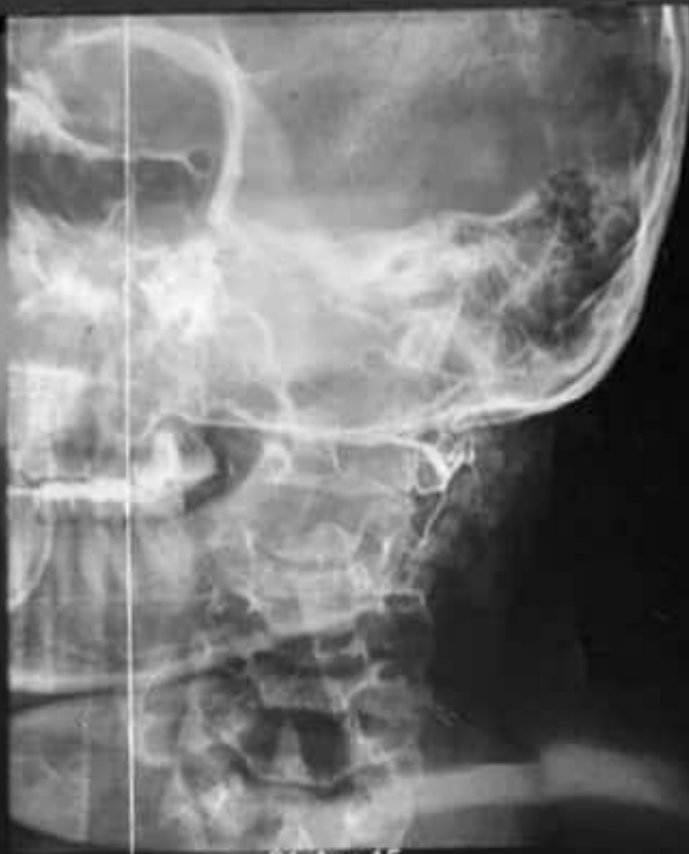Esophagoscope

Oesophagoscope

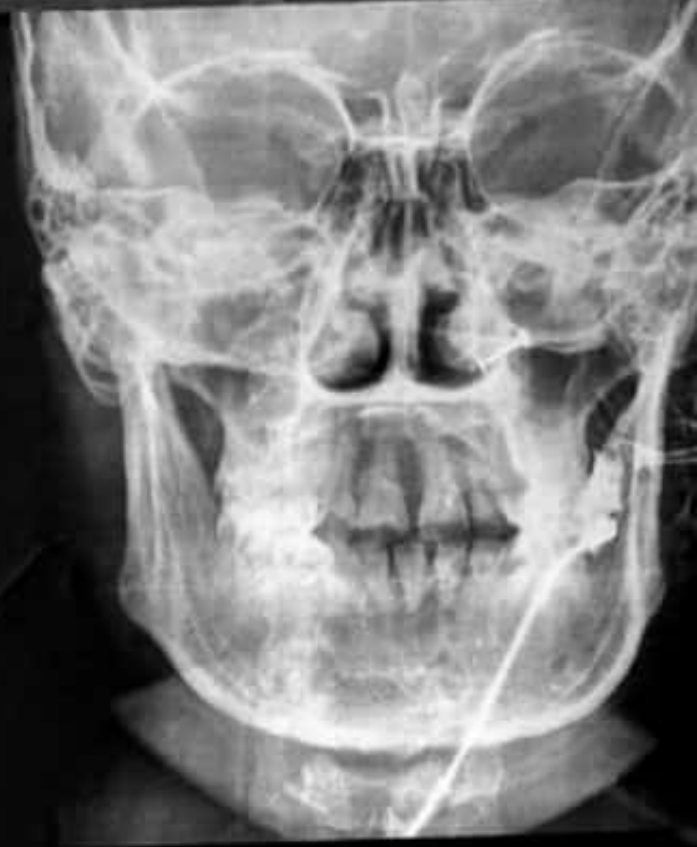



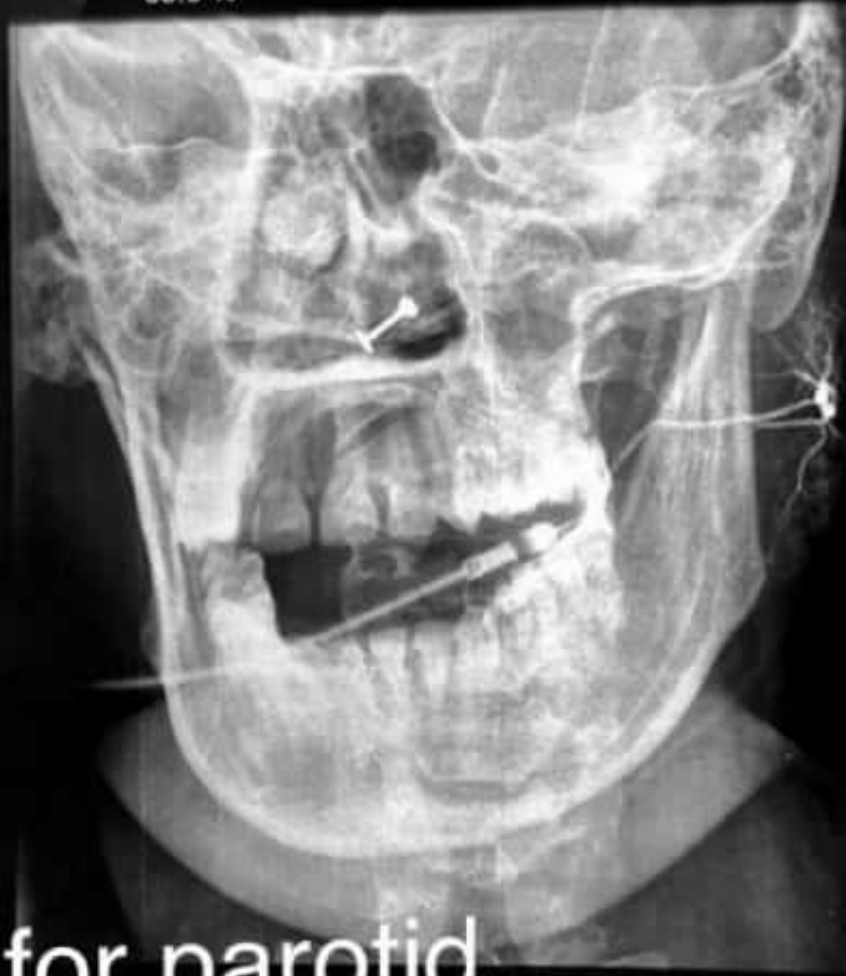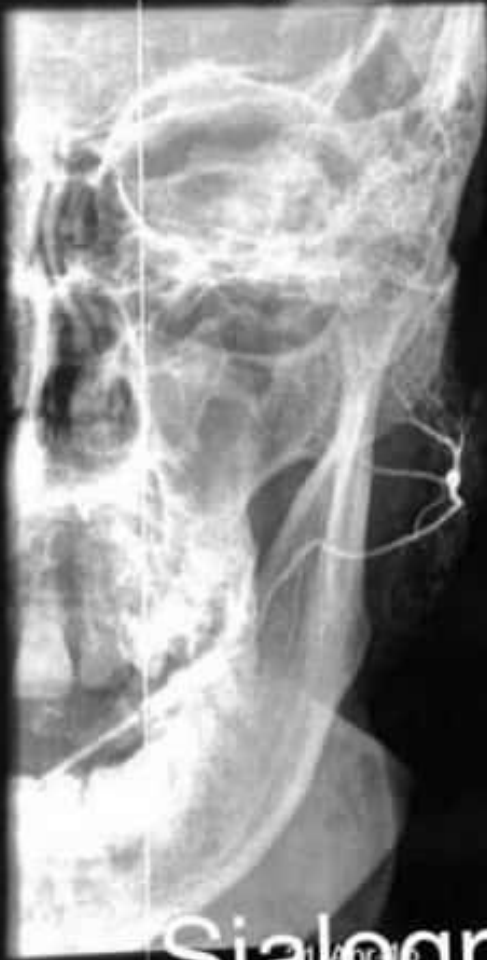Parts seen in Laryngoscopy



21-Apr-15



63.0 %



3.5 %

Sialogram for parotid region

SABA 20Y/ F

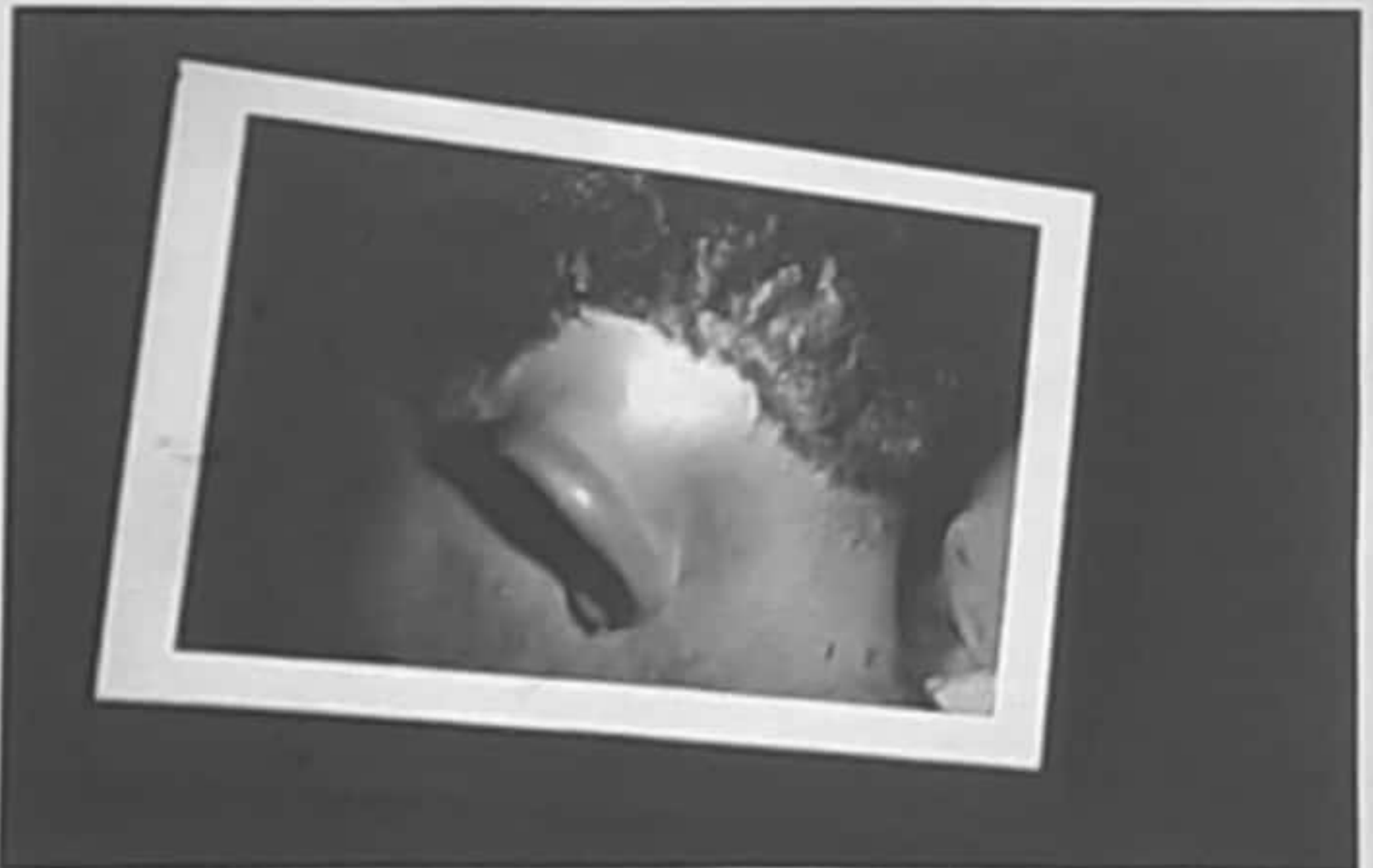SHAIKH ZAYED HOSPITAL, LAHORE

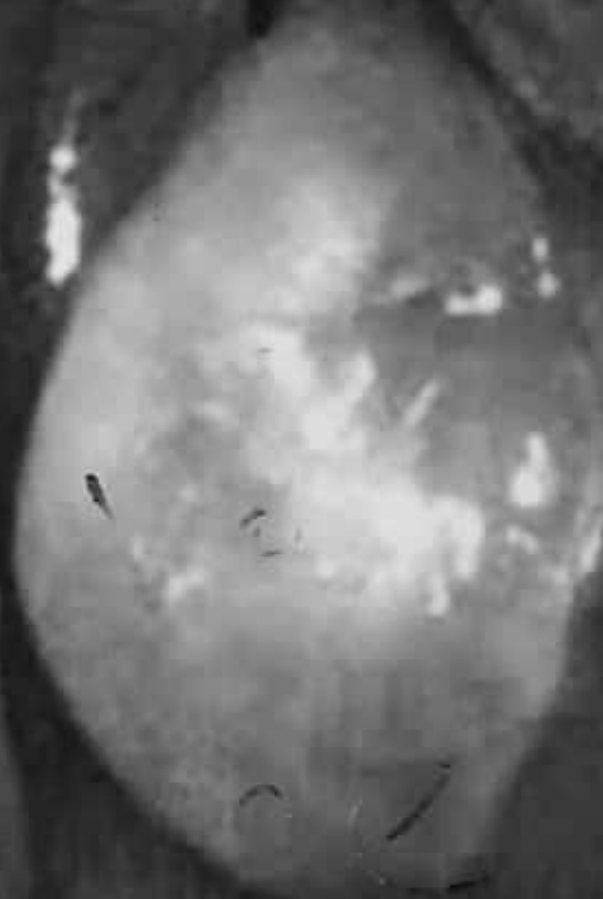Skull
region

21-Apr-15 1:17:50 PM

DEPT: SIALOGRAM

Slide: mastoiditis





Vocal polyp

LARYNX PICTURE

X-ray
mastoids, 80
nasal fractures, 494
nasopharynx, soft tissue lateral view, 494
neck, anteroposterior view, 494
neck, lateral view, 494

Schuller's view of, 493
Stenver's view of, 493
submentovertical view of, 493

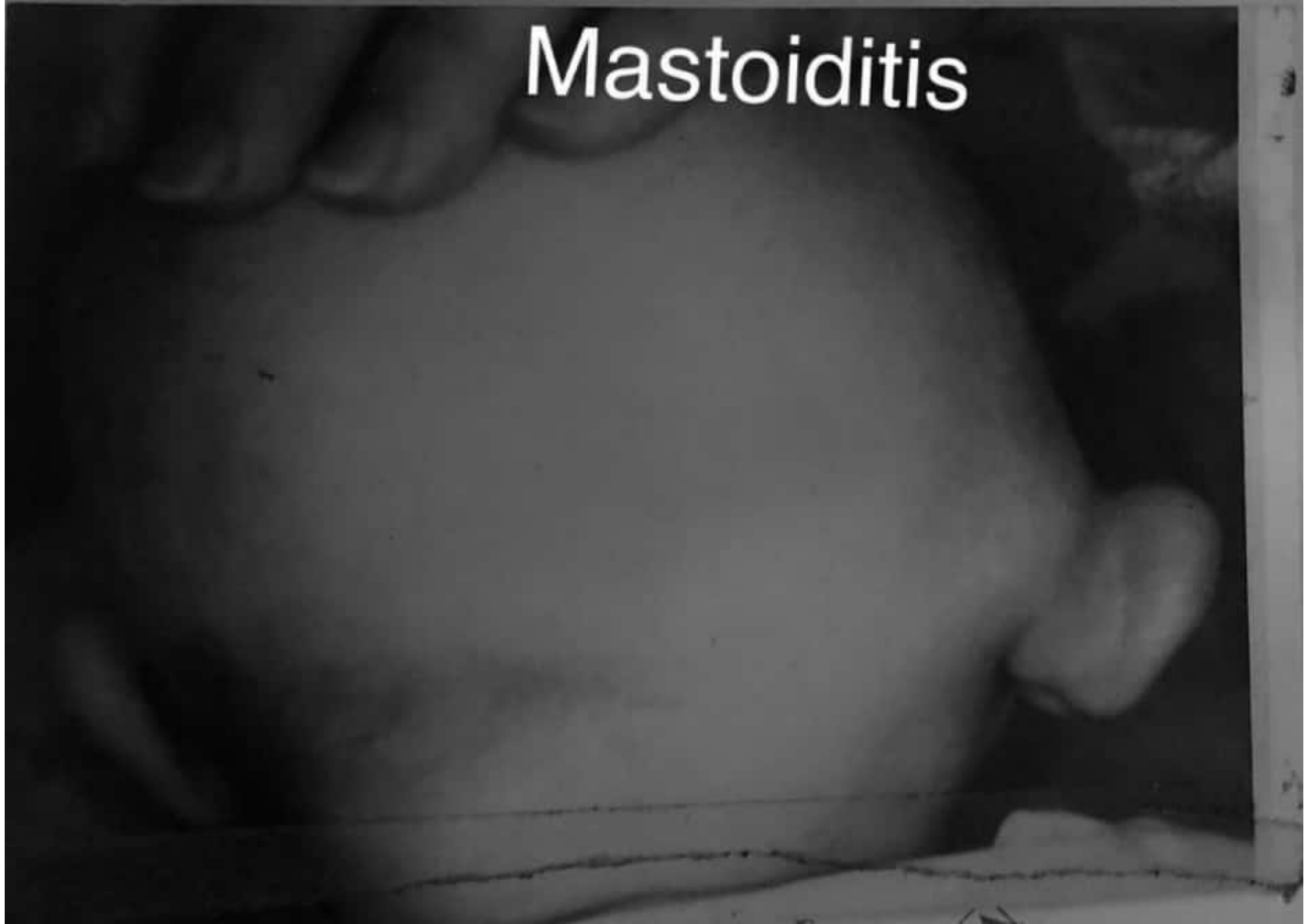Zypp

tonsil holder



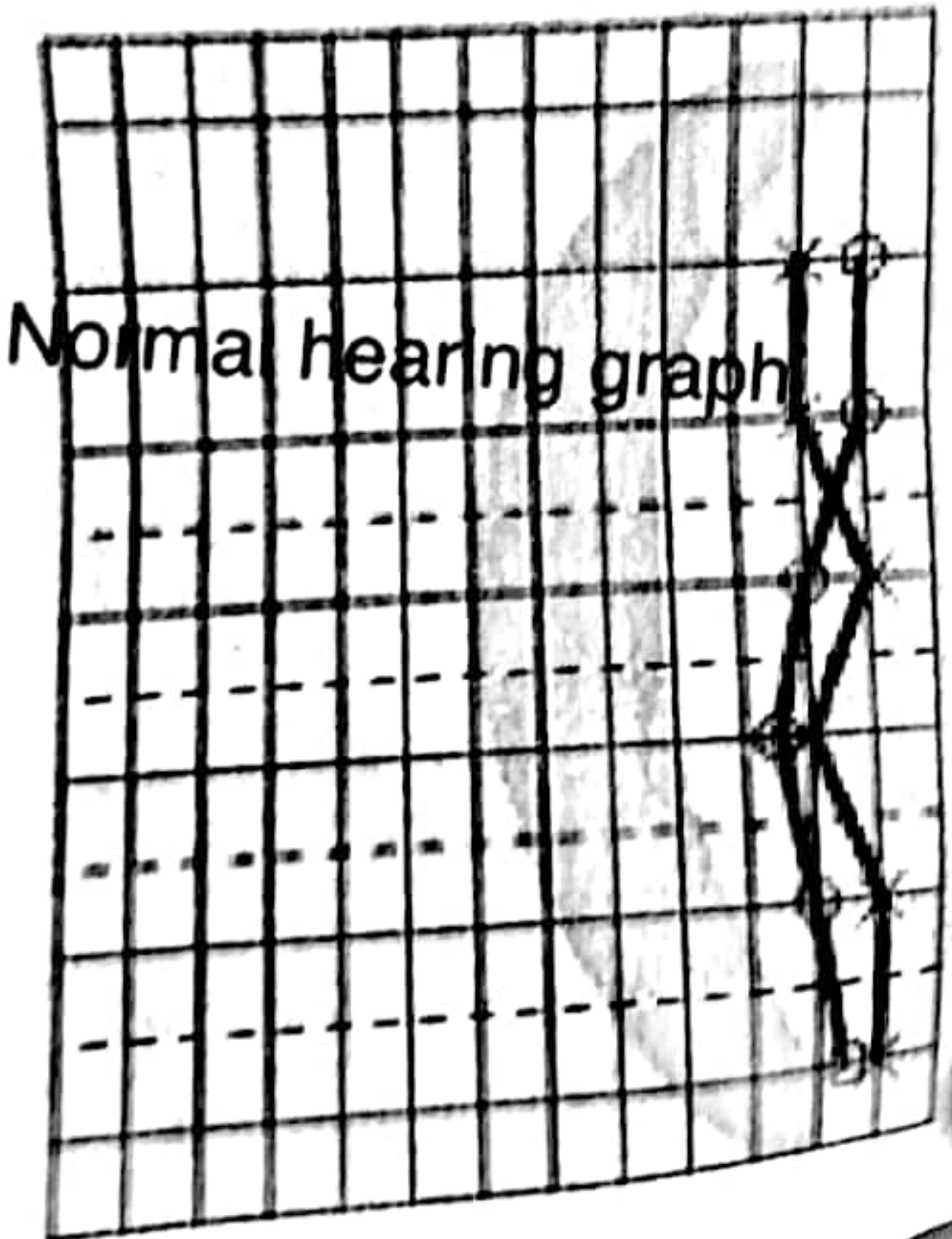
W. L. BAKER
L. S. L. W. BAKER

Mastoiditis



Hearing Level (dB)

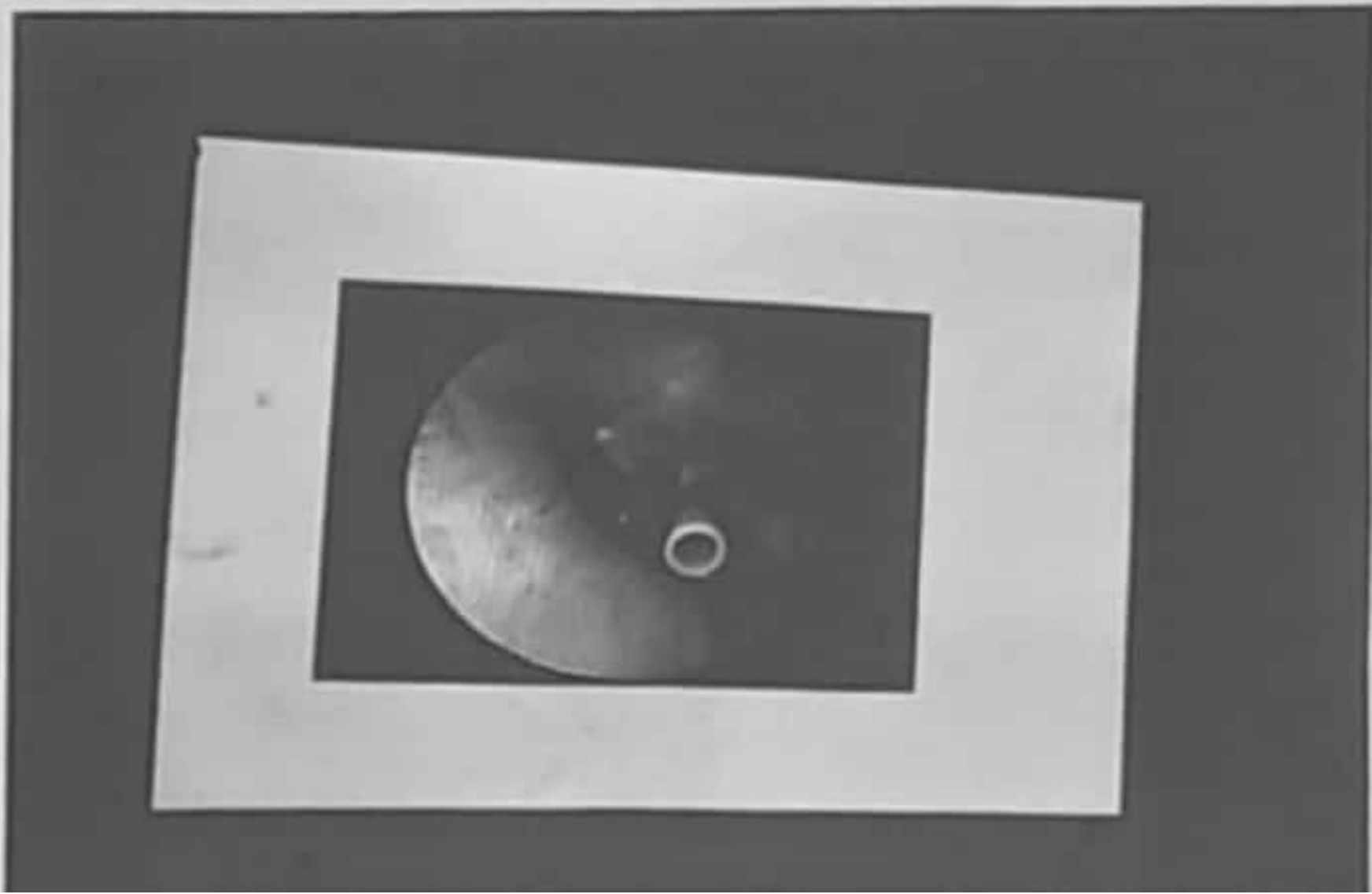
10 20 30 40 50 60 70 80 90 100 110 120



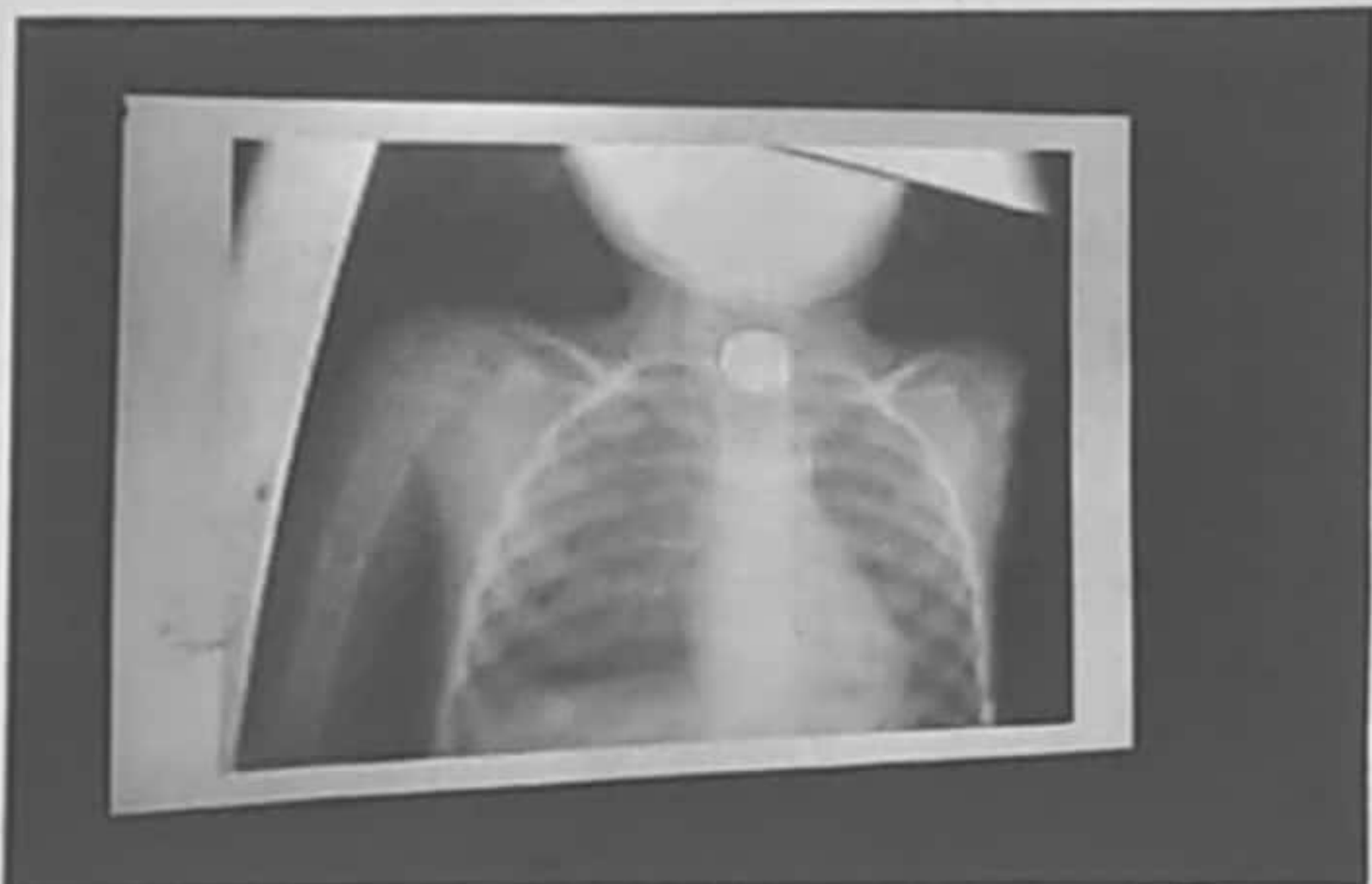125 250 500 1000 2000 4000 8000

Frequency (Hz)

Slide: TM wid Grommet



Slide: Xray neck and chest PA view .. Showing foreign body

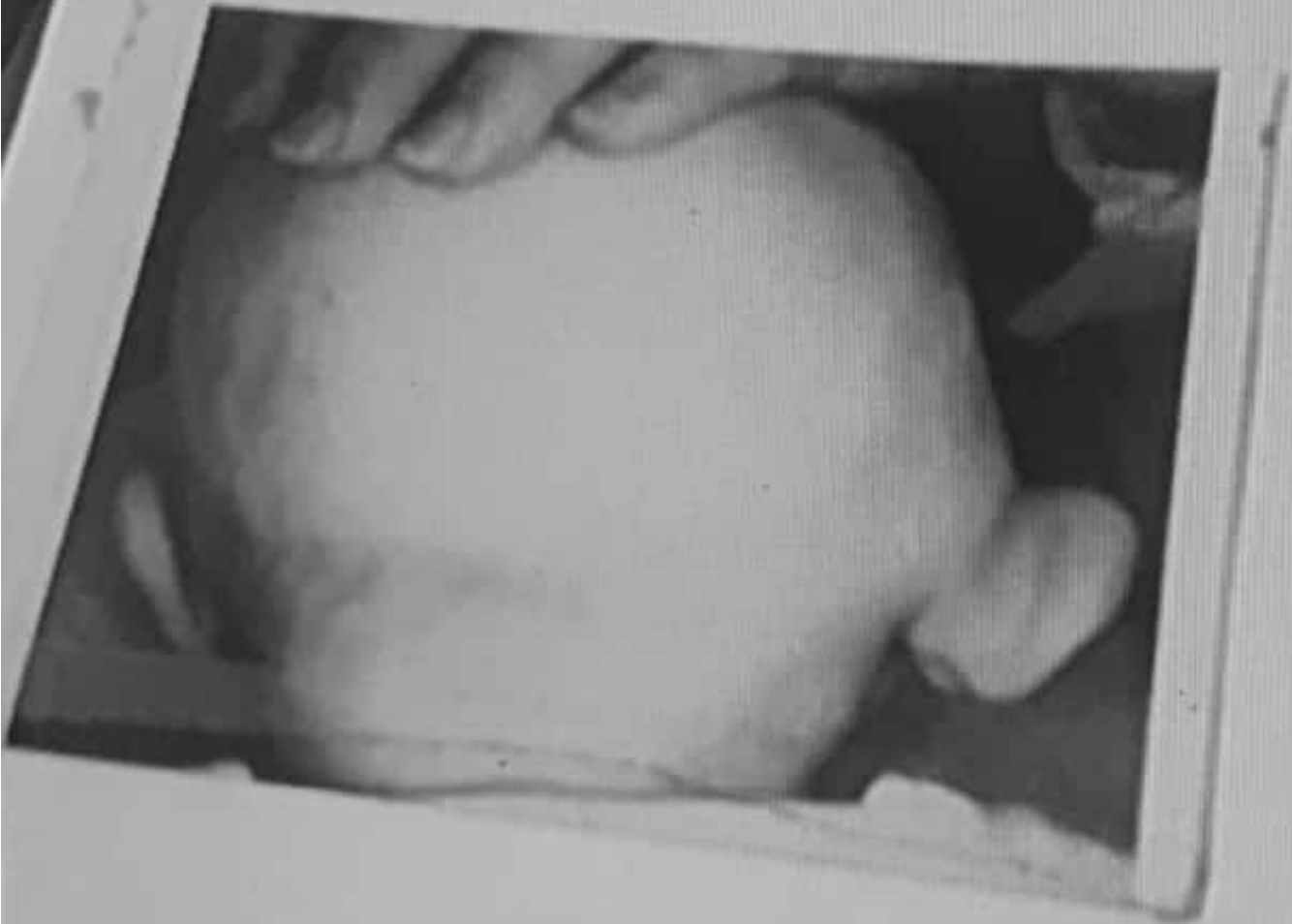

Q

Station 4

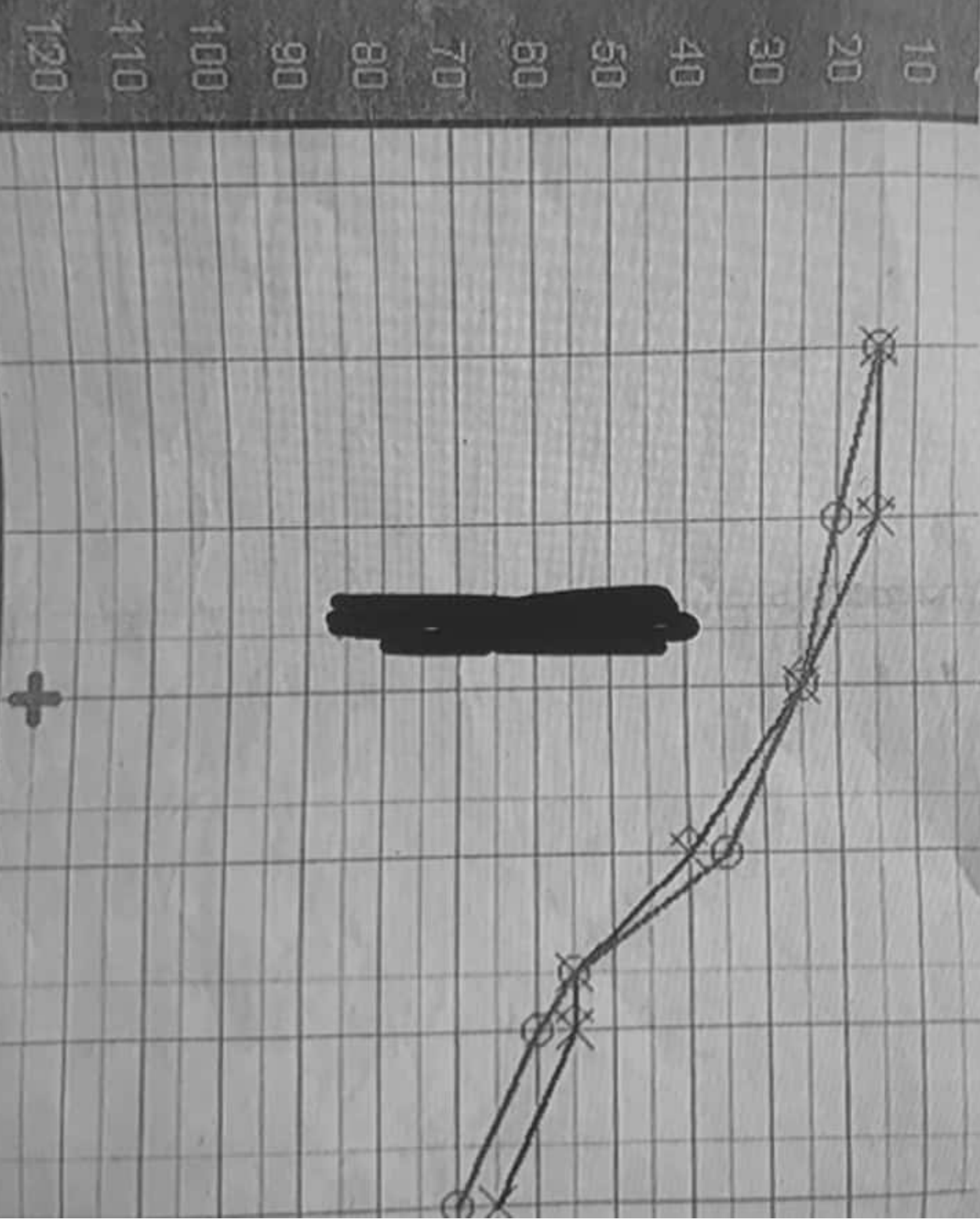
A-IDENTIFY THE PICTURE

B-WRITE DOWN TREATMENT



mastoid abscess

Bilateral conductive hearing loss



Slide. Laryngoscope



عمران علی

Slide. Laryngoscope

Laryngoscope



مرحوم علی

nasal
indications.
wax.

usage: - Traction
" "
" "

em -

Adenoid currate



540 Index

Wrisberg's cartilage, 511
Wrisberg's nerve, 99, 510

X

X-ray
mastoids, 80
nasal fractures, 494
nasopharynx, soft tissue lateral view, 494
neck, anteroposterior view, 494
neck, lateral view, 494

paranasal sinuses
Caldwell view of, 493
lateral view of, 494
right and left oblique views of, 494
submentovertical view of, 494
Waters' view of, 493, 496f
temporal bone
Law's view of, 493, 495f
Schuller's view of, 493
Stenver's view of, 493
submentovertical view of, 493

trochar and
canula





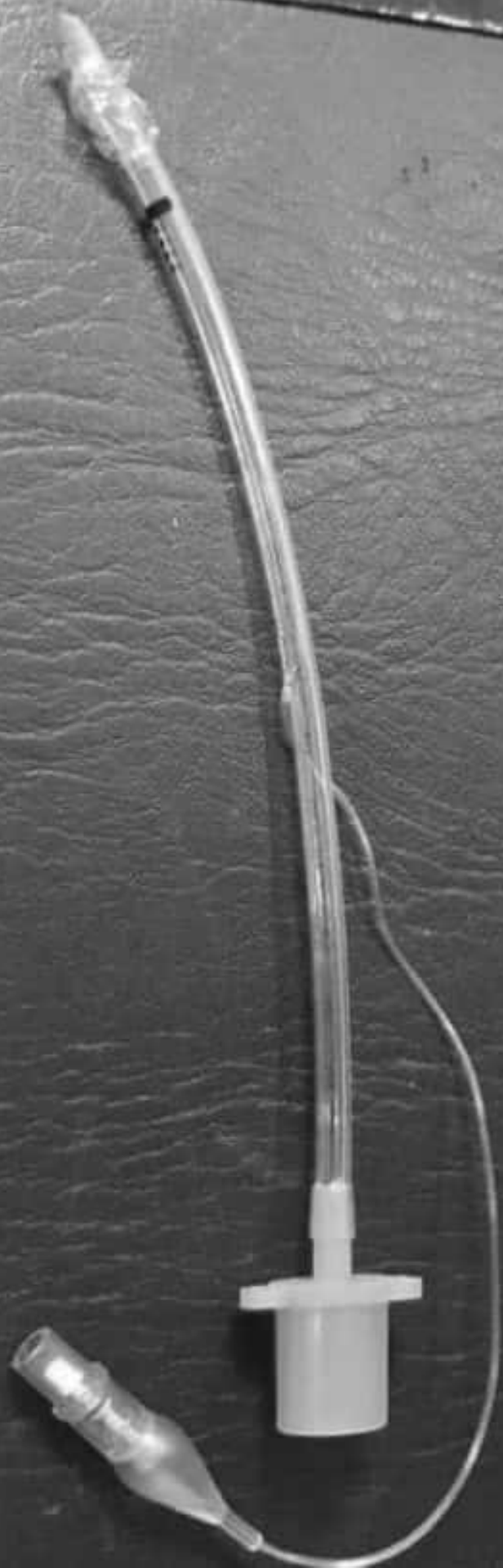
Adult endo tracheal tube



Tonsil dissector ...pillar retractor



endotracheal tube (short case)





Tilleys forcep

Treatment-
Decongestant
antihistamine
antibiotics
Adenoidectomy

Adenoid

Enlargement of
nasopharyngeal tonsil
which is mass of
lymphoid tissue
located at the
junction of roof and
post.wall of
nasopharynx

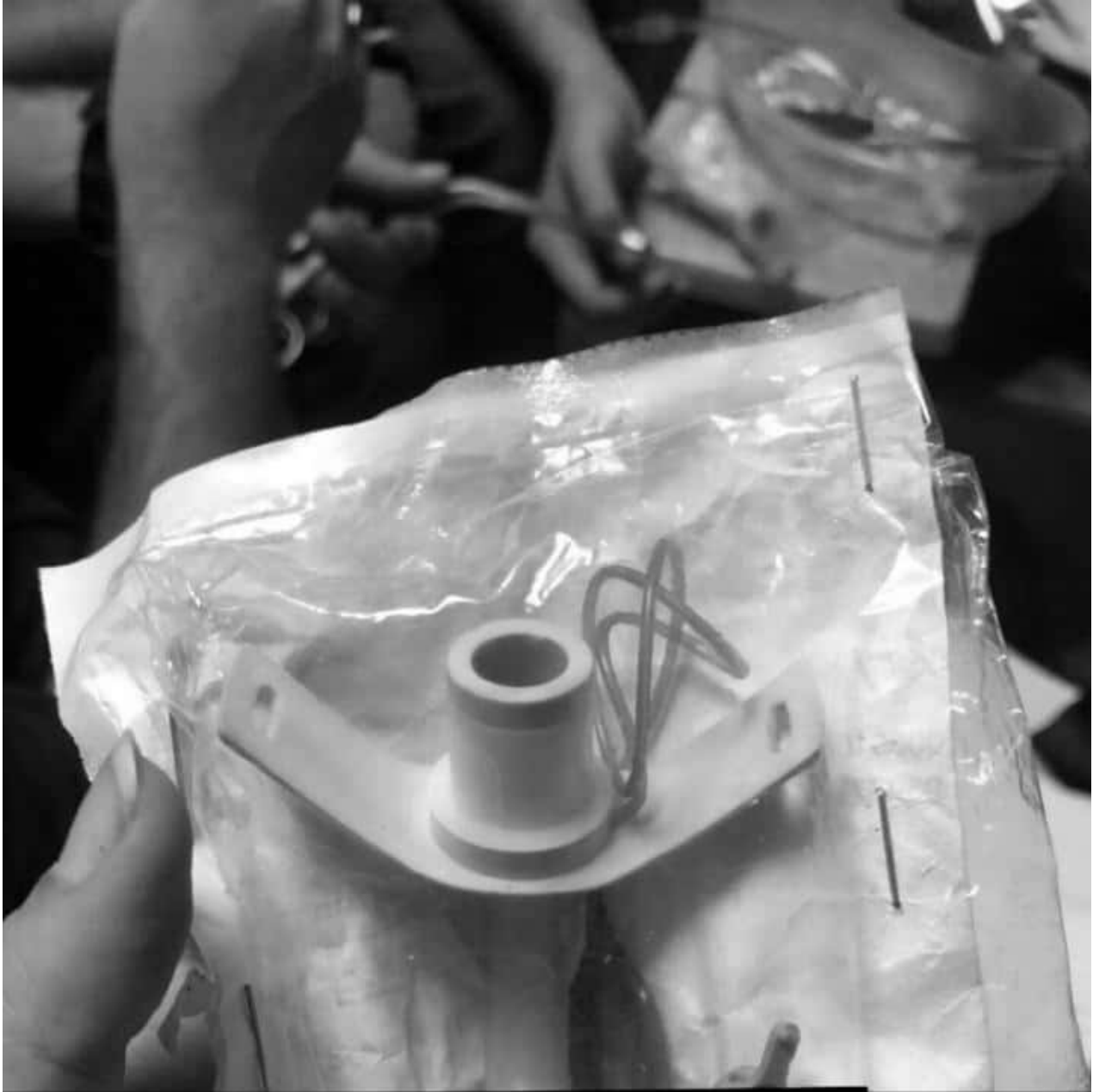produce-IgG,IgM,IgA

Adenoidectomy

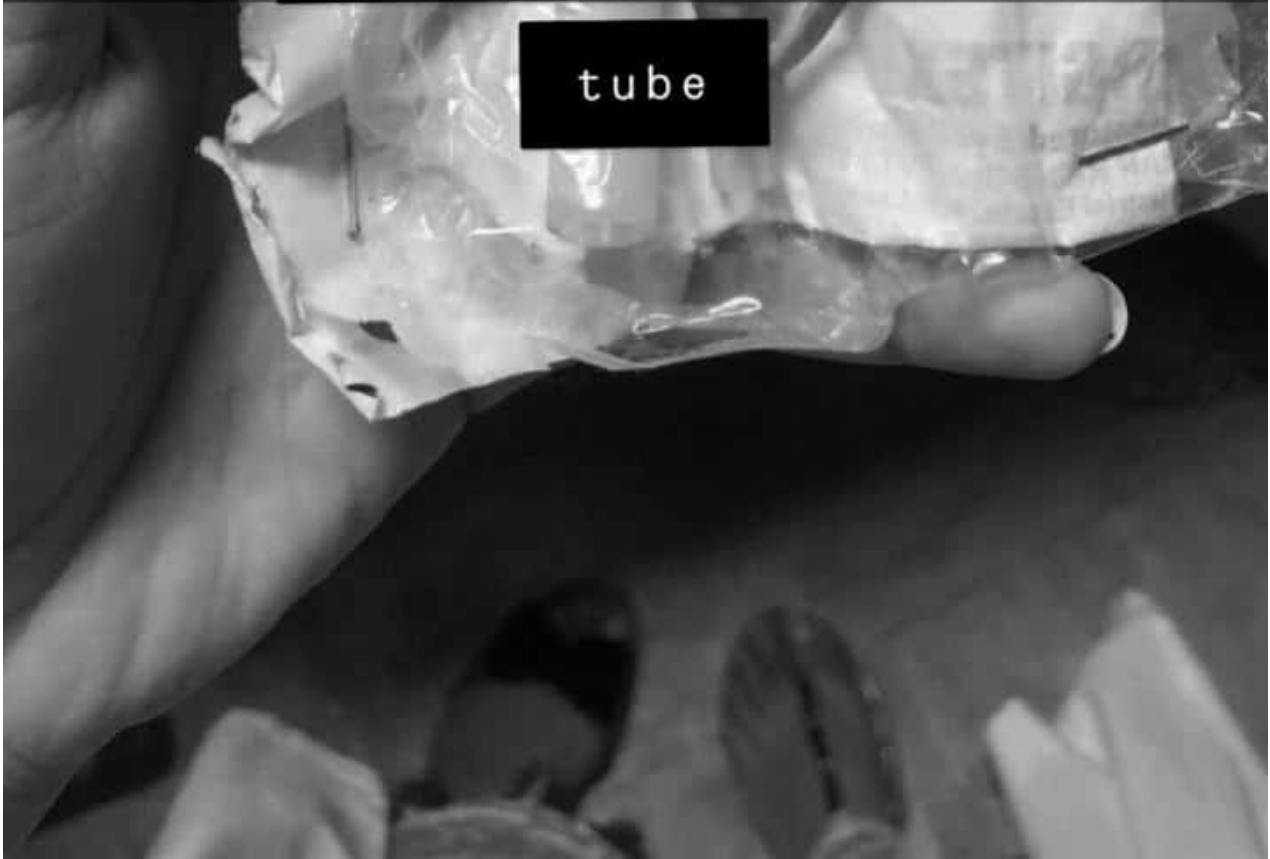Indication-Recurrent
rhinosinusitis
adenoid hypertrophy
otome
dental malocclusion

C/I-hemorrhagic
diathesis
cleft palate
Acute LRTI

Complications-
hemorrhage
injury to ET
Nasopharyngeal
stenosis
Recurrence
grisel syndrome



Adult tracheostomy



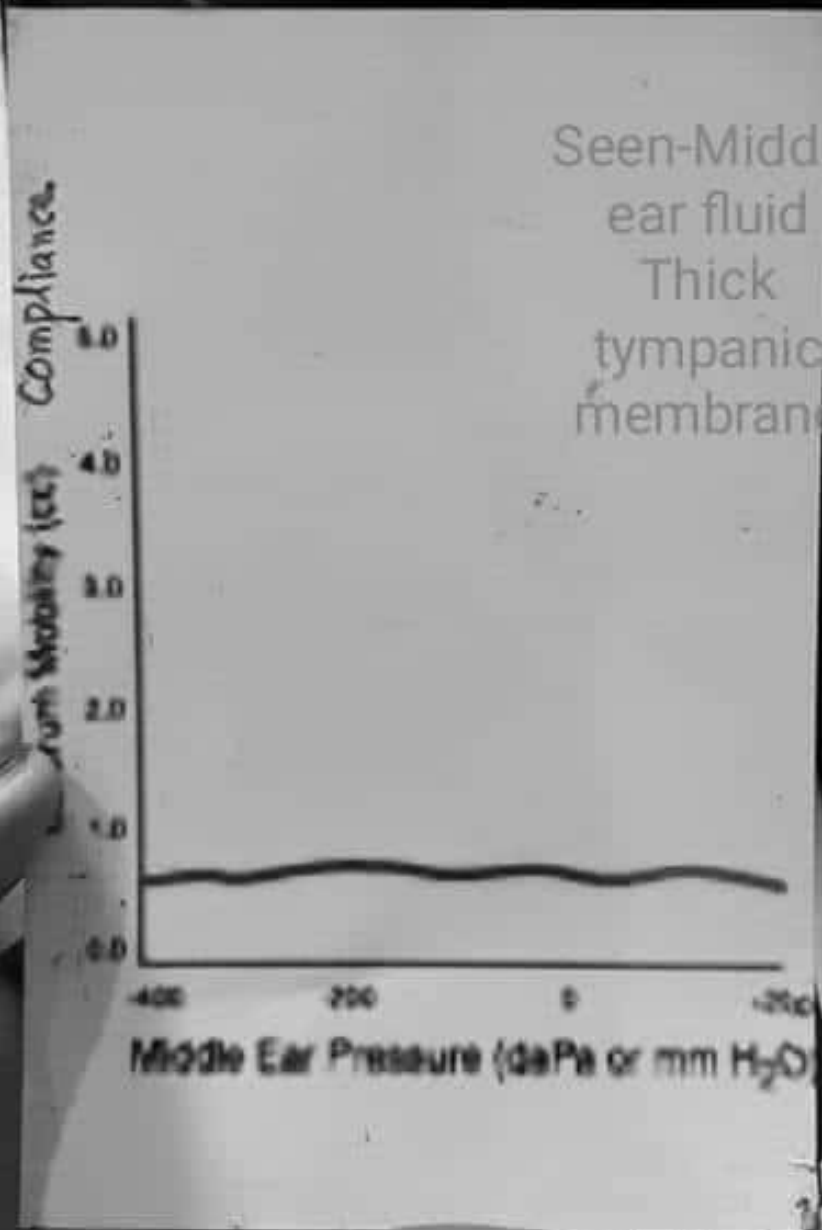
tube




Tilley hanckel nasal

turbinate forcep

Flat graph
no change in
compliance
with pressure
changes

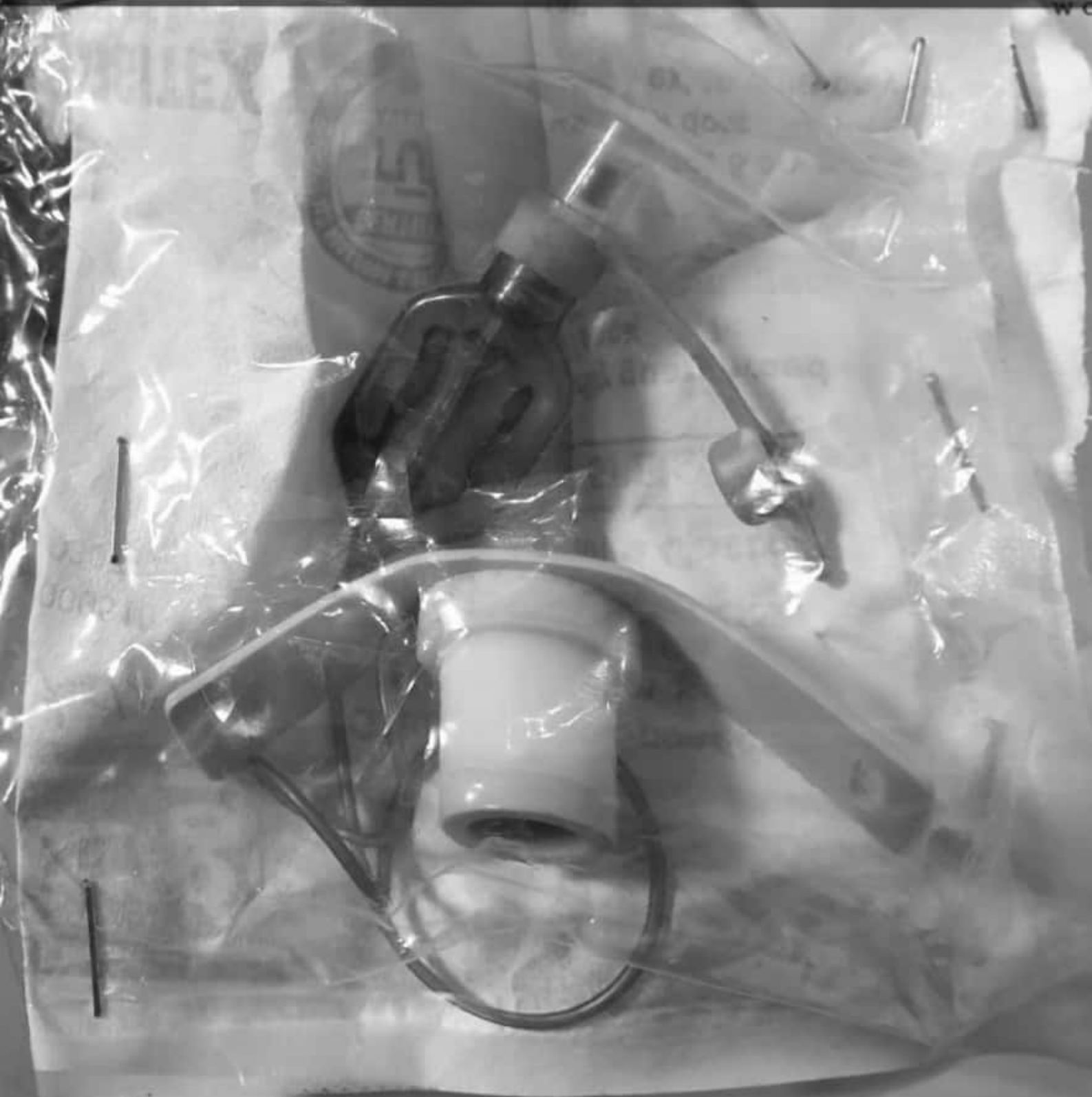

type b graph

A black and white photograph showing a hand holding a clear plastic package containing a child tracheostomy tube. The tube is visible through the plastic, showing its internal structure and the absence of a cuff. The background is dark and out of focus, suggesting a clinical setting.

Child tracheostomy tube without cuff because of narrow subglottic area

Traechostomy tube

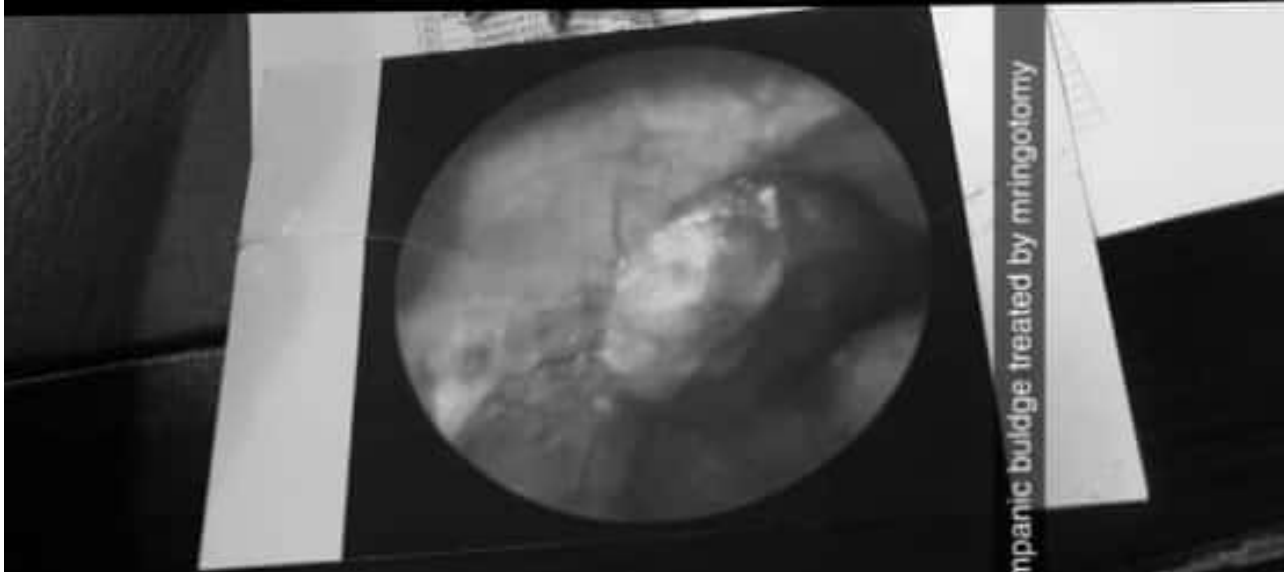


Myringotomy

Complication-
injury to
incudostapedial joint
injury to juglar
bulb with
profuse
bleeding
middle ear
infection

Indications-
ASOM
OME
Aero-Otitis
media
Atelactic ear

Anesthesia-
When TM
inflamed
childrens nd
Adult~GA
No TM
inflamed~Loc
al anesthesia



tympanic buldge treated by mringotomy

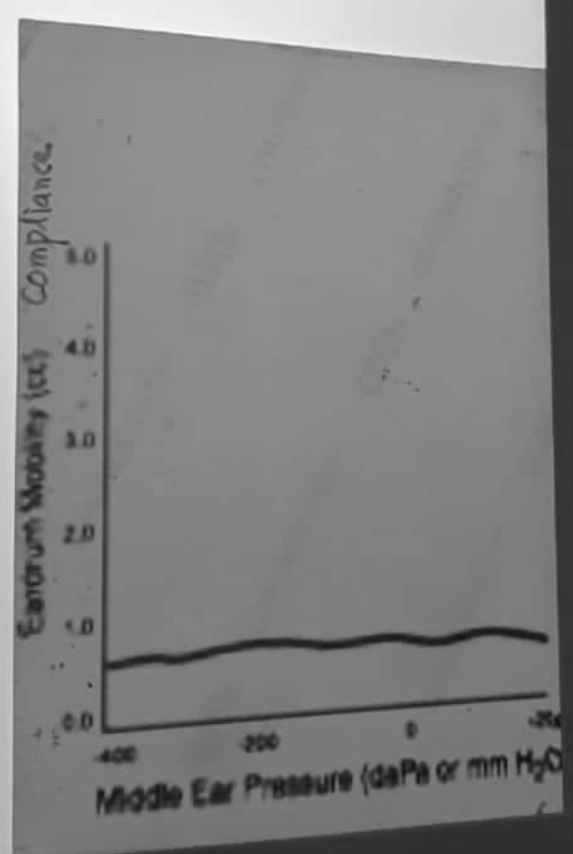
Incision~In
ASOM-
Circumferentia
l incision
Posteroinferio
r quardant to
protect
incudospedal
joint

OME-small
radial incision
posteroinferio
r

Station 7

- a-Identify the graph
- b-Write down the causes of disease

tympanometry type B graph






white patches on tonsils


Station 8

identify the picture

write down the treatment

A black and white photograph showing a hand holding a pair of crocodile forceps. The forceps have long, thin, pointed jaws and circular handles. The background is blurred, showing a clinical environment with a person in a white coat and other medical equipment. A semi-transparent dark horizontal bar is overlaid across the middle of the image, containing the text 'Crocodile forcecep'.

Crocodile forcecep



Clair thompson's

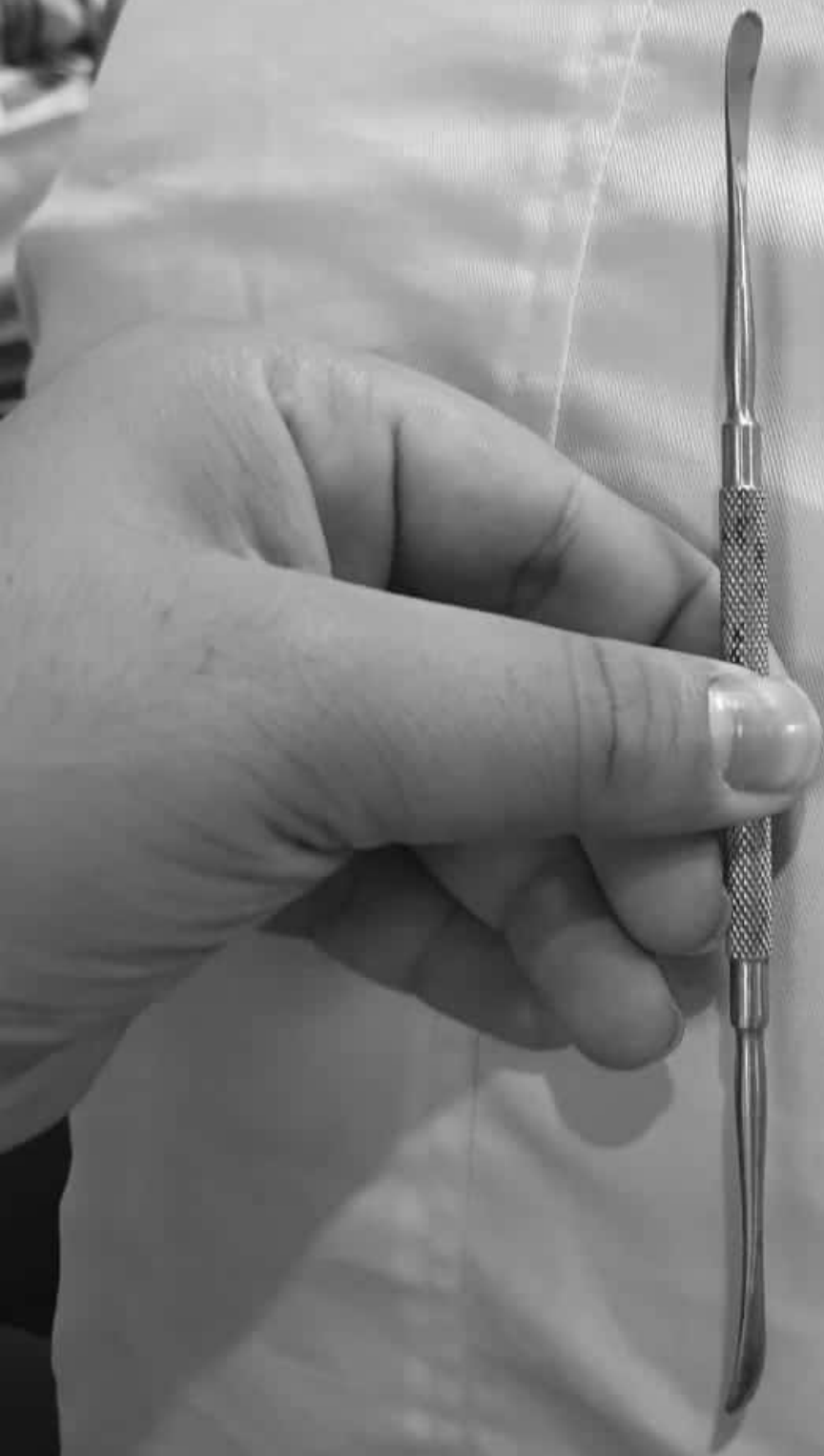adenoid curette with

gaurd

tracheostomy tube for infants



smr disector





anterior pillar retractor

mouth gag
boyles davis mouth gag with
tounge depressor

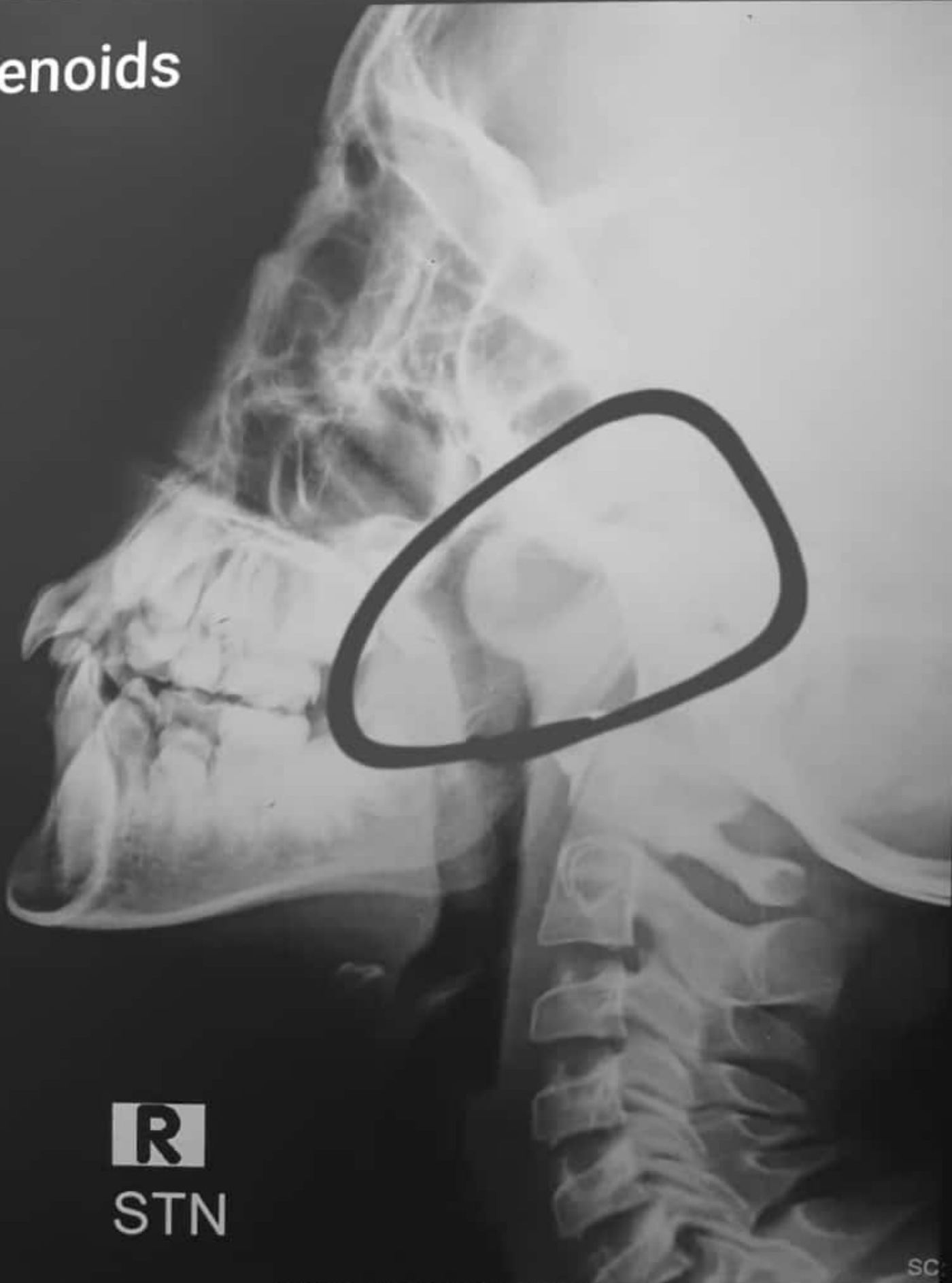

nasal polypectomy forceps



10805

adenoids



R

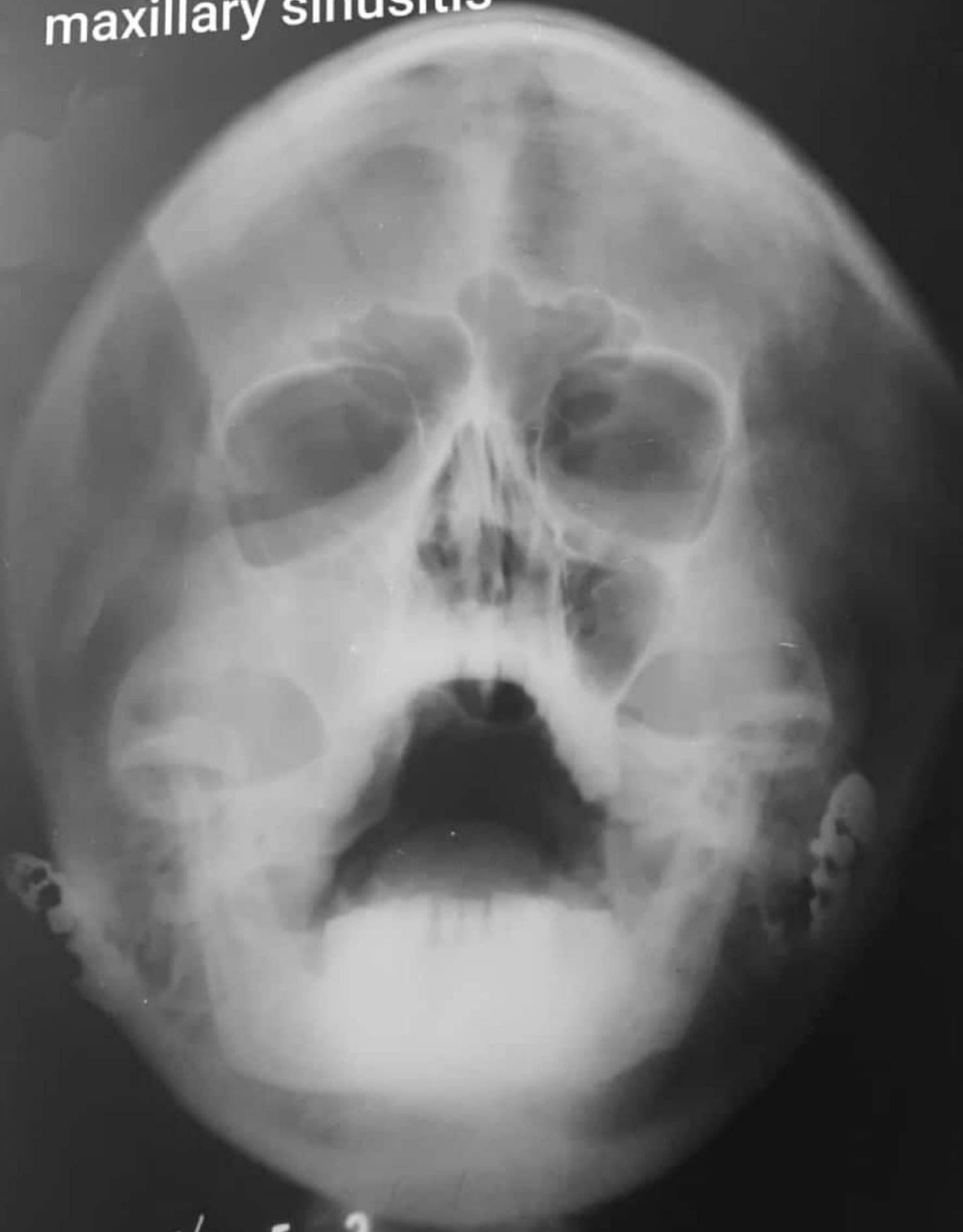STN

10805 SIKANDAR 13YRS M

05.06.2019

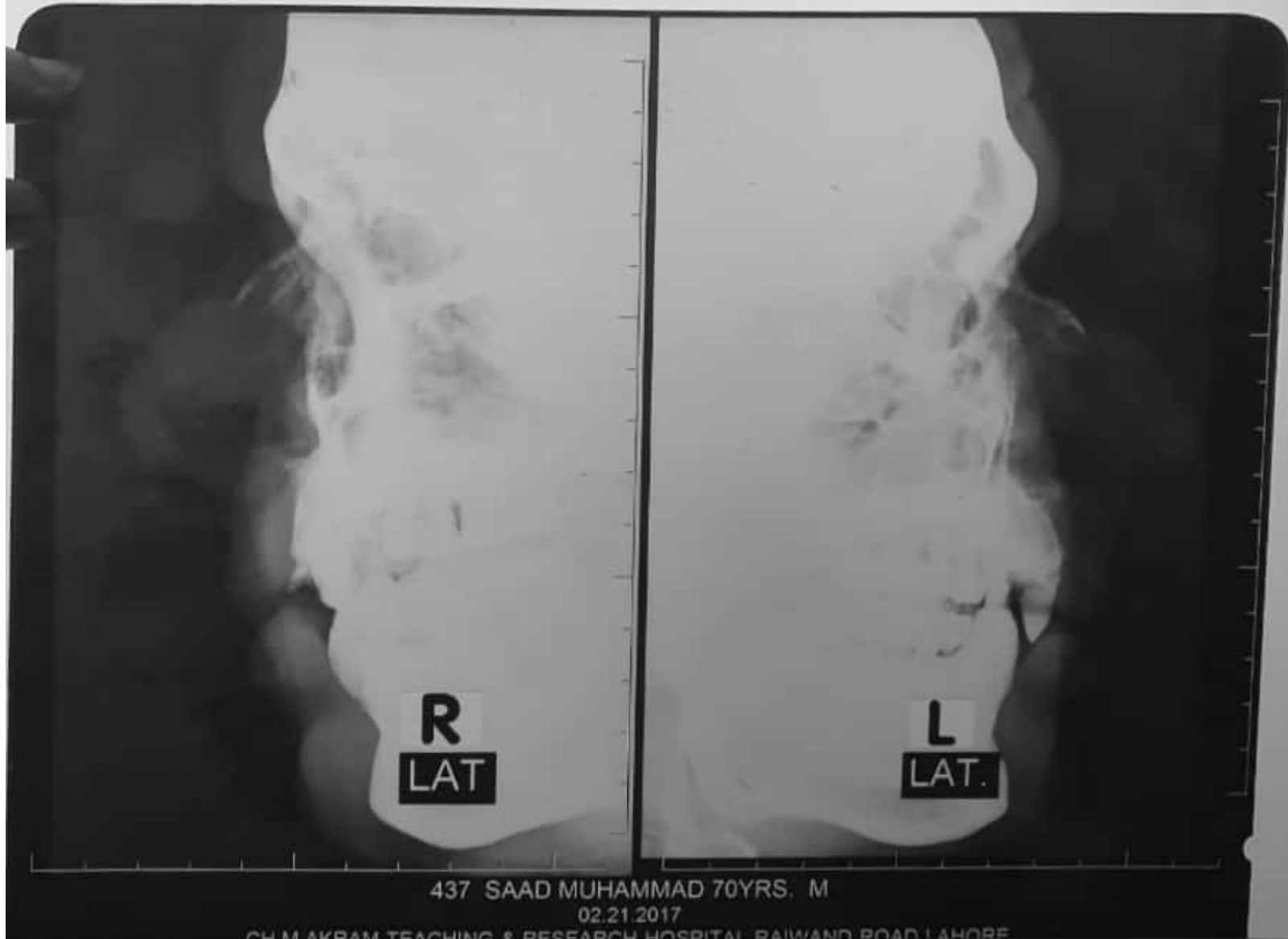SC: 1

maxillary sinusitis



1/ 5 3

fracture nose




437 SAAD MUHAMMAD 70YRS. M

02.21.2017

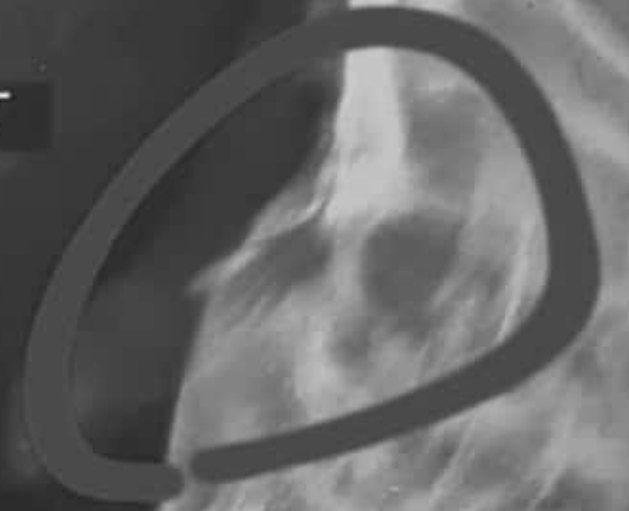
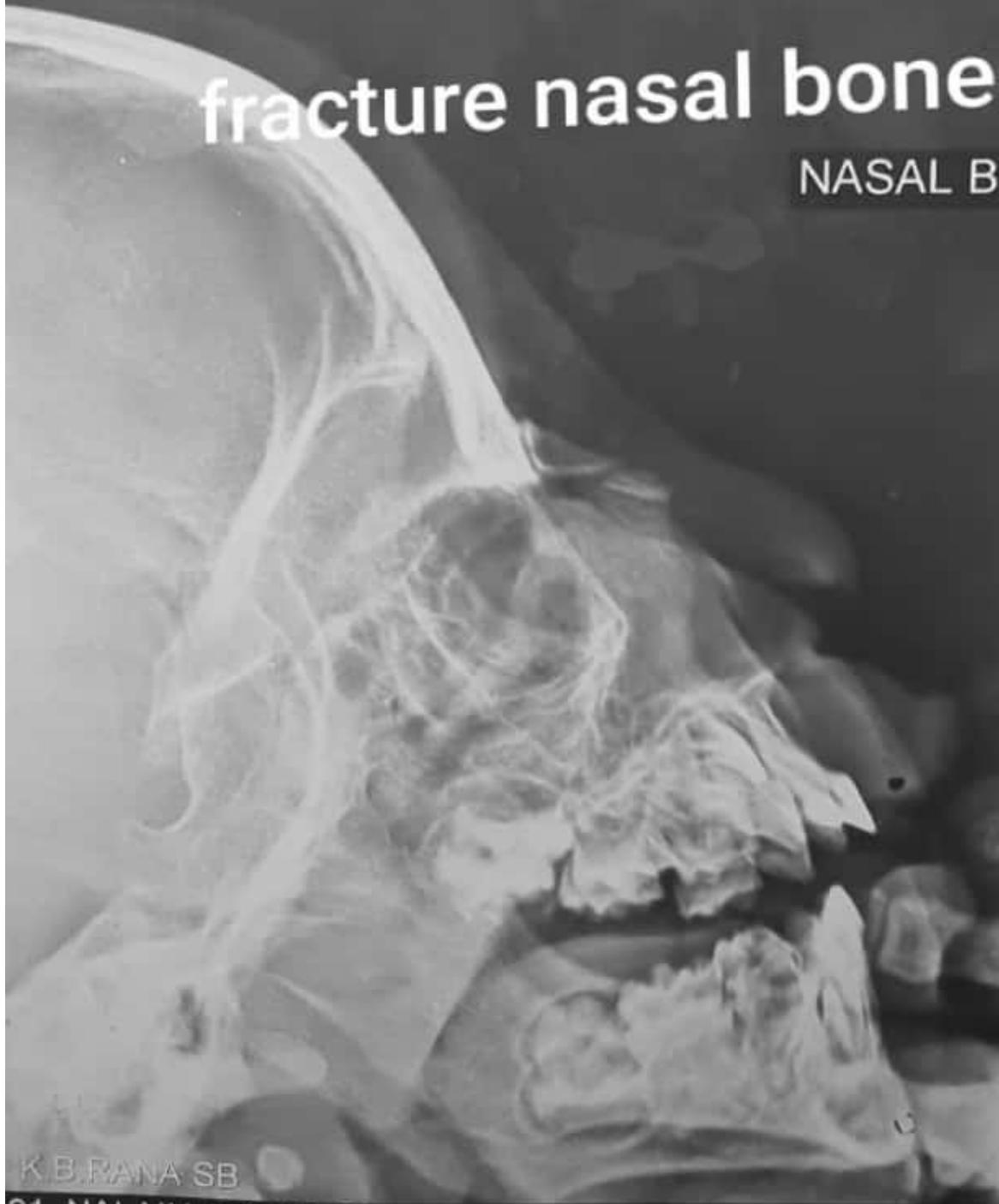CH.M.AKRAM TEACHING & RESEARCH HOSPITAL, RAIWAND ROAD LAHORE

trochar canula



fracture nasal bone

NASAL BONE LAT



K B RANA SB

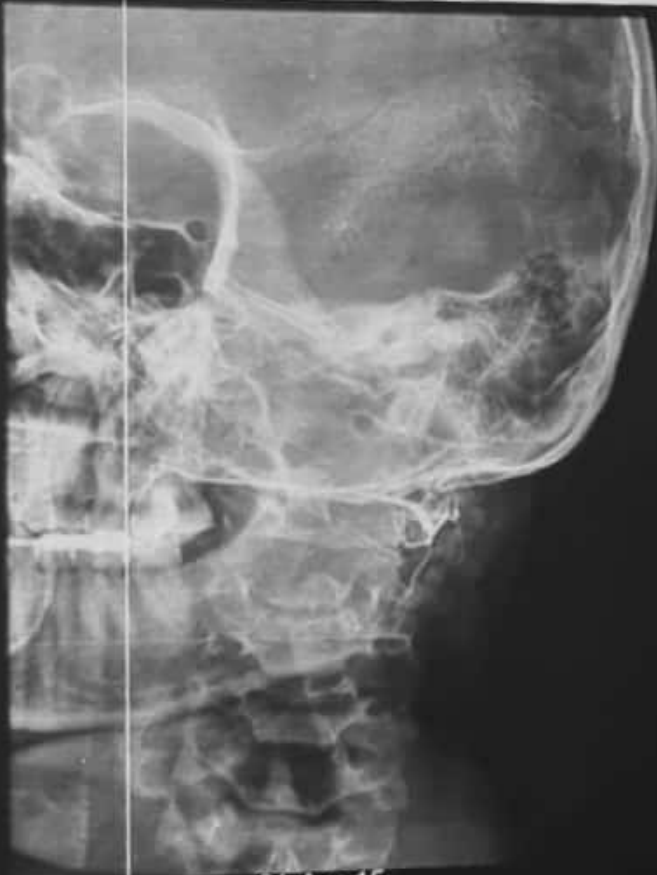91 NALAIN ABBAS M

4.2016

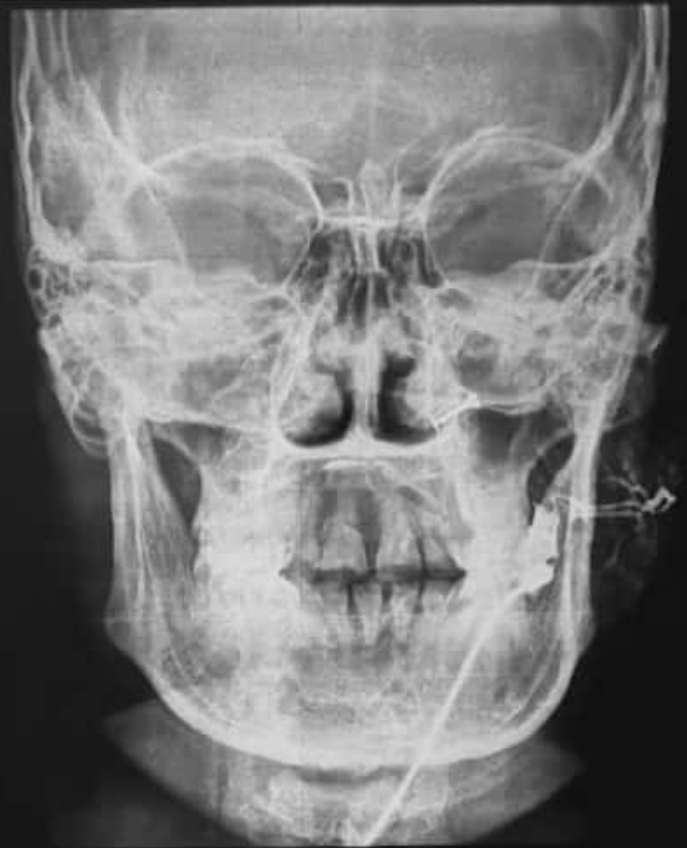ZI MEDICAL COMPLEX SARGODHA, 048-215999

sialogram

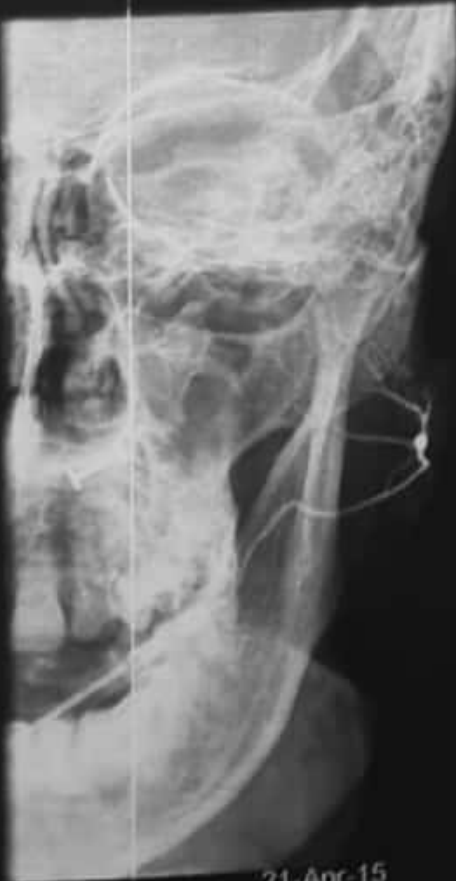normal



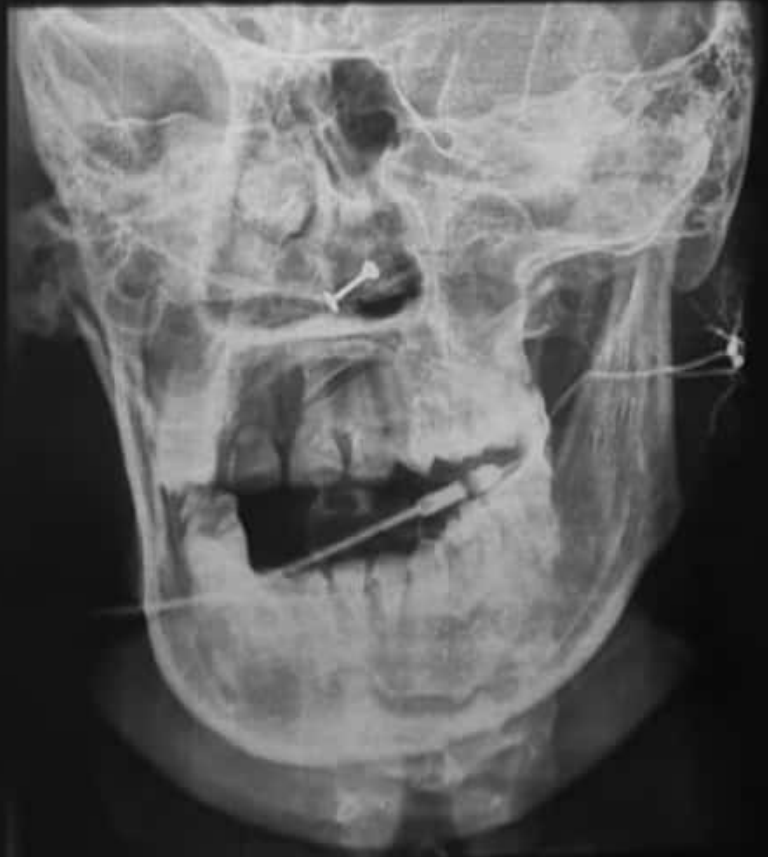21-Apr-15



63.0 %

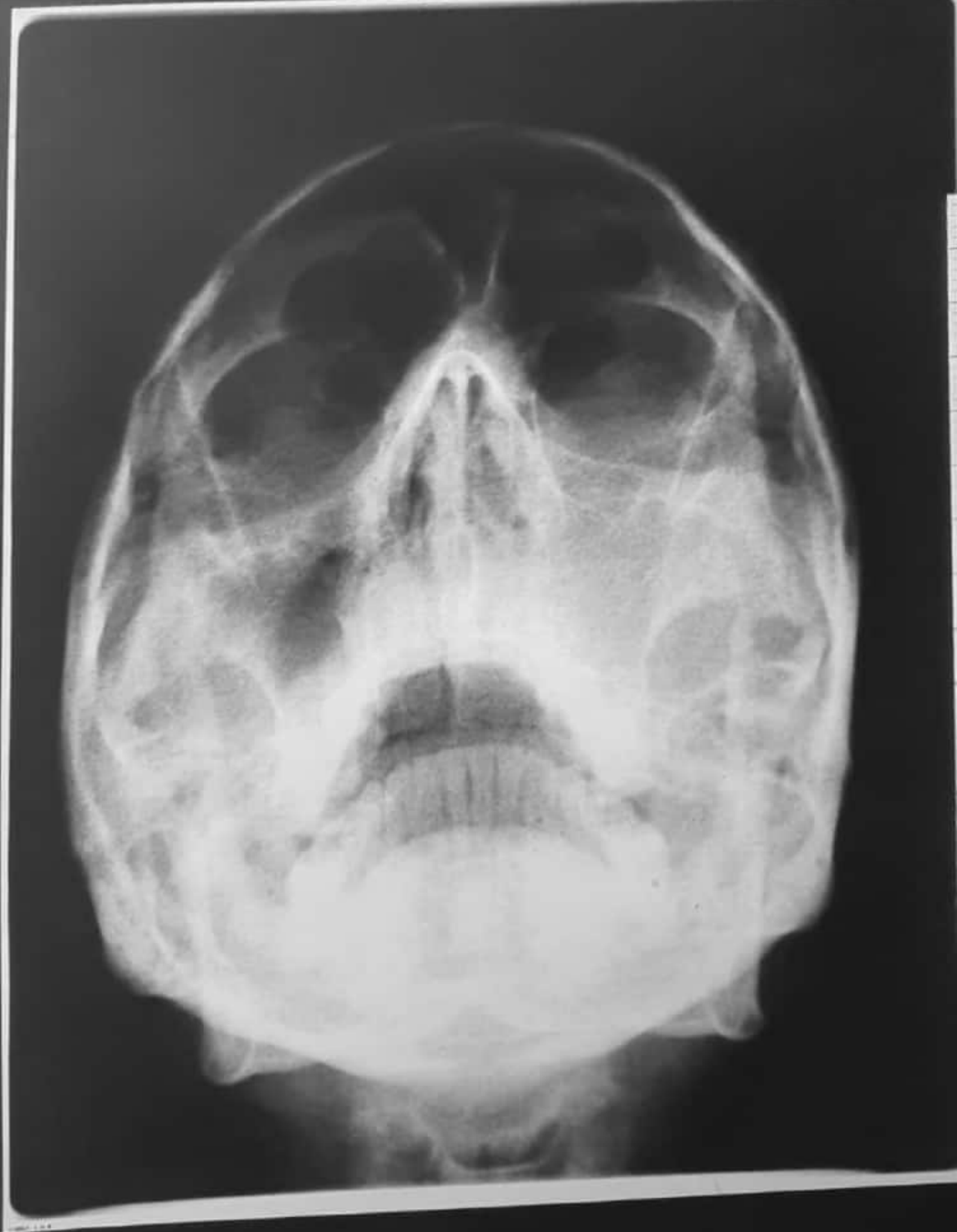

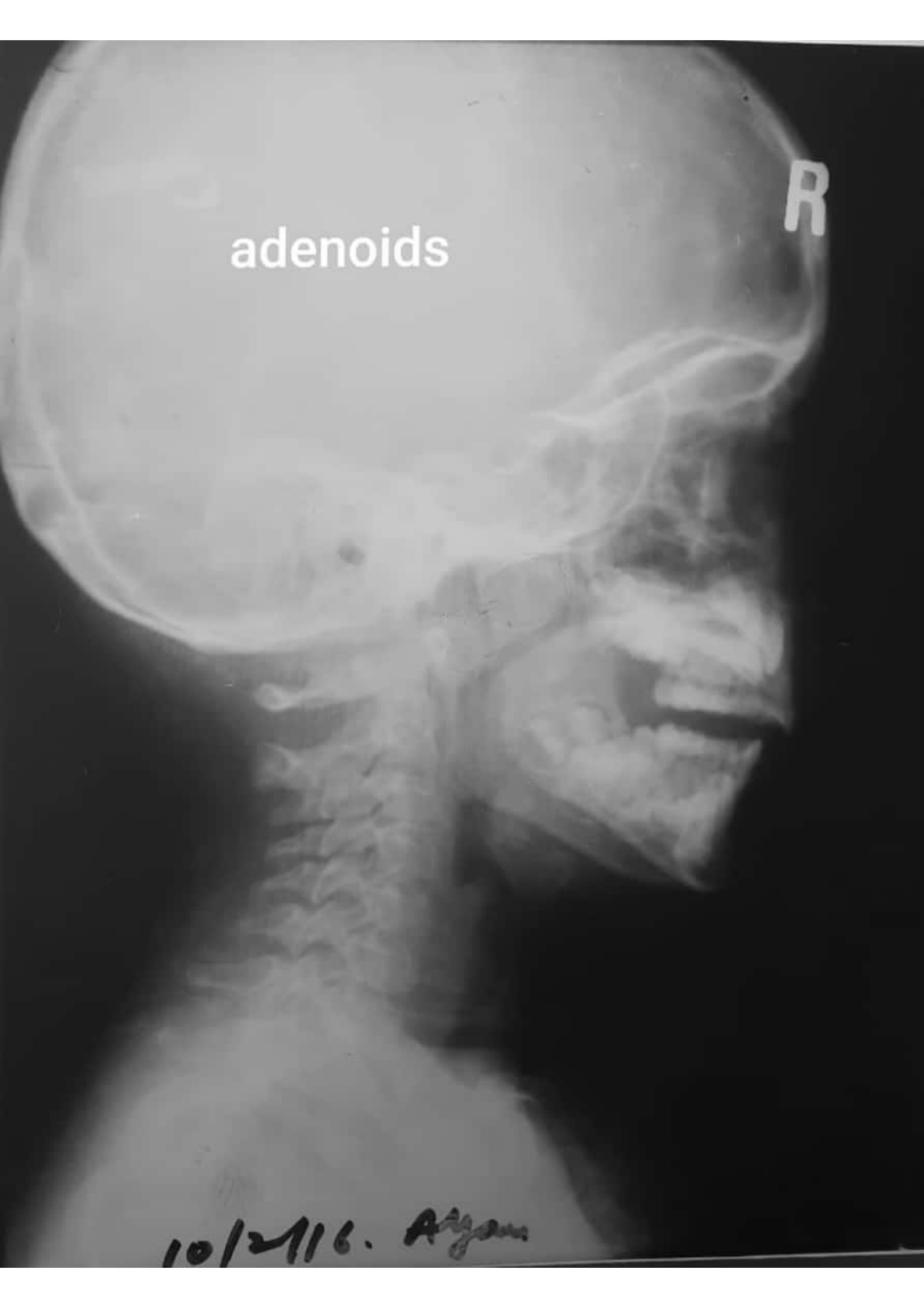
21-Apr-15



73.5 %

left sinusitis

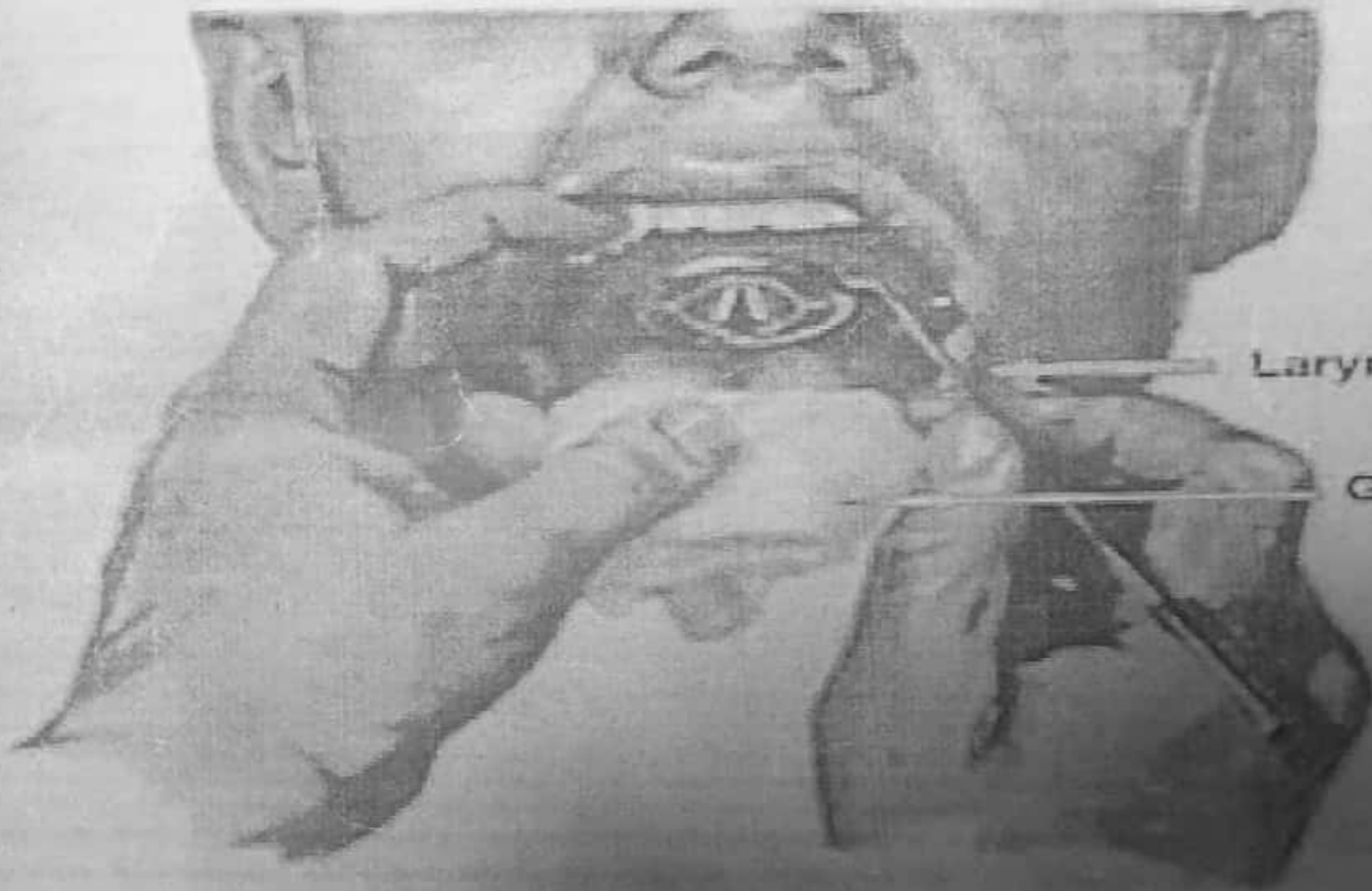




adenoids

R

10/2/16. Aygen

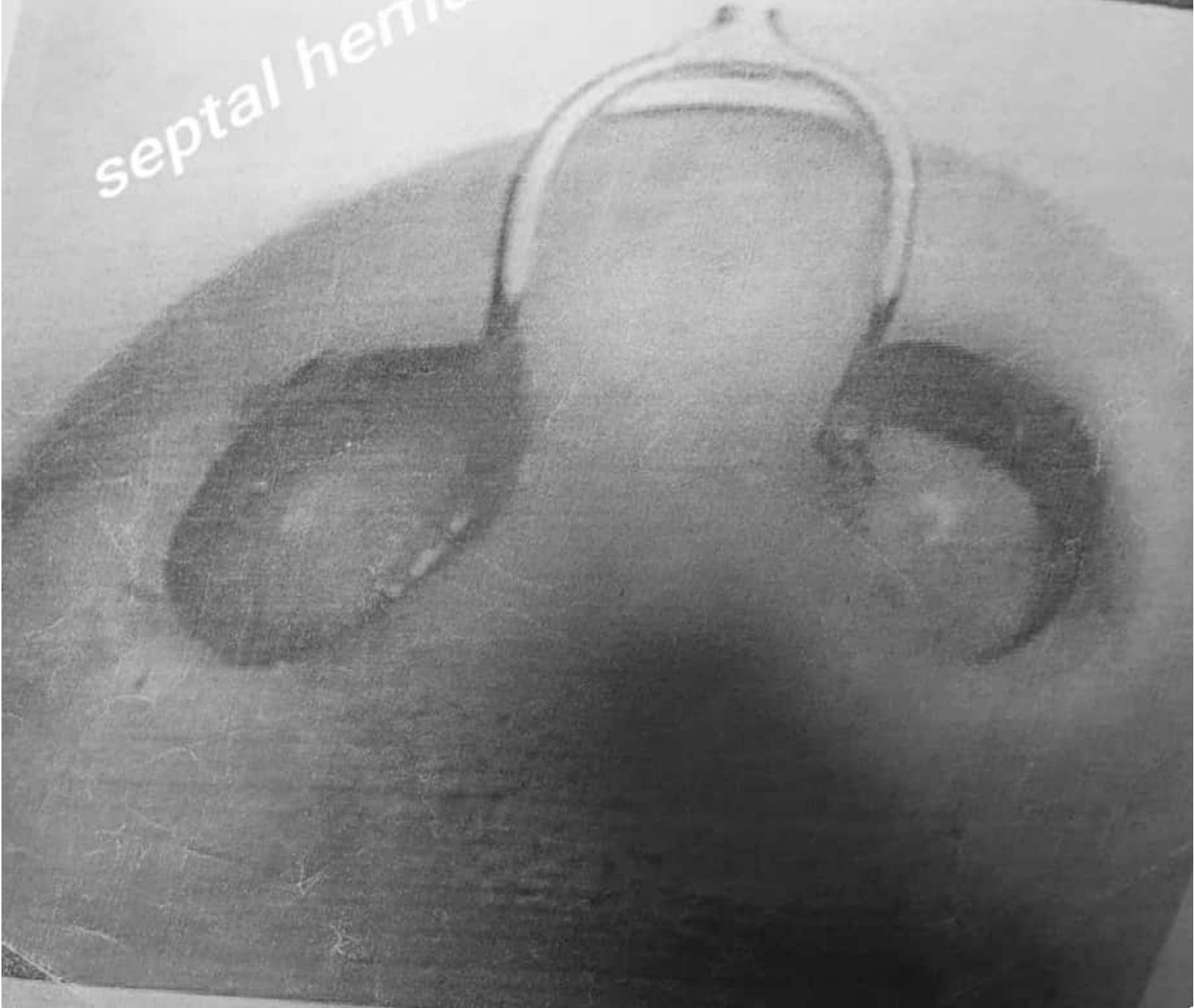


Laryngeal mirror

Gauze piece


Indirect Laryngoscopy

septal hematoma



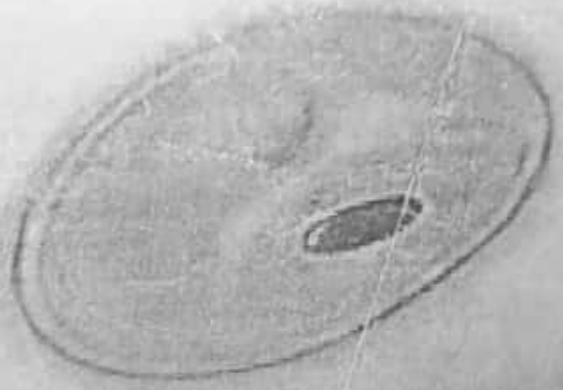

with tongue plate



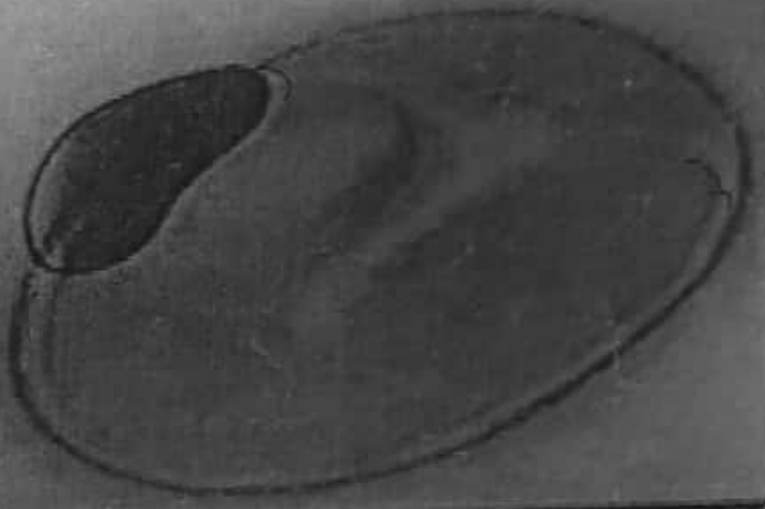direct laryngoscopy

perforation in tympanic membrane



attic

central



**boils devis mouth Gag
with out tongue plate**





