

FACE & NECK

- 1- orbicularis oculi
- 2- zygomatic major
- 3- orbicularis oris
- 4- parotid gland with emerging branches of facial nerve
- 5- facial artery
- 6- dorsal nasal (external carotid artery)
- 7- ^{anastomosis} supratrochlear (internal carotid artery)
- 8- superficial temporal artery) → terminal branch of external carotid artery)
- 9- External carotid artery
- 10- Thyroid gland
- 11- external jugular vein
- 12- inferior belly of omohyoid.




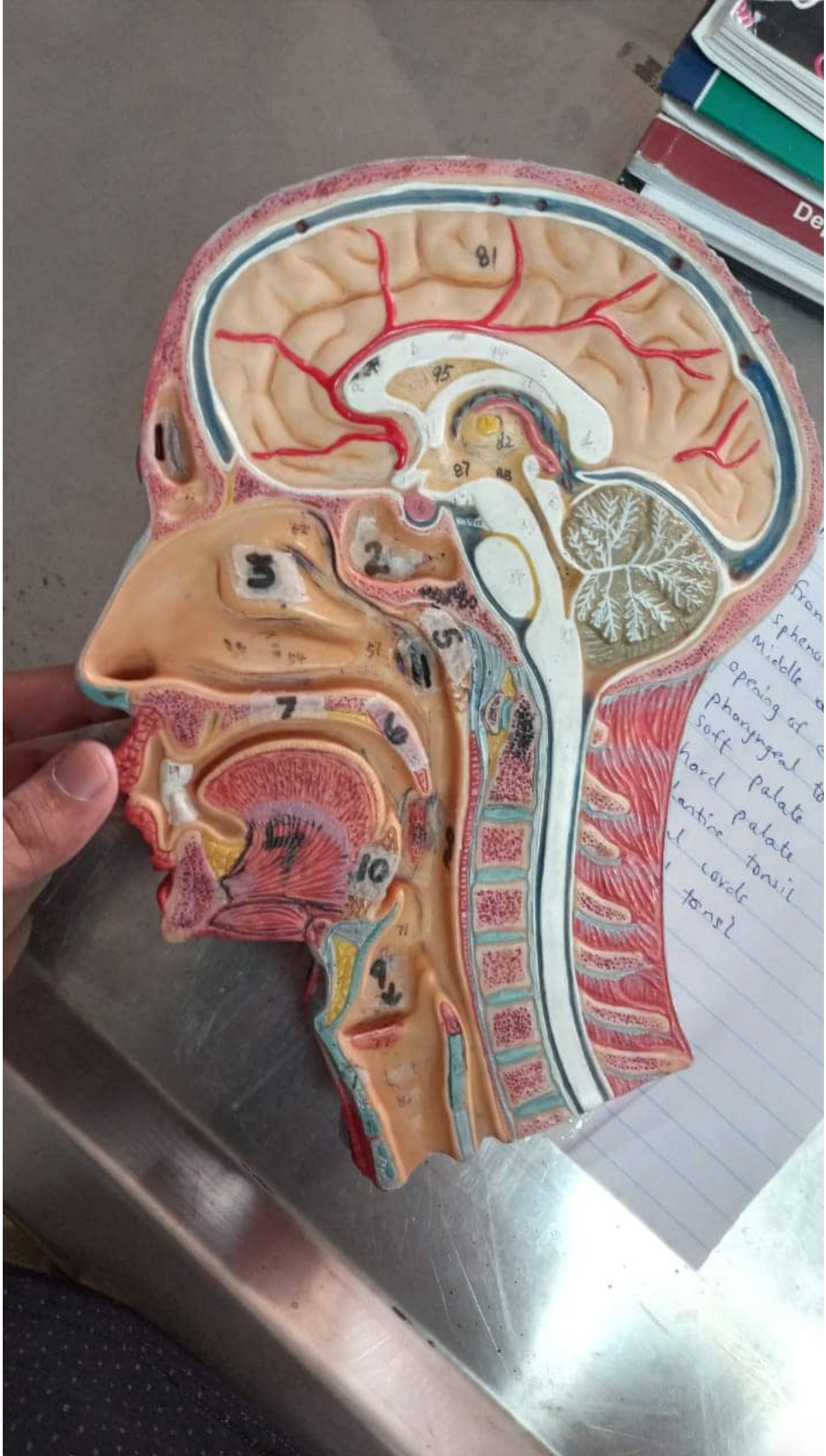


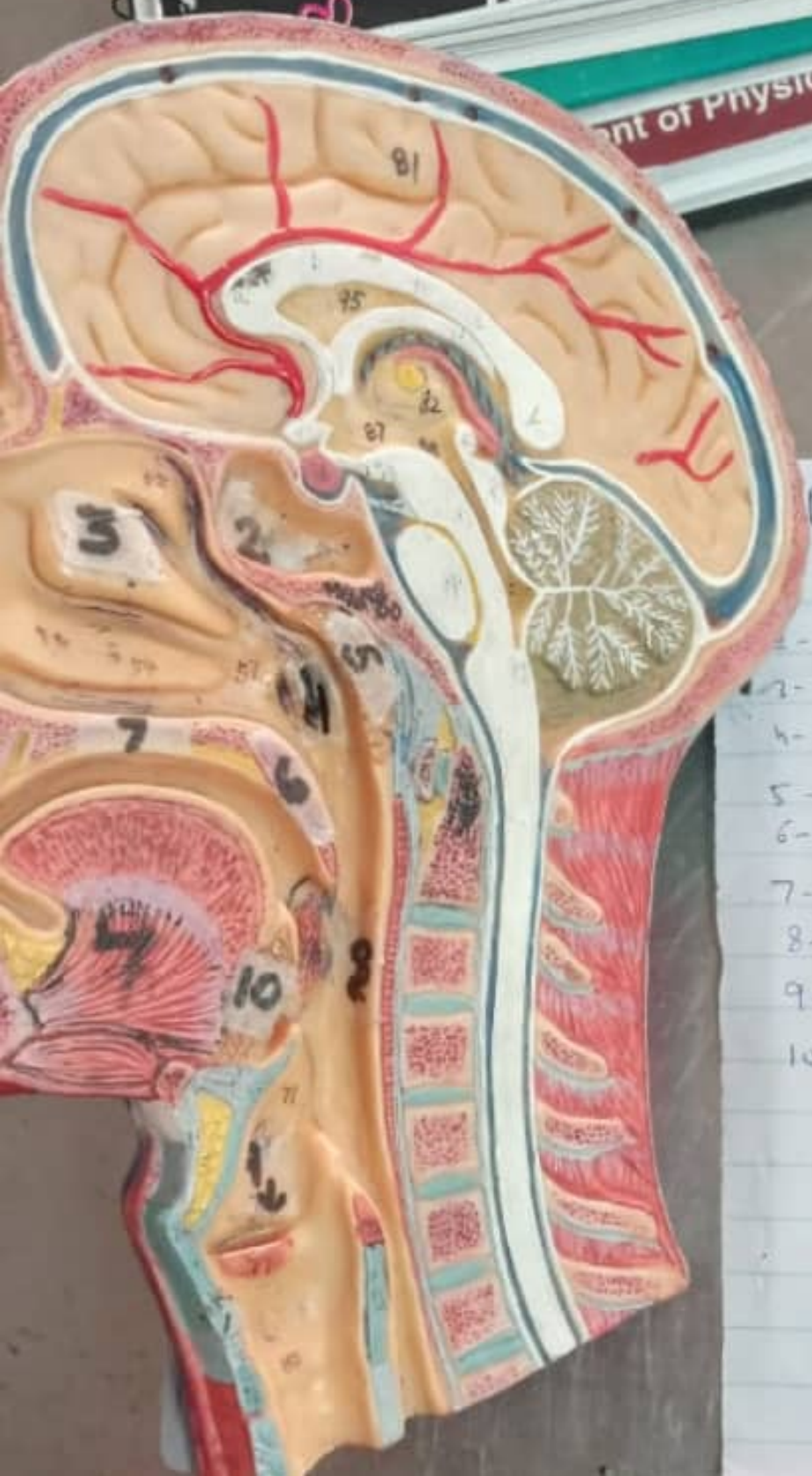
HUMAN
1. CEREBRUM
2. THALAMUS
3. CORPUS CALLOSUM
4. PONS
5. MIDBRAIN
6. MEDULLA OBLONGATA

FACE

- 1- orbicularis
- 2- zygomatic
- 3- orbicularis
- 4- parotid
branches
- 5- facio
- 6- do







PHARYNX Cut section (face + neck)

- 1- frontal sinus
- 2- sphenoid sinus
- 3- Middle nasal concha
- 4- opening of eustachian tube
- 5- pharyngeal tonsils
- 6- soft palate
- 7- hard palate
- 8- palatine tonsil
- 9- vocal cords
- 10- lingual tonsil