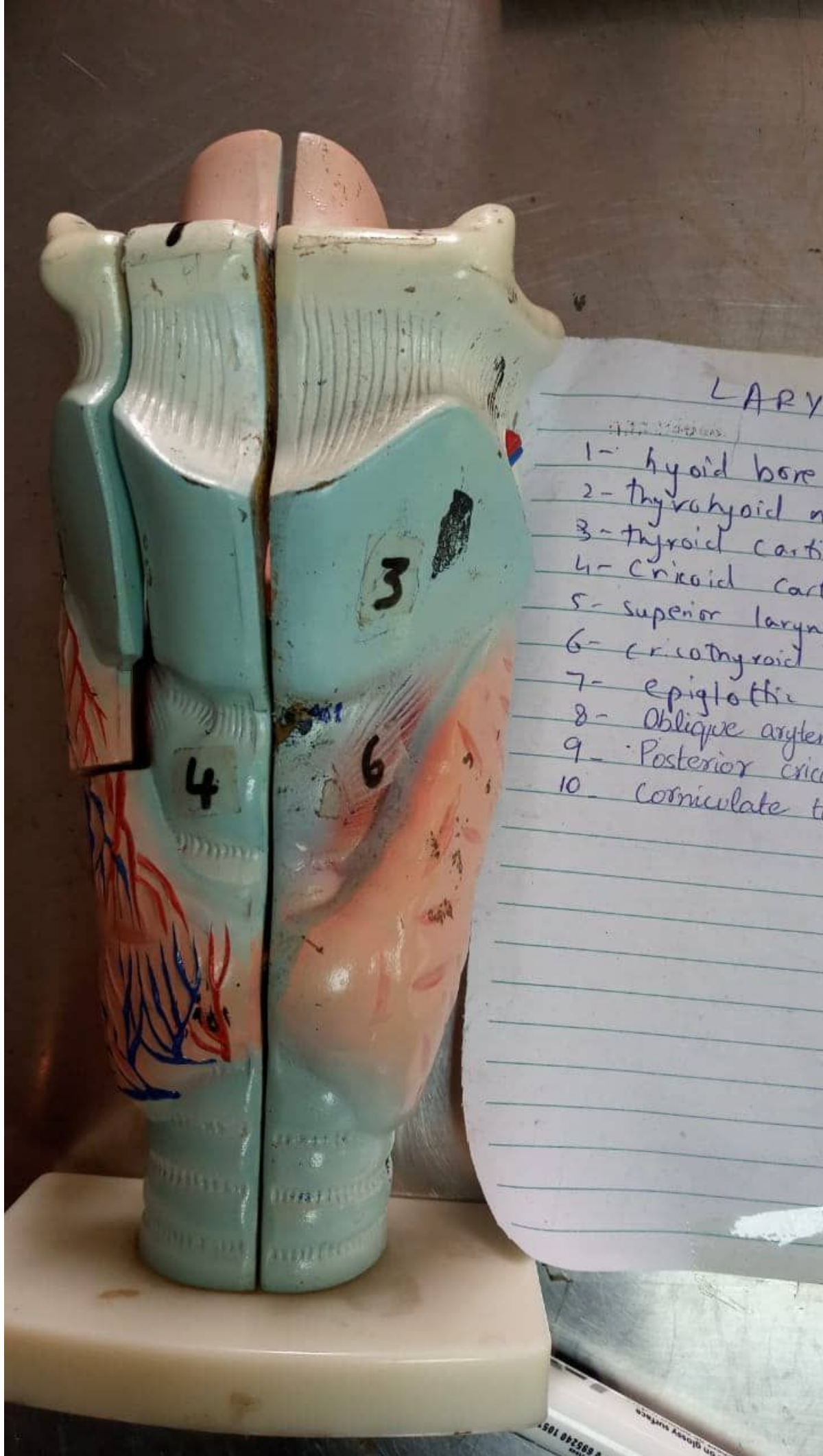



LARY

- 1- hyoid bone
- 2- thyrohyoid m
- 3- thyroid carti
- 4- Cricoid cart
- 5- superior larynx
- 6- cricothyroid
- 7- epiglottic
- 8- Oblique aryten
- 9- Posterior crico
- 10- Corniculate t

LARYNX

- 1- hyoid bone
- 2- thyrohyoid membrane
- 3- thyroid cartilage
- 4- Cricoid cartilage
- 5- superior laryngeal vessels
- 6- cricothyroid muscle
- 7- epiglottic fold
- 8- Oblique arytenoid muscle
- 9- Posterior cricoarytenoid muscle
10. Corniculate tubercle





- 1 - hyoid
- 2 - thyrohyoid
- 3 - thyroid
- 4 - cricoid
- 5 - superior
- 6 - cricoid
- 7 - epiglott
- 8 - oblique
- 9 - posterior
- 10 - cornicula