

Page # ①

P.M.R. No.

(DUPLICATE)

Page 1 of 4



Govt. of Punjab, Health Department

POST-MORTEM EXAMINATION REPORT

Book No.	1	Serial No.	1
Teaching Hospital:	DHQ / THQ / King Edward Medical University (KEMU) / MAYO Hospital, Lahore.	P.M.R. No.	1... 2021

NAME: Fatima AGE: 35 SEX: F CASTE: Mughal
 FATHER / HUSBAND NAME: Mohd Khan RESIDENCE: Johar Town LHR.

Body Brought By:

1- Name & Designation:	<u>Nadeem 2543/C</u>	Police Station:	<u>Johar Town LHR</u>
2- Name & Designation:	<u>Khalid 4125/HC</u>	DISTRICT:	<u>LHR.</u>

Body Identified By:

1- Name:	<u>Nasir Khan</u>	NIC No.	<u>35603-2888084-7</u>	Relation:	<u>Brother</u>
2- Name:	<u>Jubbar Ali</u>	NIC No.	<u>36603-2778422-7</u>	Relation:	<u>Brother</u>

DATE & TIME OF:

1) Death:	<u>22nd at 6:00 P.m</u>	2) Receiving Dead Body in Dead House:	<u>22nd at 9:00 P.m</u>
3) Receiving Complete Documents from Police:	<u>23rd at 10:00 A.m</u>	4) Conducting Autopsy:	<u>23rd at 11:45 A.m</u>

INFORMATION FURNISHED BY POLICE:

Handwritten Urdu text

DIAGNOSTIC TESTS:

Radiological:	<u>Nil</u>
Ultrasound:	<u>Nil</u>

I - EXTERNAL EXAMINATION

General Physical Appearance (Including length / weight of the body, Rigor Mortis, Post Mortem Staining, Putrefaction, Condition of eyes, Condition of natural orifices, Congestion, Patecheal Hemorrhages, etc.)

Examination of Clothes:	It is a dead body of an adult female who appears to be of above stated age. She is wearing pink, printed shawl qameez and white braizer. Lot of blood stains are present on her body and face and on clothes. Clothes labelled and handed over to police. Rigor mortis is fully developed and hypostasis is present on the back. Following injuries are found on her body - ^{Left} Black eye and subconjunctival haemorrhage present.
Examination of Neck:	
Description of Injuries:	

P.M.R.No.

(DUPLICATE)

Note: The Medical-Legal Examiner should mention size, weight, gross appearance, any evidence of trauma / disease / malfunctioning of all the organs & viscera externally & on cut section. If disease / injury / abnormality is detected, the word should be written.

Page 2

II - CRANIUM AND SPINAL CORD

SCALP	Stated	Injury # ① A lacerated wound, 8x2 cm
SKULL	Healthy	on left parietal region, bone exposed. It is 4 cm from left ear.
MEMBRANES	Healthy	5 cm from left ear. 150 ml of clotted and unclotted blood present in cranial cavity. No fracture seen
BRAIN	Stated	Injury # ② Laceration, 6x2 cm on left eye brow
VERTEBRAE	not opened	It is 5 cm from glabella, bone is exposed.
SPINAL CORD	Not opened	Injury # ③ - Laceration, 3x2 cm, below left eye.

III - THORAX

1- Walls, Sternum (Manubrium, Body Xiphisternum), Cartilages & Ribs.	Healthy	Injury # ④ = Lacerated wound, 2x1 cm
2- Pleurae	Healthy	above left upper lip
3- Hyoid Bone, Larynx & Trachea	Healthy	Injury # ⑤ - An incised wound, 9x6 cm
4- Right Lung	Healthy	on front and sides of neck. It is 9 cm below chin.
5- Left Lung	Healthy	on dissection
6- Pericardium & Heart	Healthy (Empty) No blood	All major blood vessels of neck and trachea has been cut.
7- Blood Vessels	Healthy	

Injury # ⑥ Incised wounds each, 1x0-3 cm

on palmar aspect of right index and thumb. p10

IV - ABDOMEN

1- Walls	Healthy	(9) - Multiple Small, each
2- Peritoneum	Healthy	0.5 x 0.2 cm on dorsal aspect of
3- Mouth, Pharynx and Esophagus	Healthy	left hand.
4- Diaphragm	Healthy	Fresh and clotted blood is present
5- Stomach and its contents	Healthy	in all wounds
6- Pancreas	Healthy	
7- Small Intestine and its contents	Healthy	
8- Large Intestine and its contents		
9- Liver	Healthy	
10- Spleen	Healthy	
11- Kidney	Healthy	Right:
		Left:
12- Urinary Bladder	Healthy Empty	
13- Organs of Generation <small>(External & Internal) Mention condition of testes in Male & uterus and ovaries in Female.</small>		no fetus in uterus and no signs of violence on genitalia

V - UPPER AND LOWER LIMBS

	Injuries	Disease / Deformity	Fracture	Dislocation
Upper Limb	Nil	Nil	Nil	Nil
Lower Limb	Nil	Nil	Nil	Nil.

P.M.R.No.

Specimens Sent for Expert Opinion to:

Chemical Examiner (Preserved in Saturated Saline)	Histopathologist (Preserved in 10% Formalin)	DNA (Preserved according to instructions by DNA Lab)	Ballistic Expert
N/L	N/L	N/L	N/L

OPINION: The injuries stated above are antemortem and caused by blunt weapon (injury # 1 to 4) and by sharp edged weapon (injury # 5 to 7). The Cause of death in this case is damage to major blood vessels of the neck leading to haemorrhagic shock and death. This injury is sufficient to cause death in ordinary course of nature. Injury # 1 is Probable Time that Elapsed:- fatal as well with in a few minutes.

(a) Between Injury and Death

fatal as well with in a few minutes.

(b) Between Death & Post Mortem

12-24 hours

Dated: 23/2/21

مذکورہ جرحیں ہمدردی سے لگائی گئی ہیں اور جرحوں کا پتہ اور پوسٹ مارٹم رپورٹ پولیس کا قذافیہ ریکارڈ سے فراہم نہیں ہو سکا۔
 Samples لے کر لیبارٹری تجزیہ کے لیے روانہ کیے گئے۔
 ریکارڈ پولیس کا تعلق، تحقیقی دفتر، ساجد خان، قاتلہ وکیل، جوہر ٹاؤن، لاہور۔
 تانہ نمبر 25484/1
 تاریخ 23/2/21

Reports of LAB Expert:

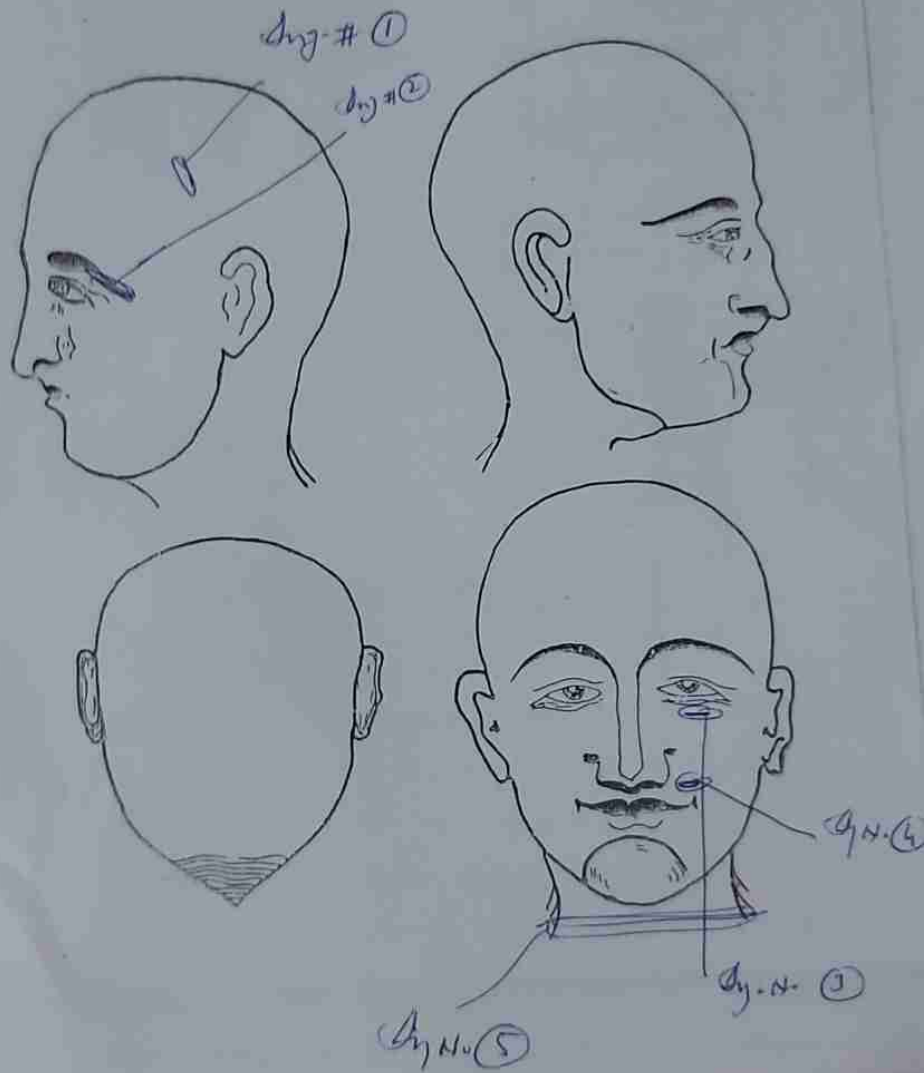
3

FINAL OPINION:

S/d:

Dated:

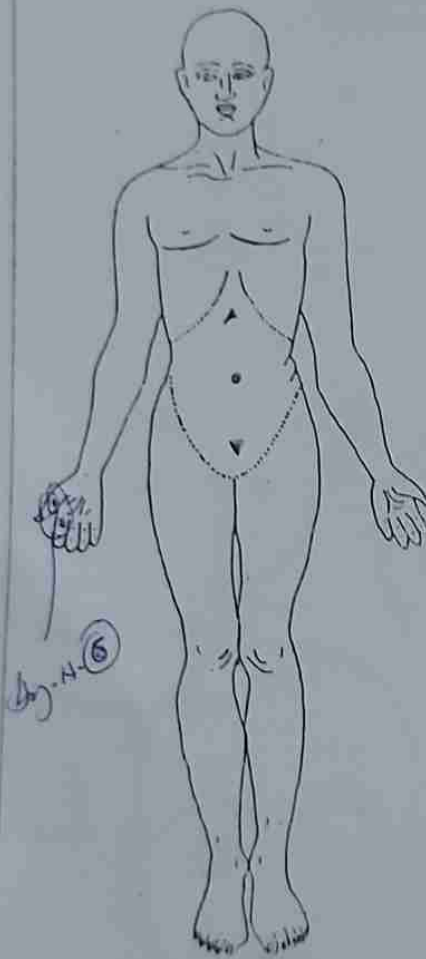
Out Lines of Human Head



Page #1 (6)

Out Lines Of the Body For Leading Injuries of Dead Bodies

Front



Back

