

FLATTENING





LABORATORY OF FORENSIC

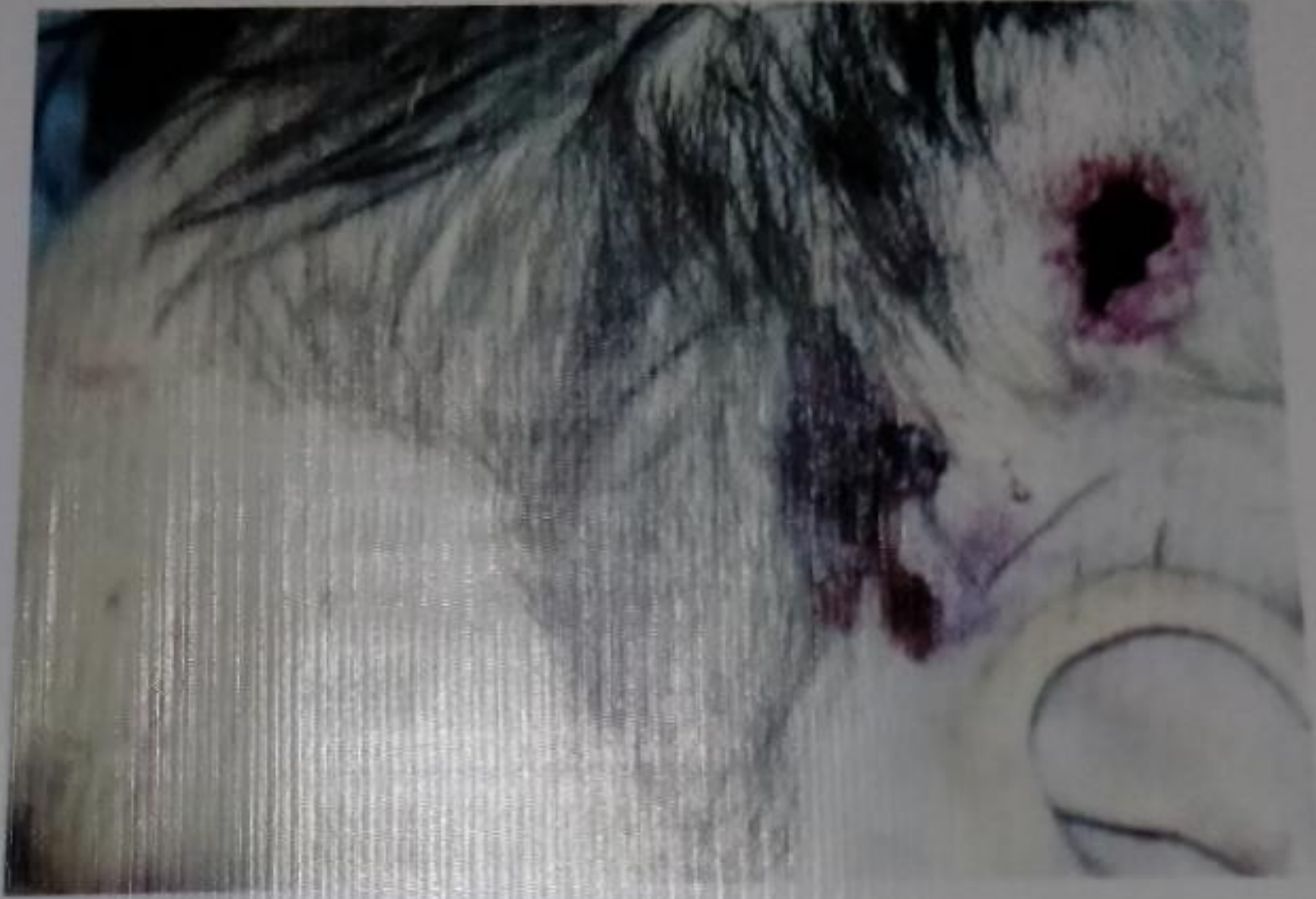FINE FROTH OF DROWNING

AMMUNITION (BULLETS & CARTRIDGES)



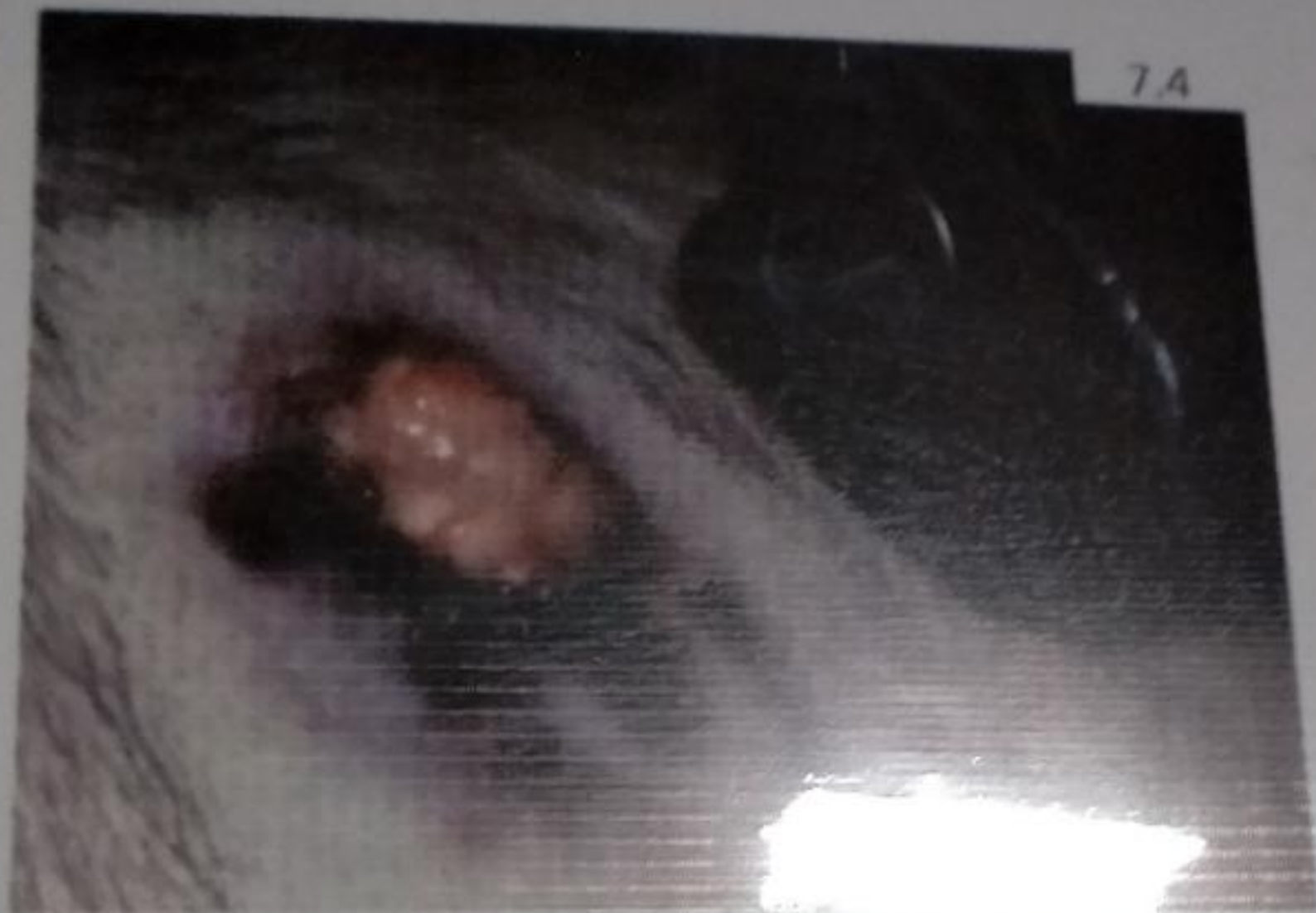Department of
Forensic Medicine & Toxicology
Azra Naheed Medical College

RIFLED FIREARM EXIT
WOUND ON HEAD



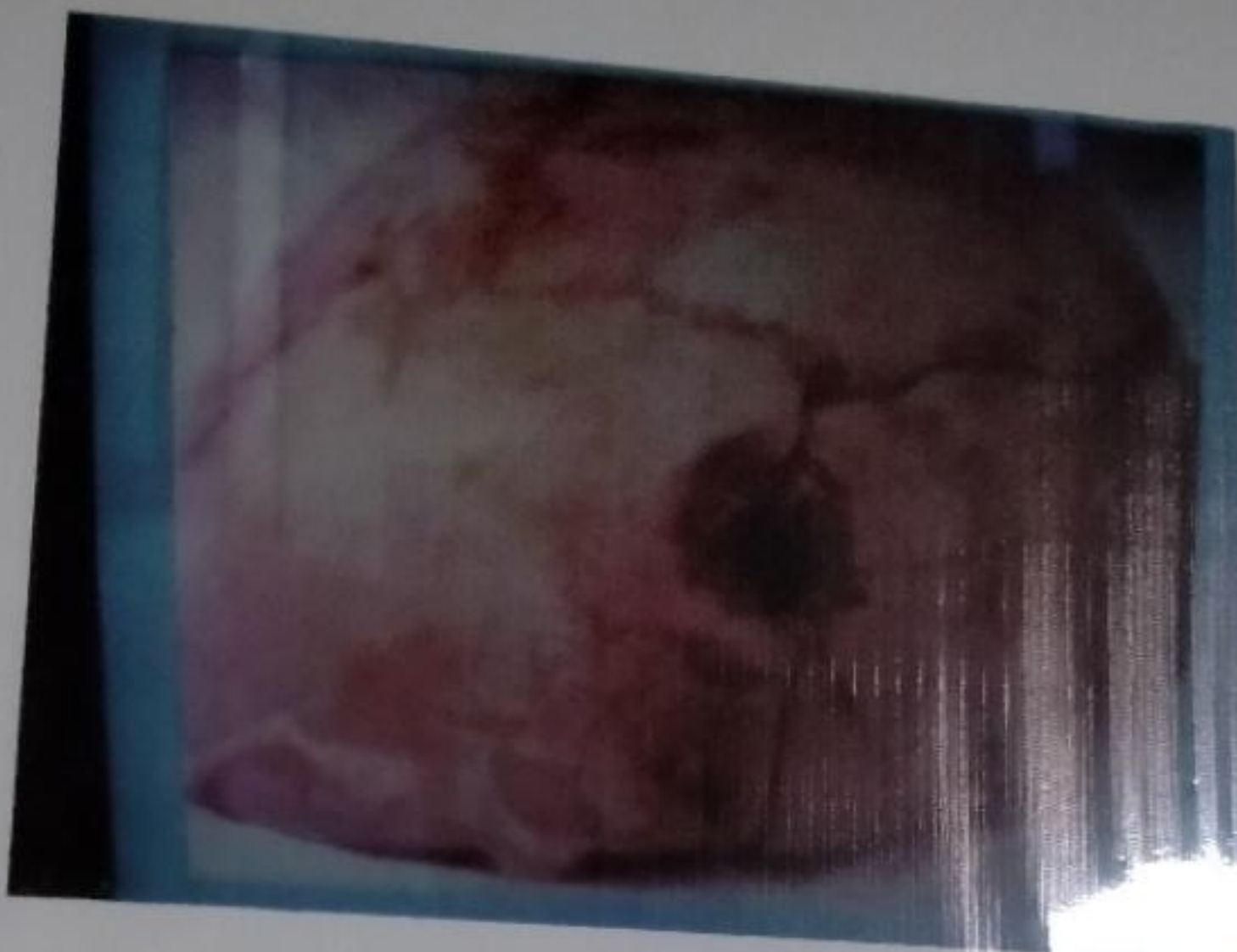Department of
Forensic Medicine & Toxicology
Azra Naheed Medical College

IMPRINT BRUISE DUE TO PRESSURE
OF MUZZLE END OF BARREL



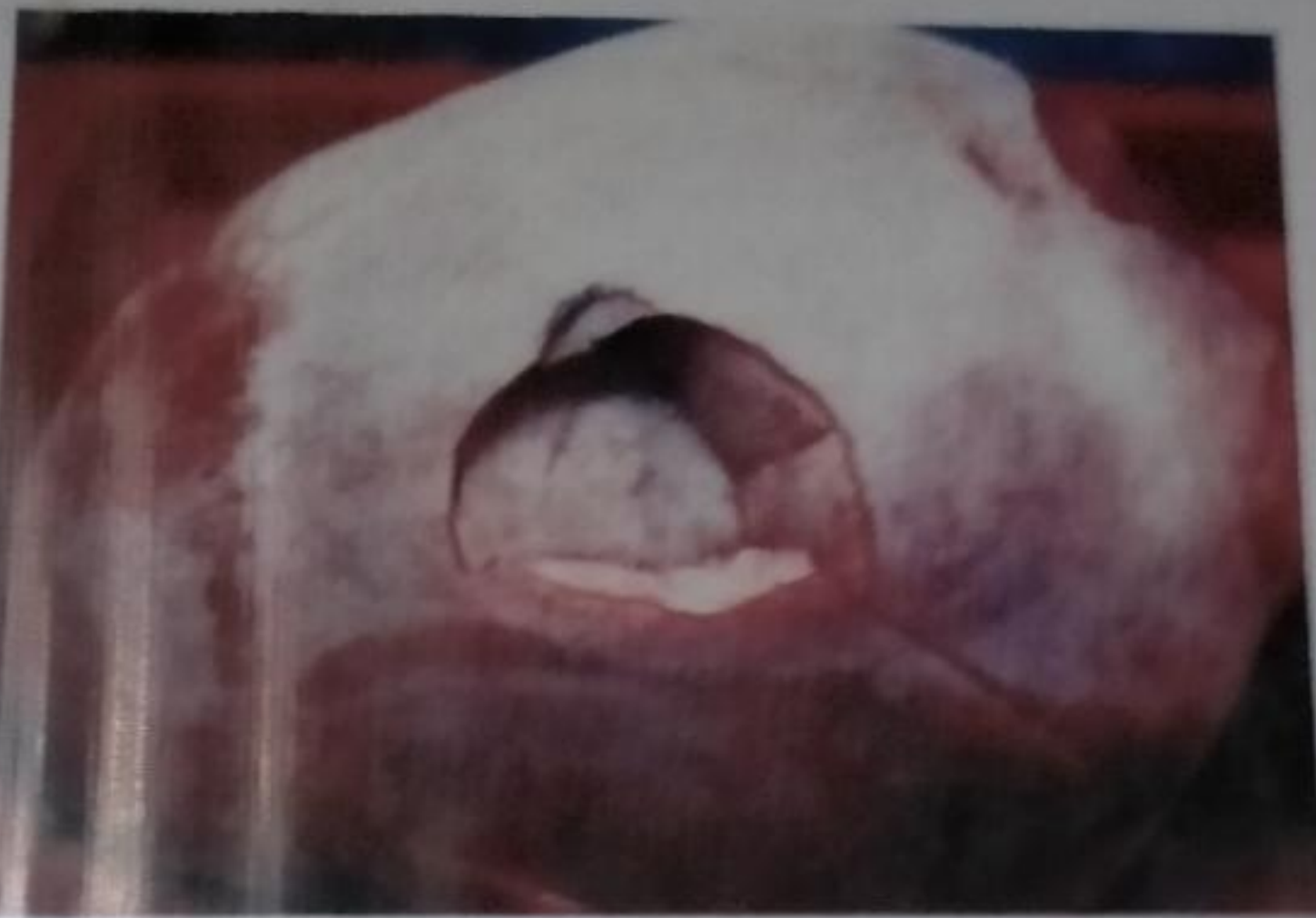Department of
Forensic Medicine & Toxicology
Azra Naheed Medical College

BEVELING IS PRESENT IN
EXIT WOUND ON SKULL



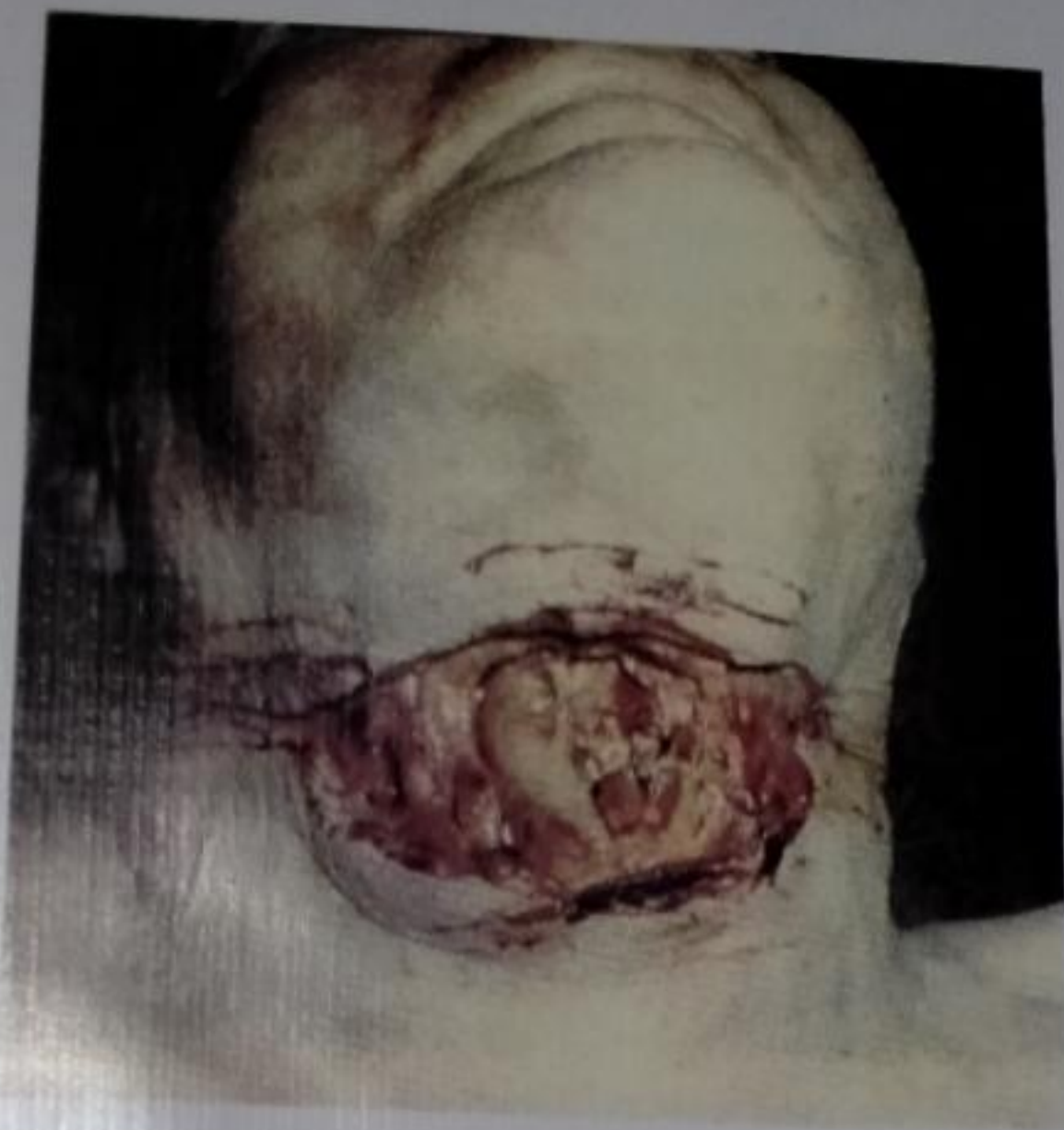Department of
Forensic Medicine & Toxicology
Azra Naheed Medical College

DEPRESSED FRACTURE SKULL



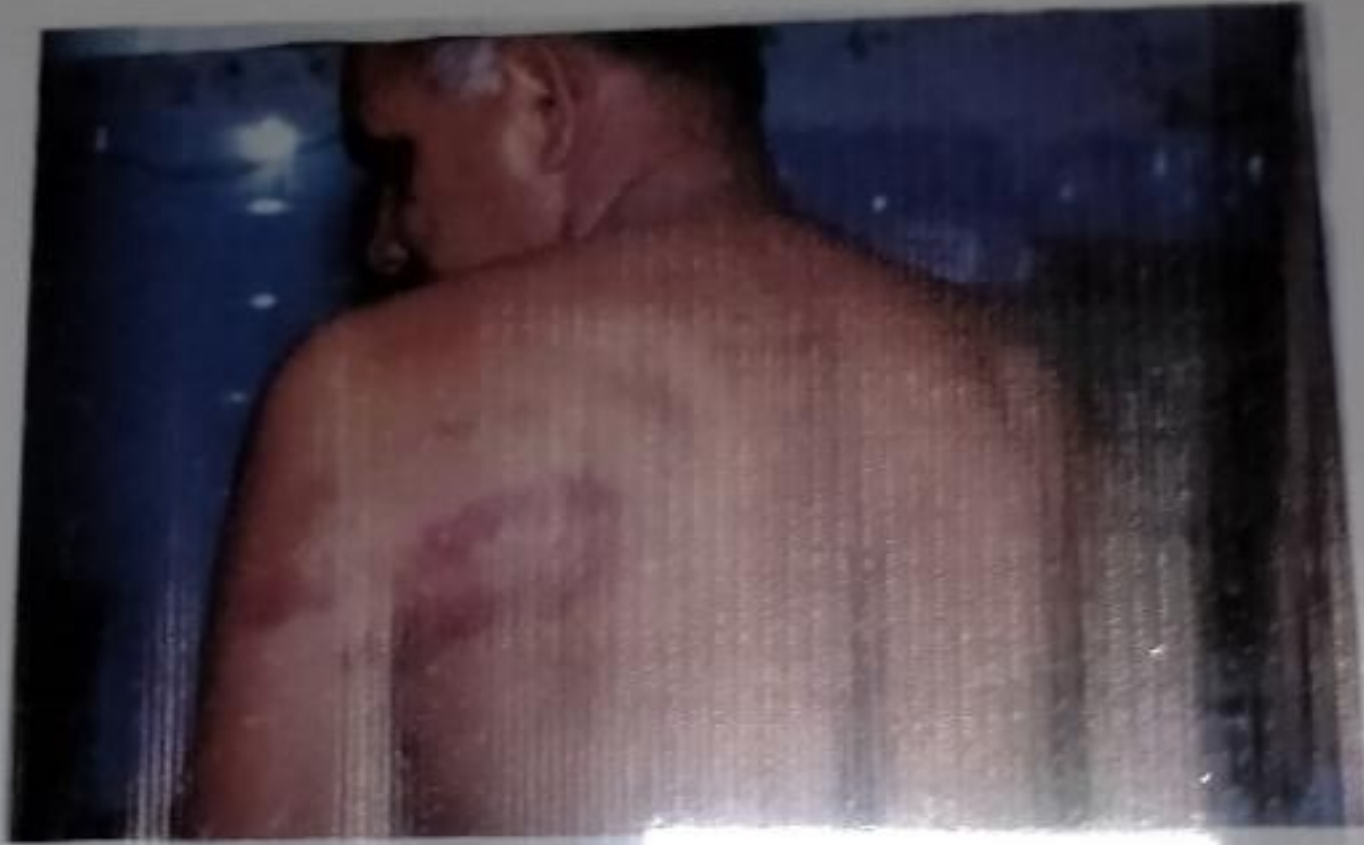Department of
Forensic Medicine & Toxicology
Azra Naheed Medical College

SUICIDAL CUT THROAT



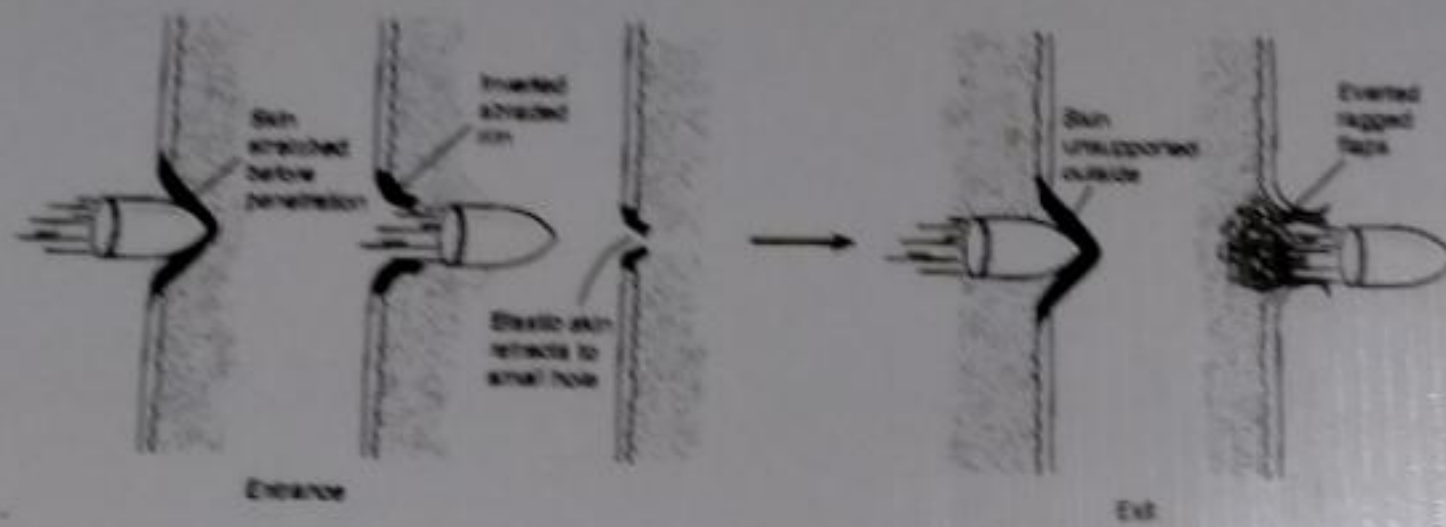
Department of
Forensic Medicine & Toxicology
Azra Naheed Medical College

BRUISE ON CHEST AND ARM



Department of
Forensic Medicine & Toxicology
Azra Naheed Medical College

TRAVEL OF BULLET THROUGH BODY



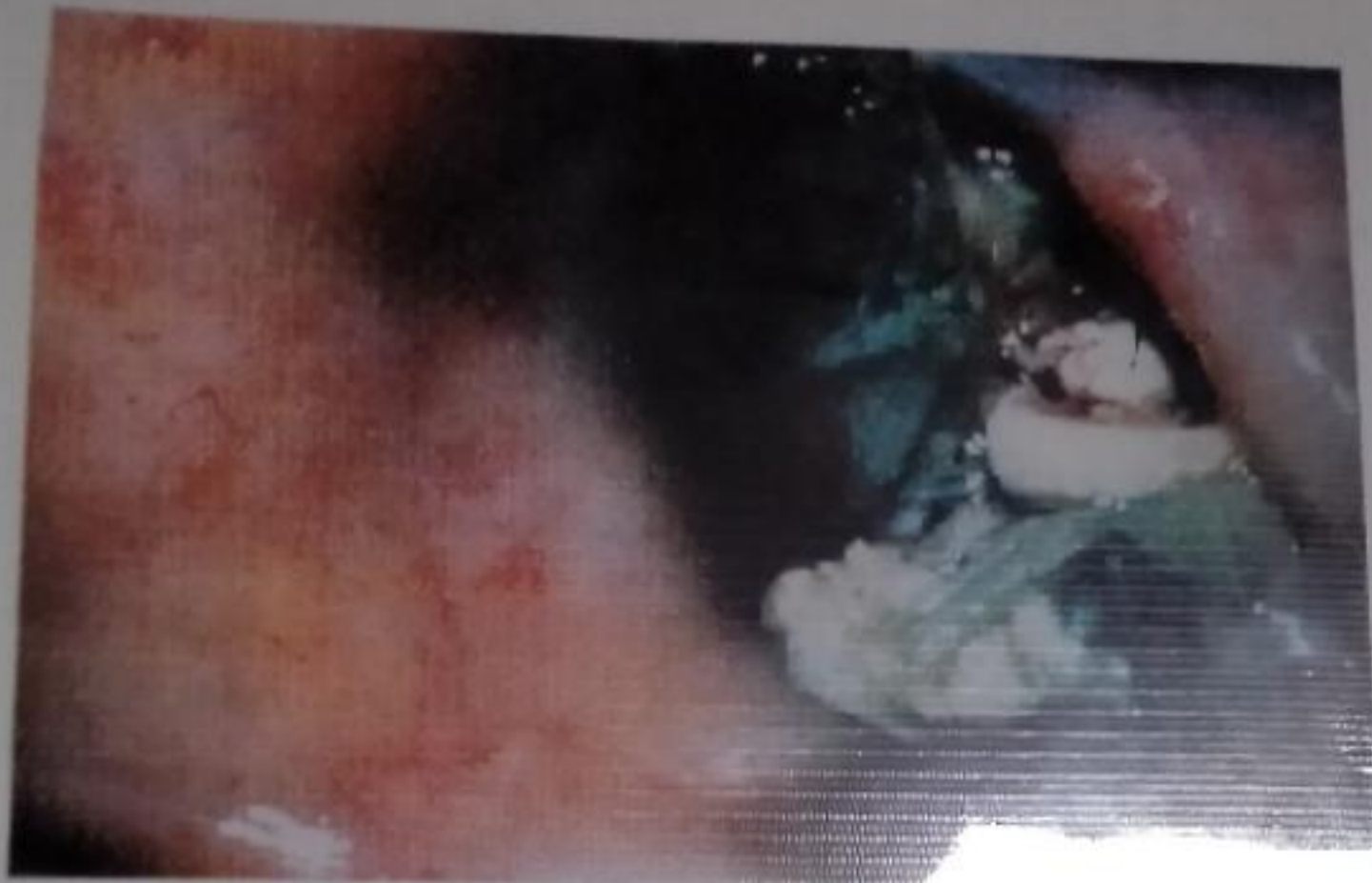Department of
Forensic Medicine & Toxicology
Azra Naheed Medical College

ASPHYXIAL DEATH SHOWING PATECHIAL
HAEMORRHAGES



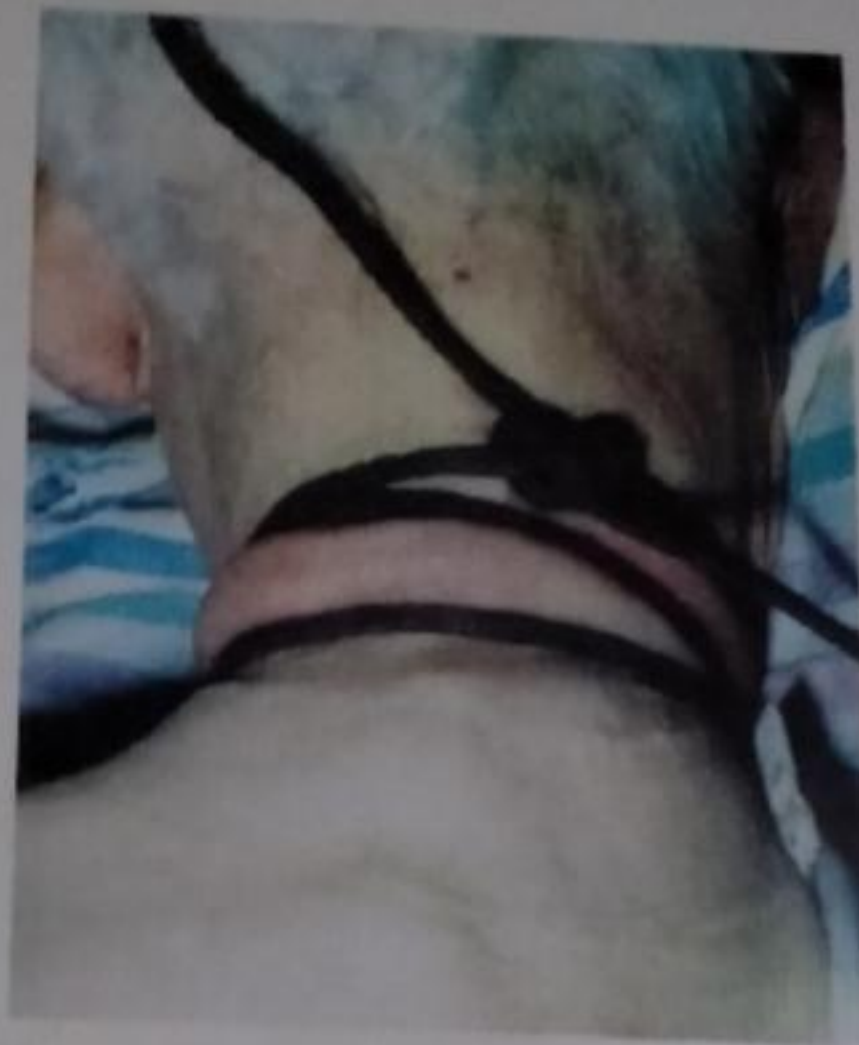Department of
Forensic Medicine & Toxicology
Azra Naheed Medical College

BOLUS OF MEAT IN LARYNX



Department of
Forensic Medicine & Toxicology
Azra Naheed Medical College

STRANGULATION

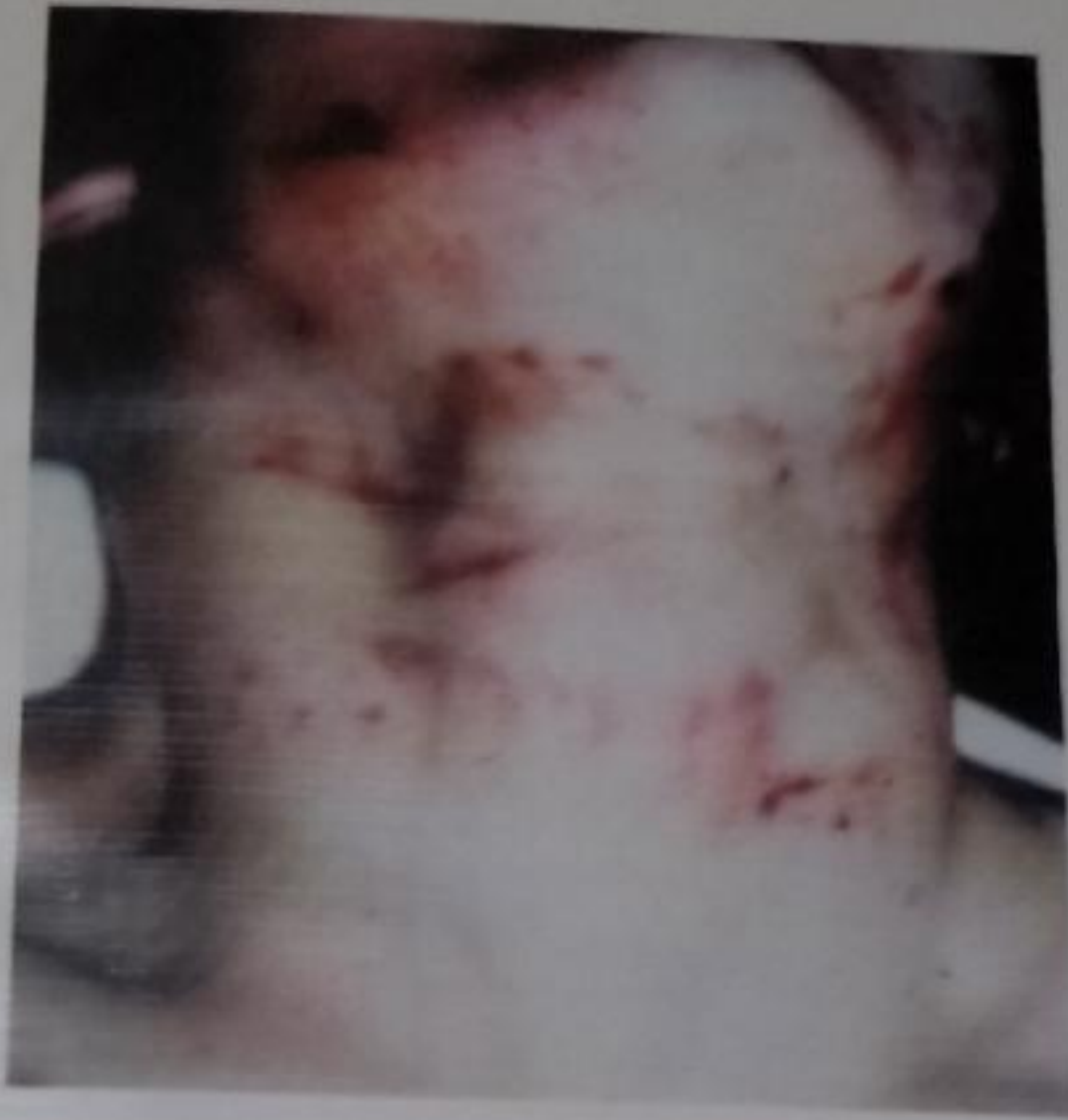

Department of
Forensic Medicine & Toxicology
Azra Naheed Medical College

Steps of Handwashing
with Hand Sanitizer



CASE OF THROTLING SHOWING
ABRASIONS AND BRUISES



Department of
Forensic Medicine & Toxicology
Azra Naheed Medical College

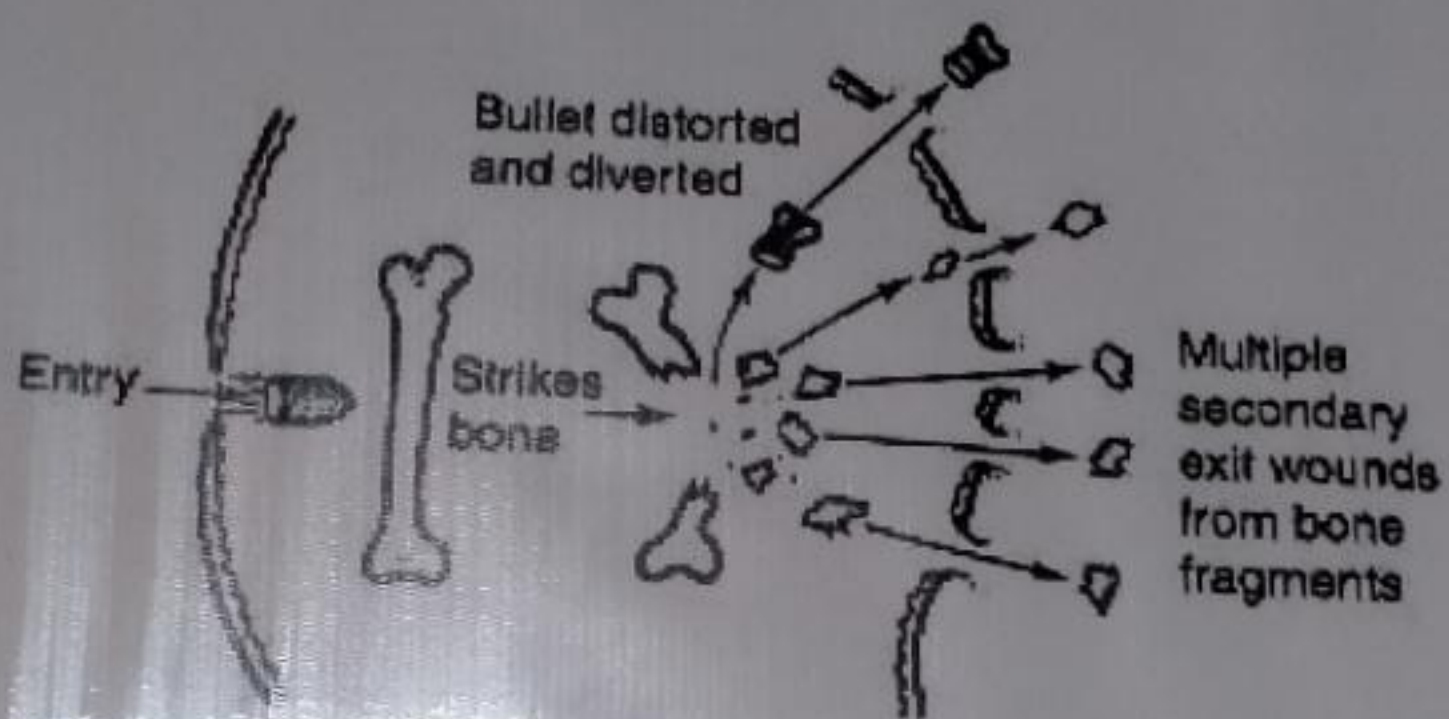
The 10 Most Common Causes of Infection



WASH YOUR HANDS

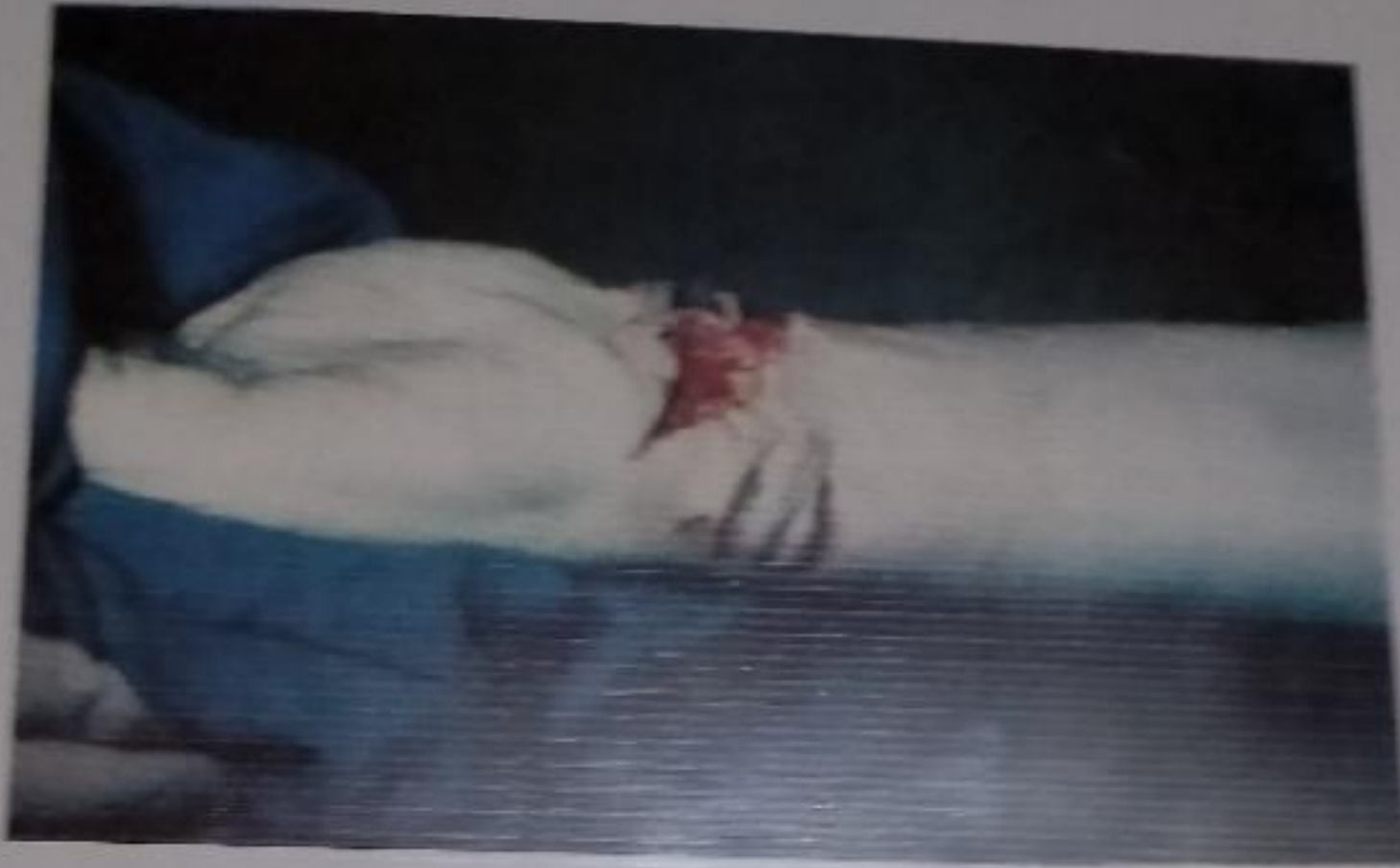

SECONDARY MISSILE EFFECT IN FIREARM INJURY



Department of
Forensic Medicine & Toxicology
Azra Naheed Medical College

SUICIDAL CUT ON WRIST



Department of
Forensic Medicine & Toxicology
Azra Naheed Medical College

Step-3



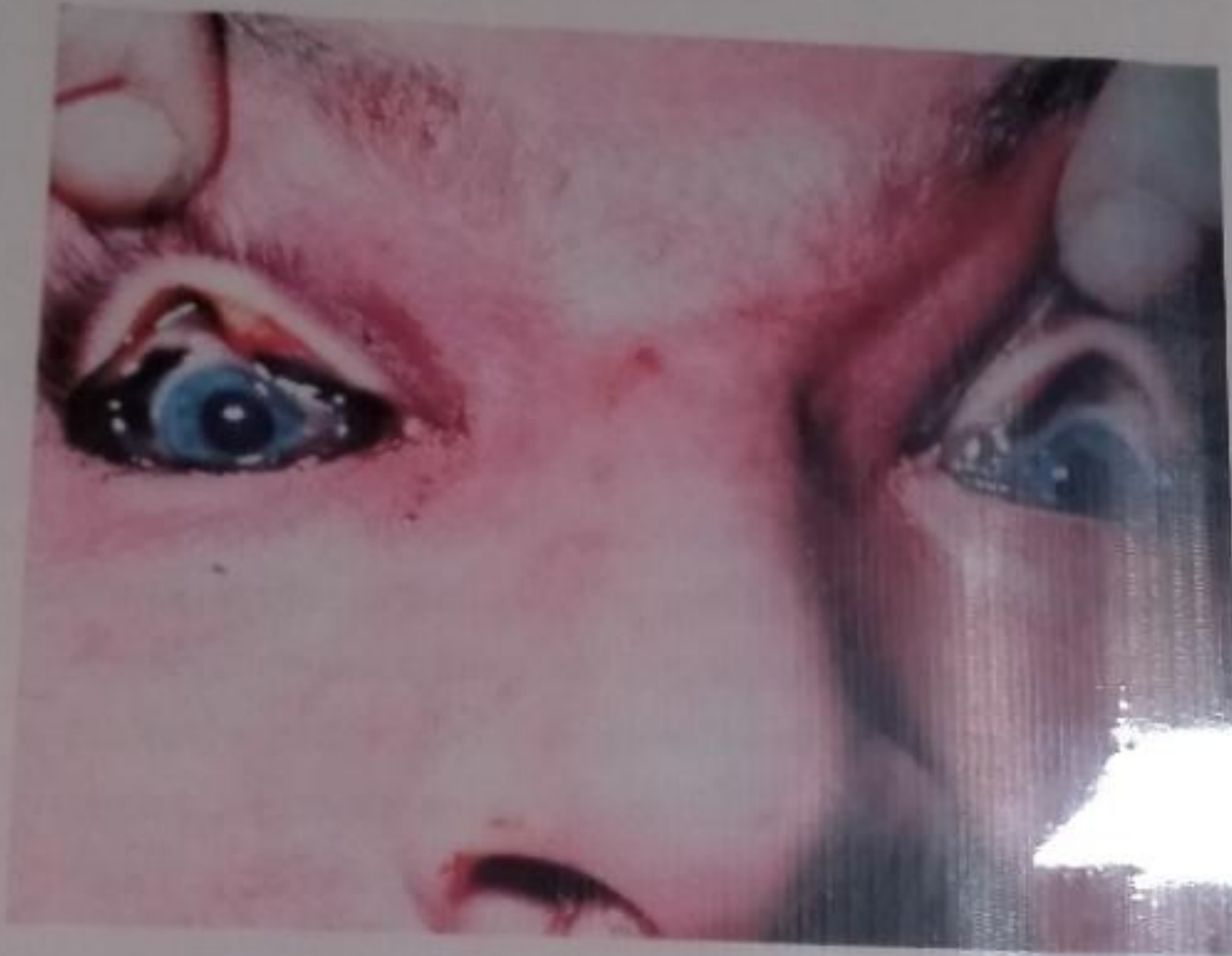Interlace fingers
and rub the
hands together.

Step-5

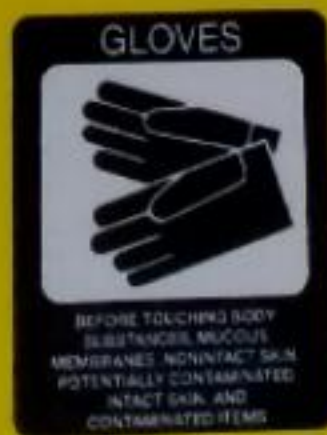
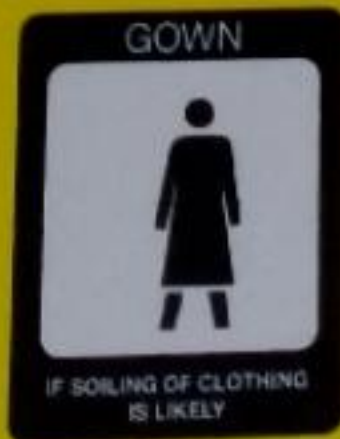
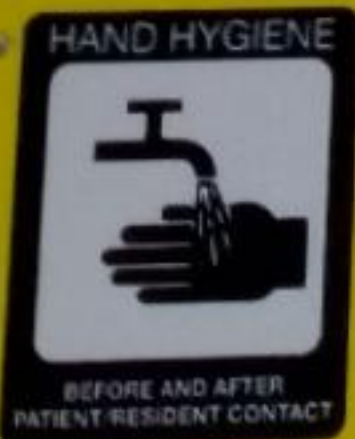... in a rotating manner

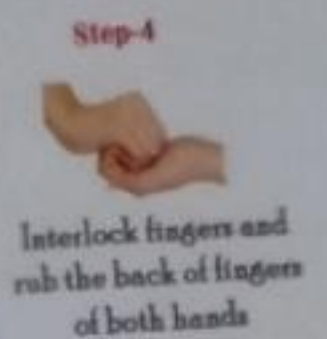


ASPHYXIAL DEATH SHOWING CONGESTION
PATECHIAL HAEMORRHAGES IN EYES
AND ON THE FACE



Department of
Forensic Medicine & Toxicology
Azra Naheed Medical College

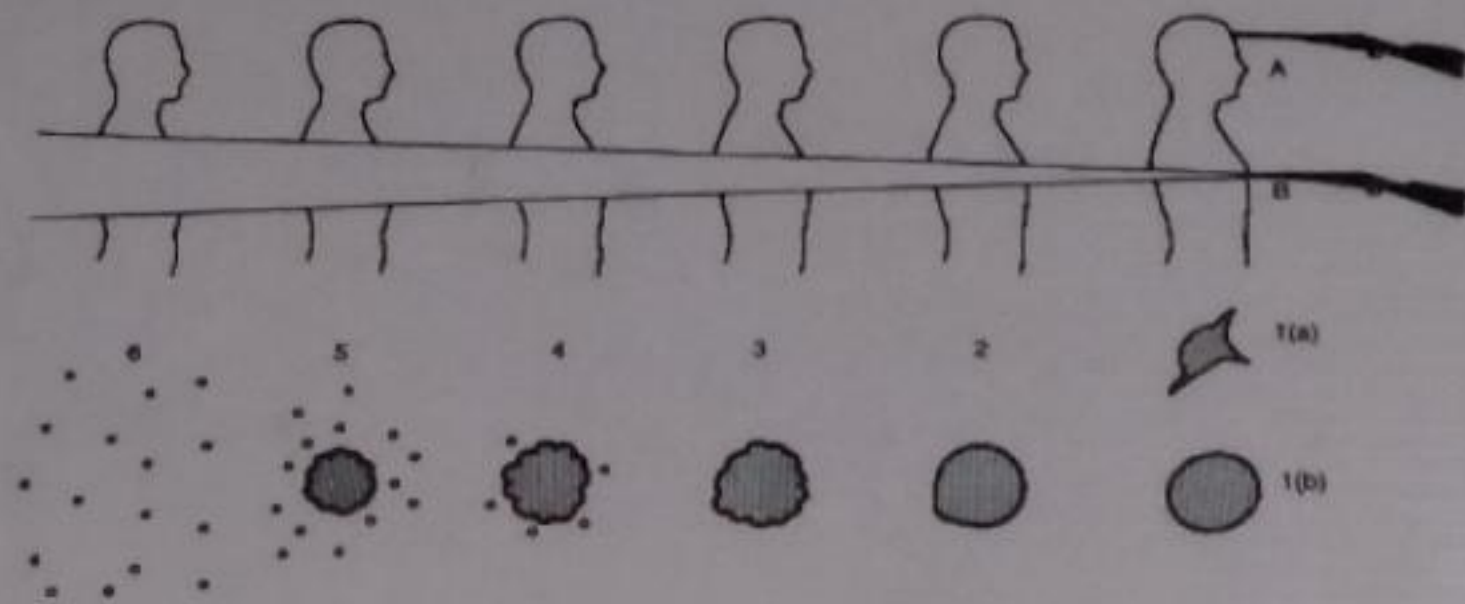


STANDARD PRECAUTIONS



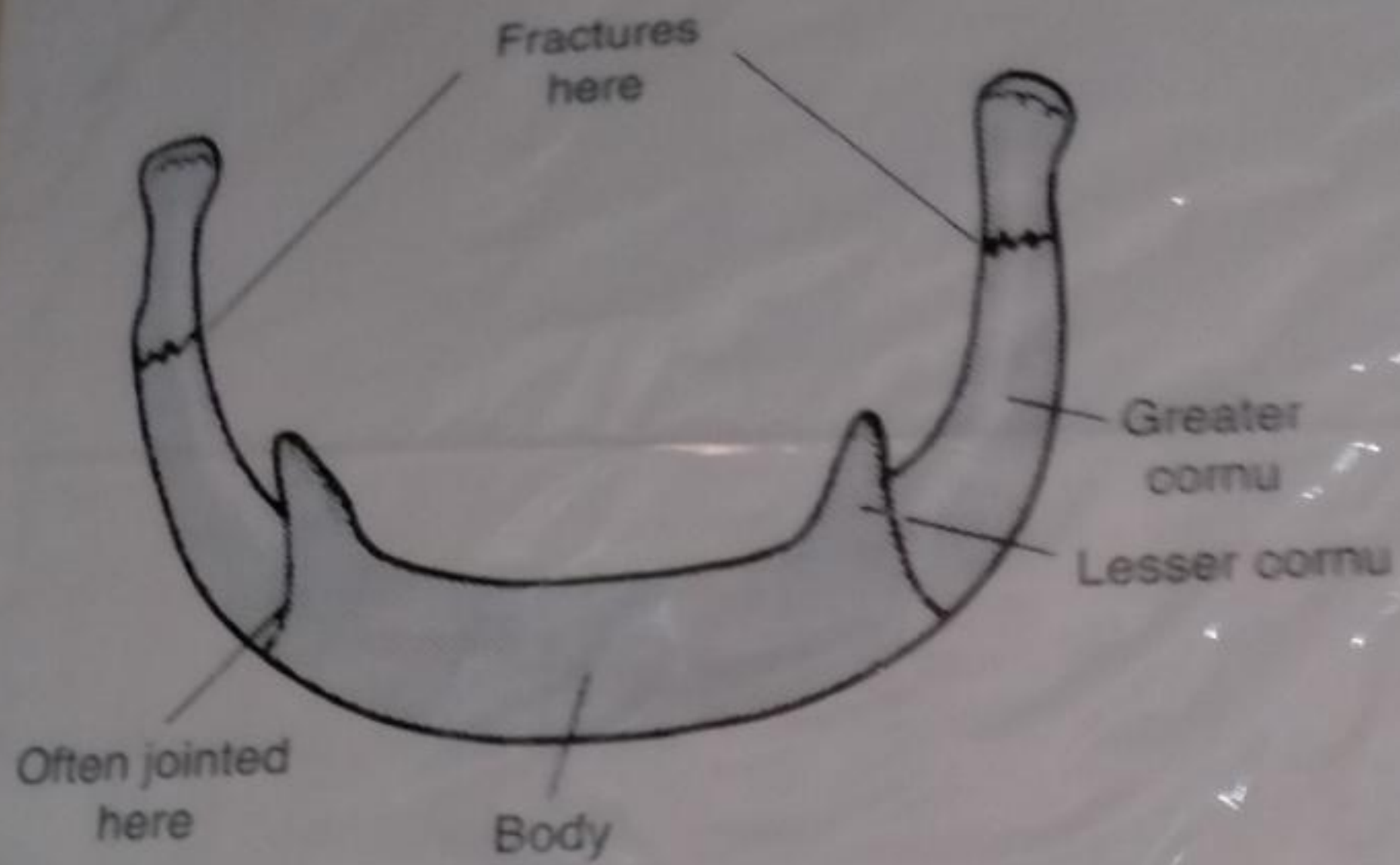
Step-6

SHOTGUN FIRE AT VARIOUS DISTANCES



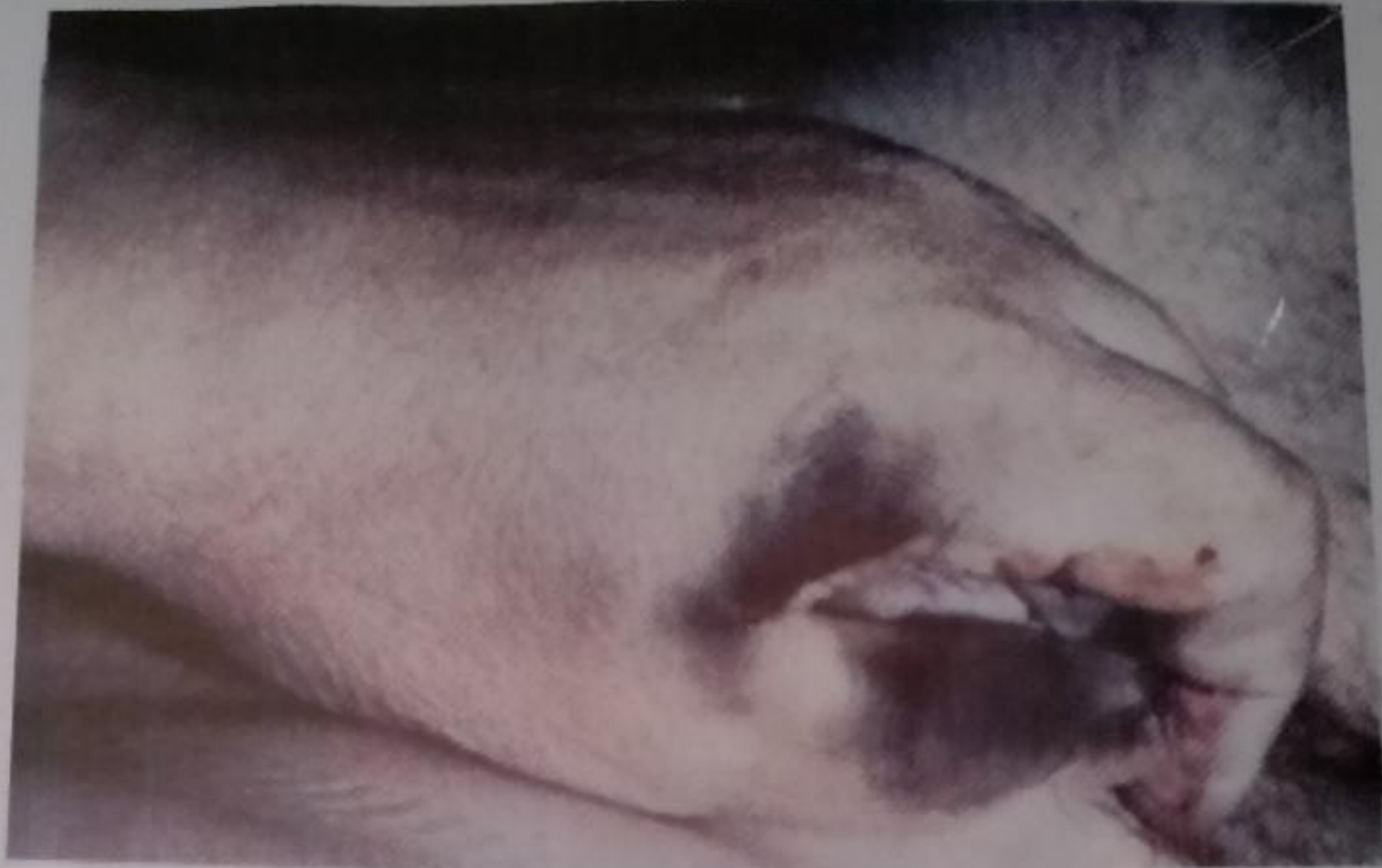Department of
Forensic Medicine & Toxicology
Azra Naheed Medical College

HYOID BONE



Department of
Forensic Medicine & Toxicology
Azra Naheed Medical College

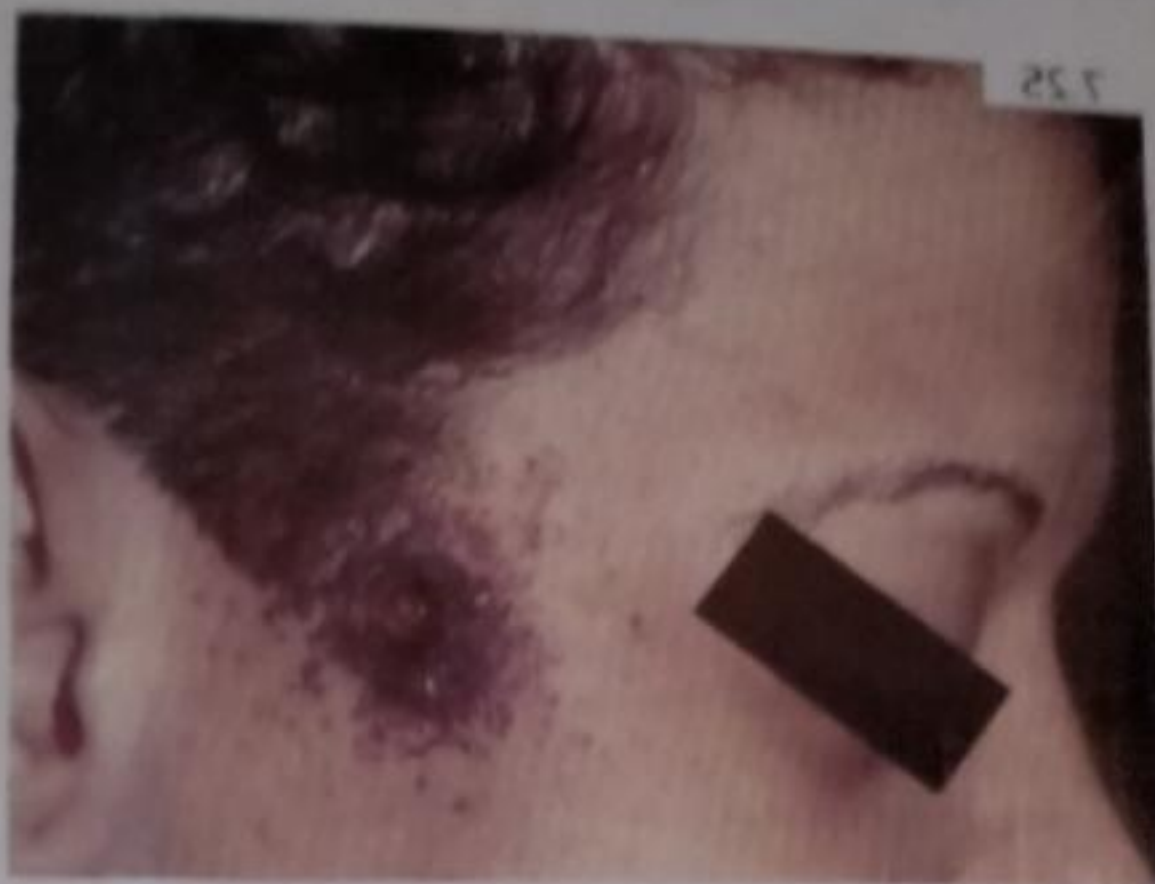BLOWBACK PHENOMENON IN SUICIDAL FIRE



Department of
Forensic Medicine & Toxicology
Azra Naheed Medical College

C BAG

RIFLED FIREARM ENTRY WOUND
ON TEMPLE



Department of
Forensic Medicine & Toxicology
Azra Naheed Medical College

Toxicology
College

SUICIDE BY PLASTIC BAG



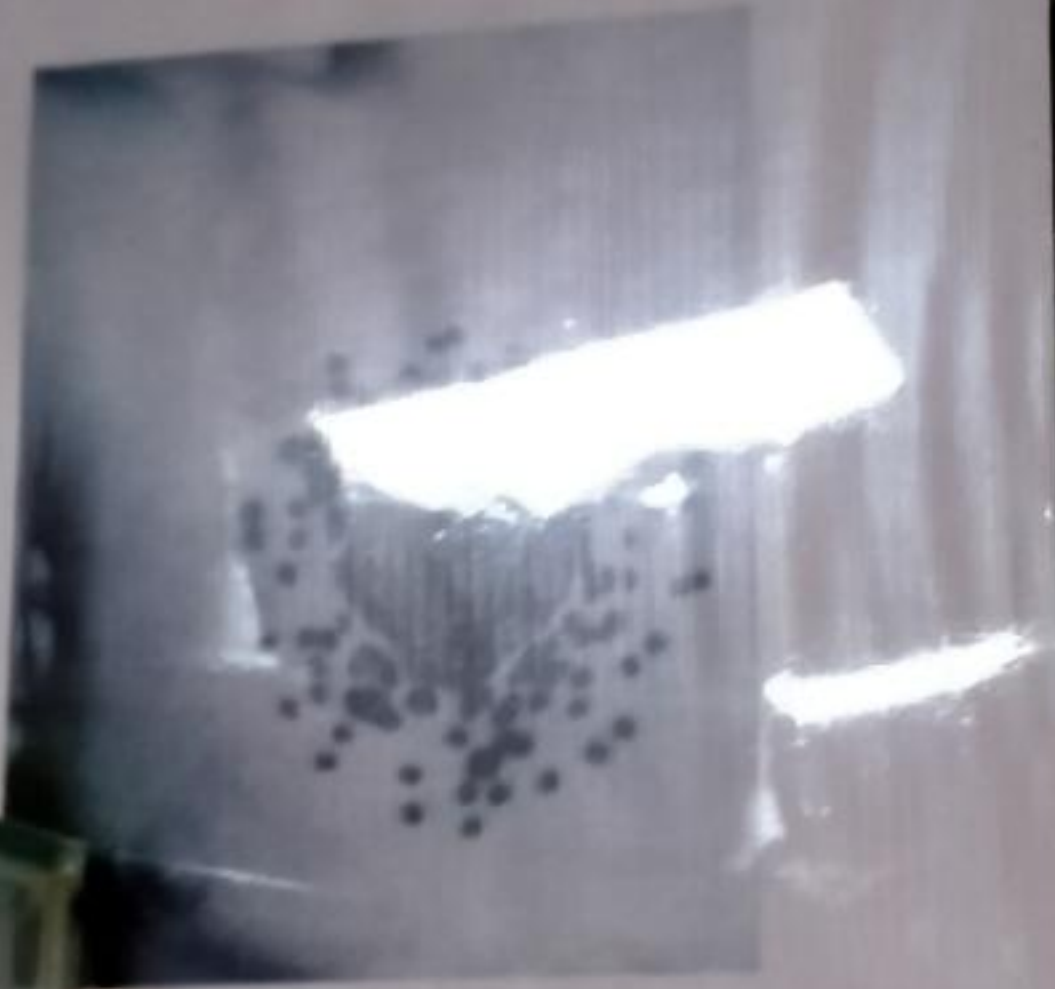Department of
Forensic Medicine & Toxicology
Azra Naheed Medical College

RIFLED FIREARMS
ON



AZRA NAHEED MEDICAL COLLEGE

SHOTGUN FIRE ON CHEST
AT ABOUT 5 FEET DISTANCE



Department of
Forensic Medicine & Toxicology
Azra Naheed Medical College

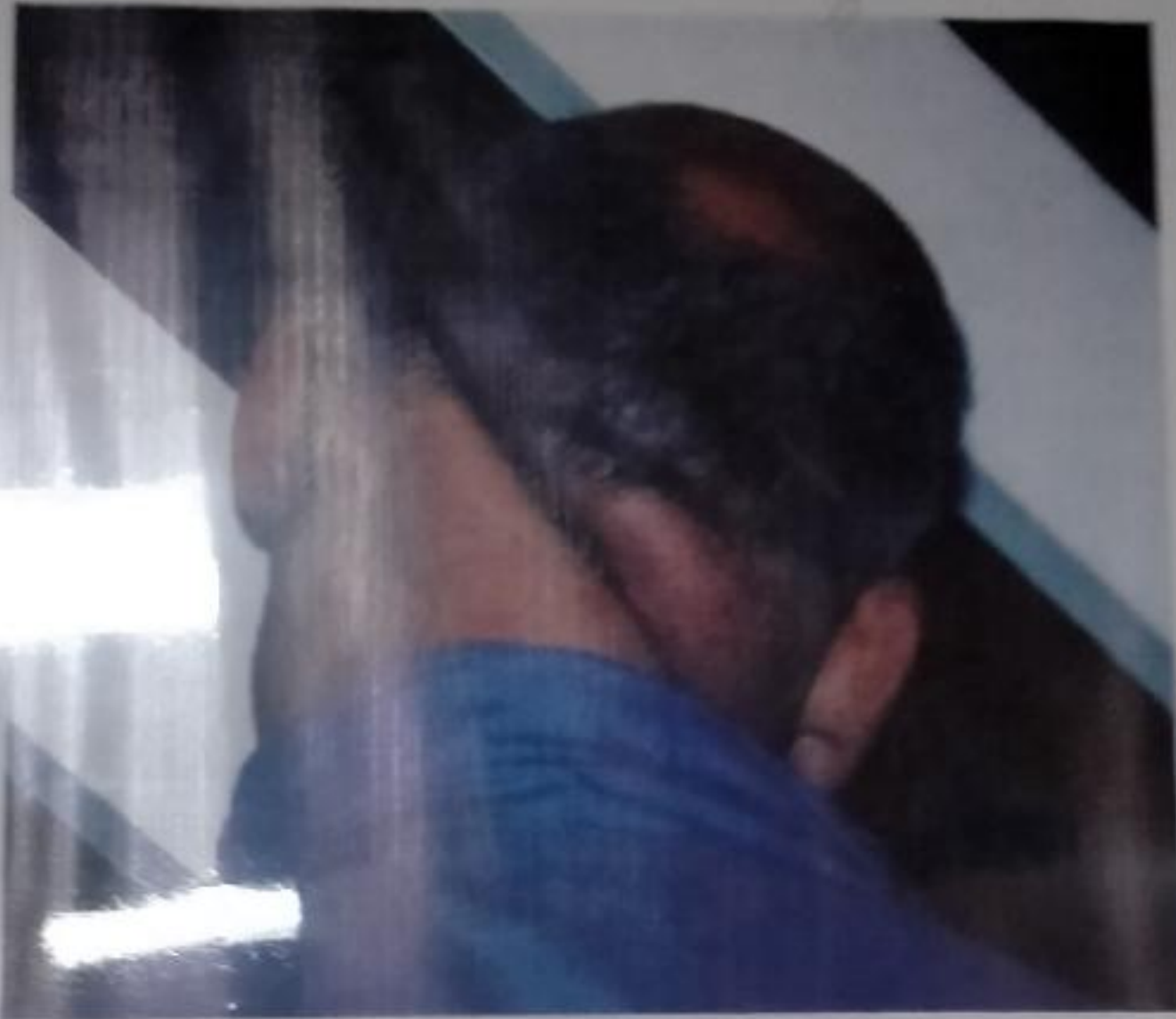

SUICIDE BY



FO
Azra

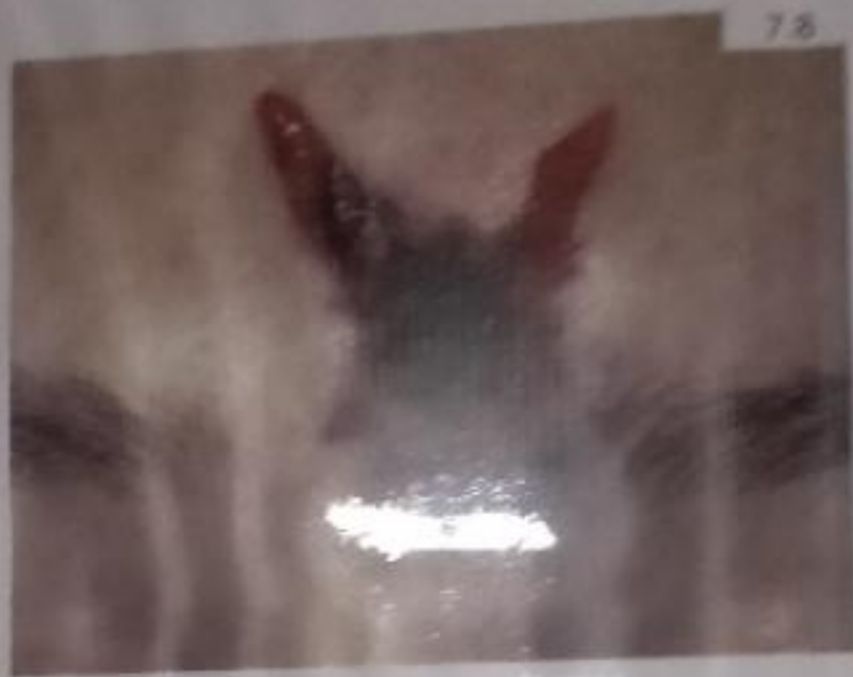HANGING



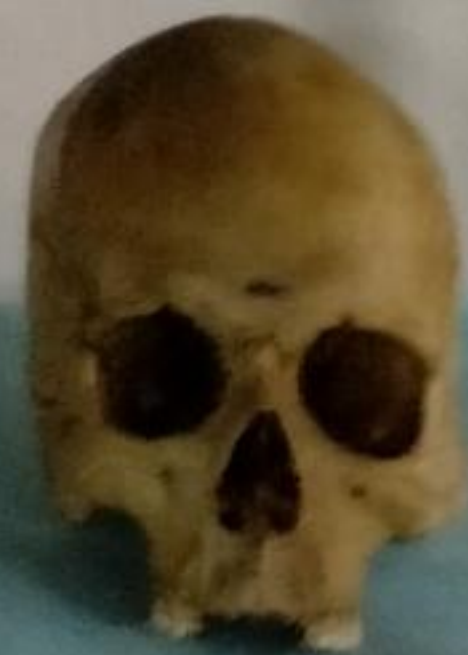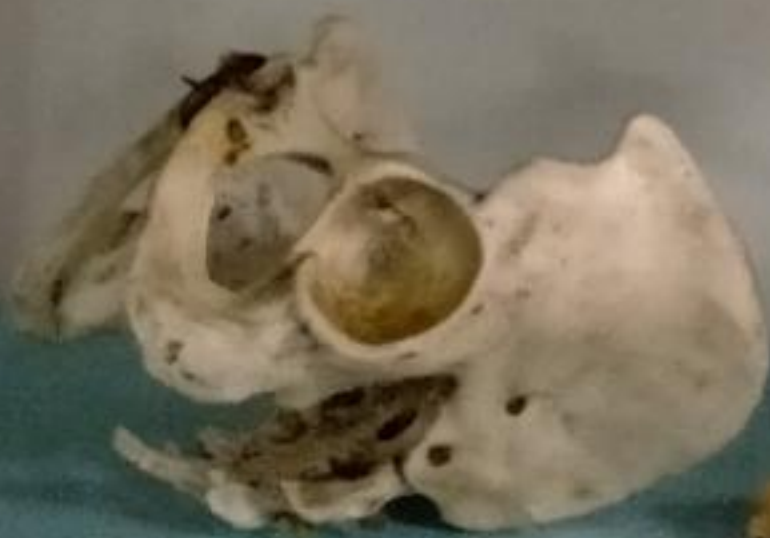Department of
Forensic Medicine & Toxicology
Azra Naheed Medical College



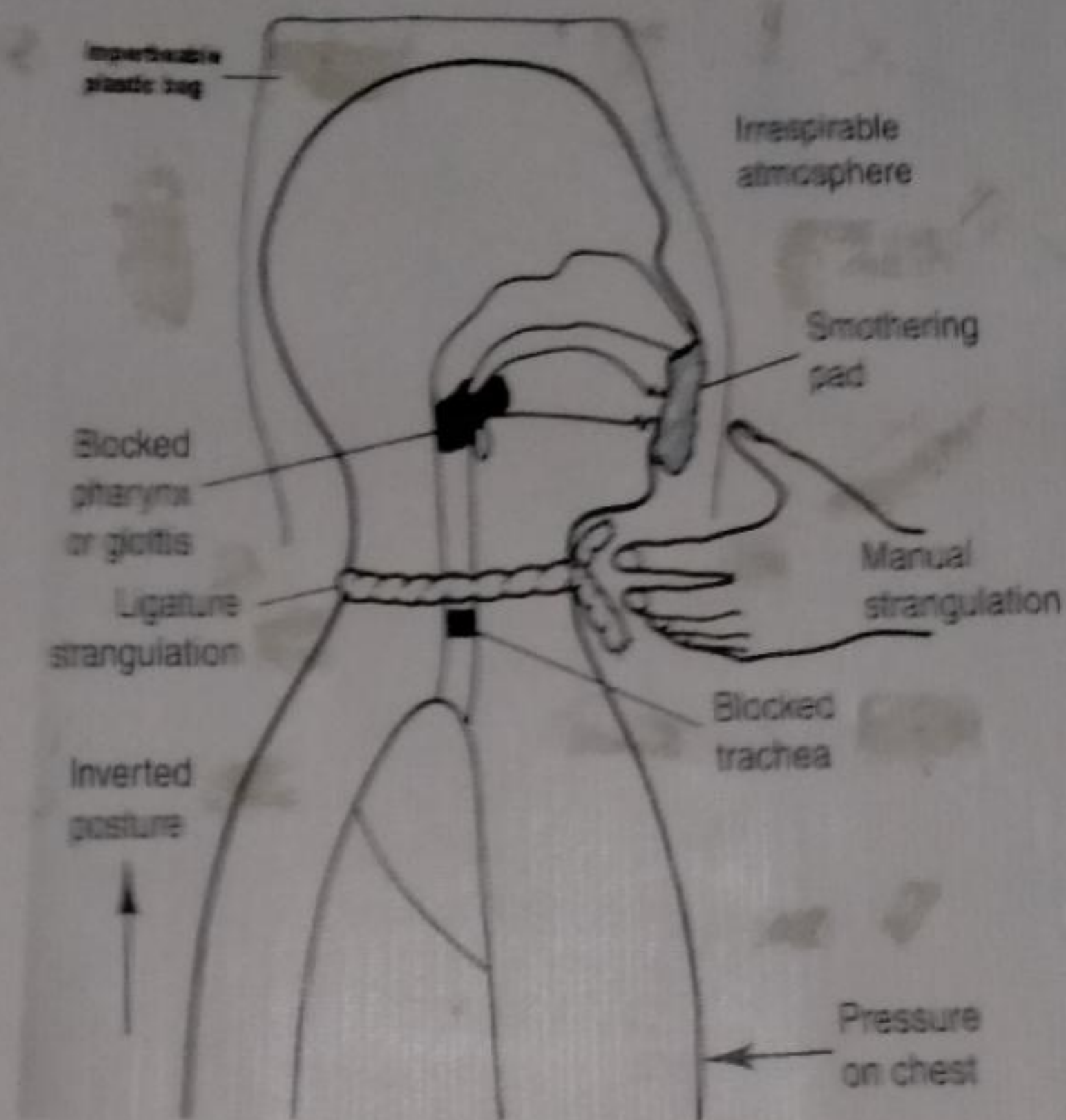
CONTACT FIRE ON FOREHEAD



Department of
Forensic Medicine & Toxicology
Assiut Medical College



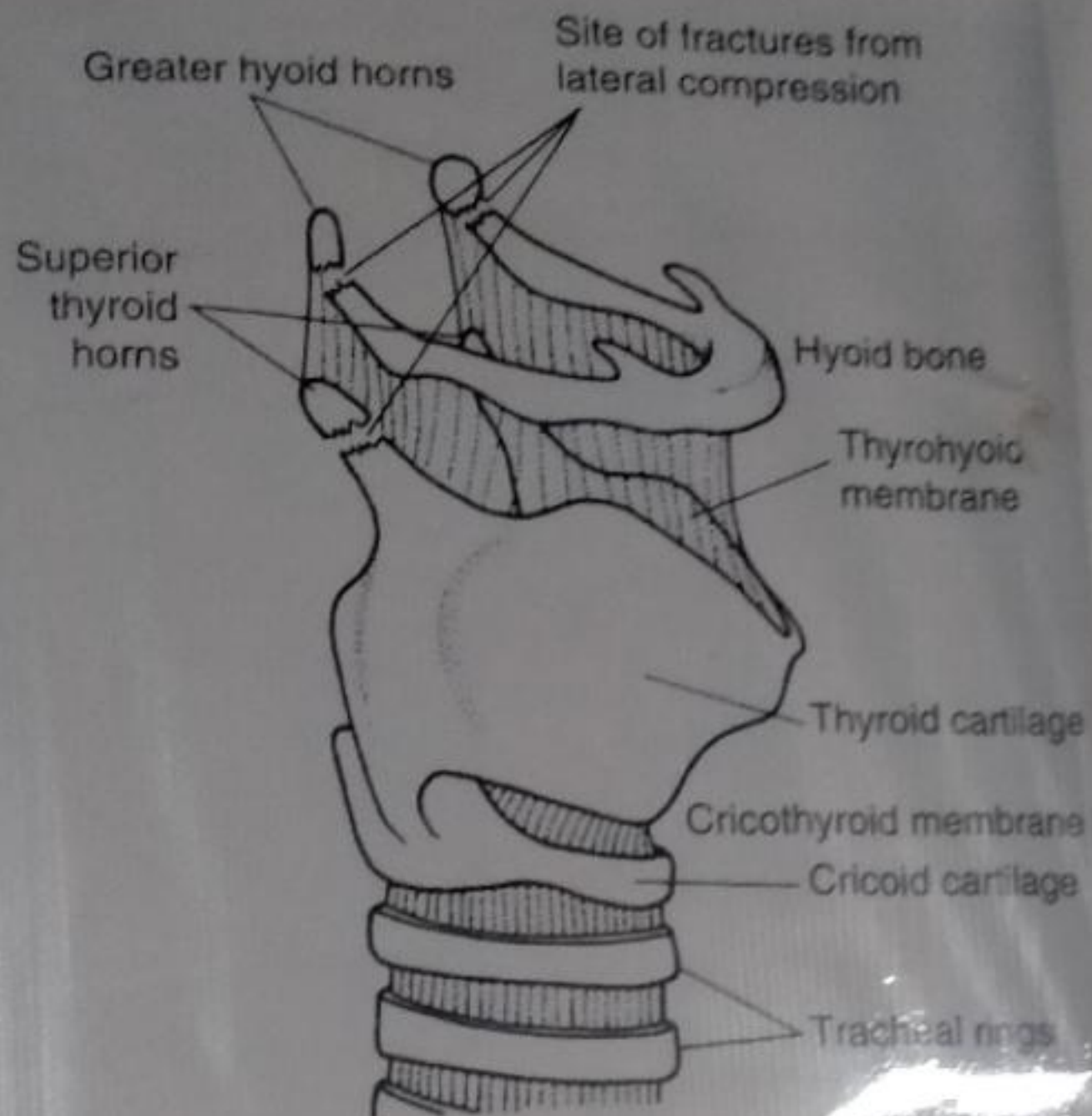
LEVELS OF MECHANICAL ASPHYXIA



Department of
Forensic Medicine & Toxicology
Azra Naheed Medical College

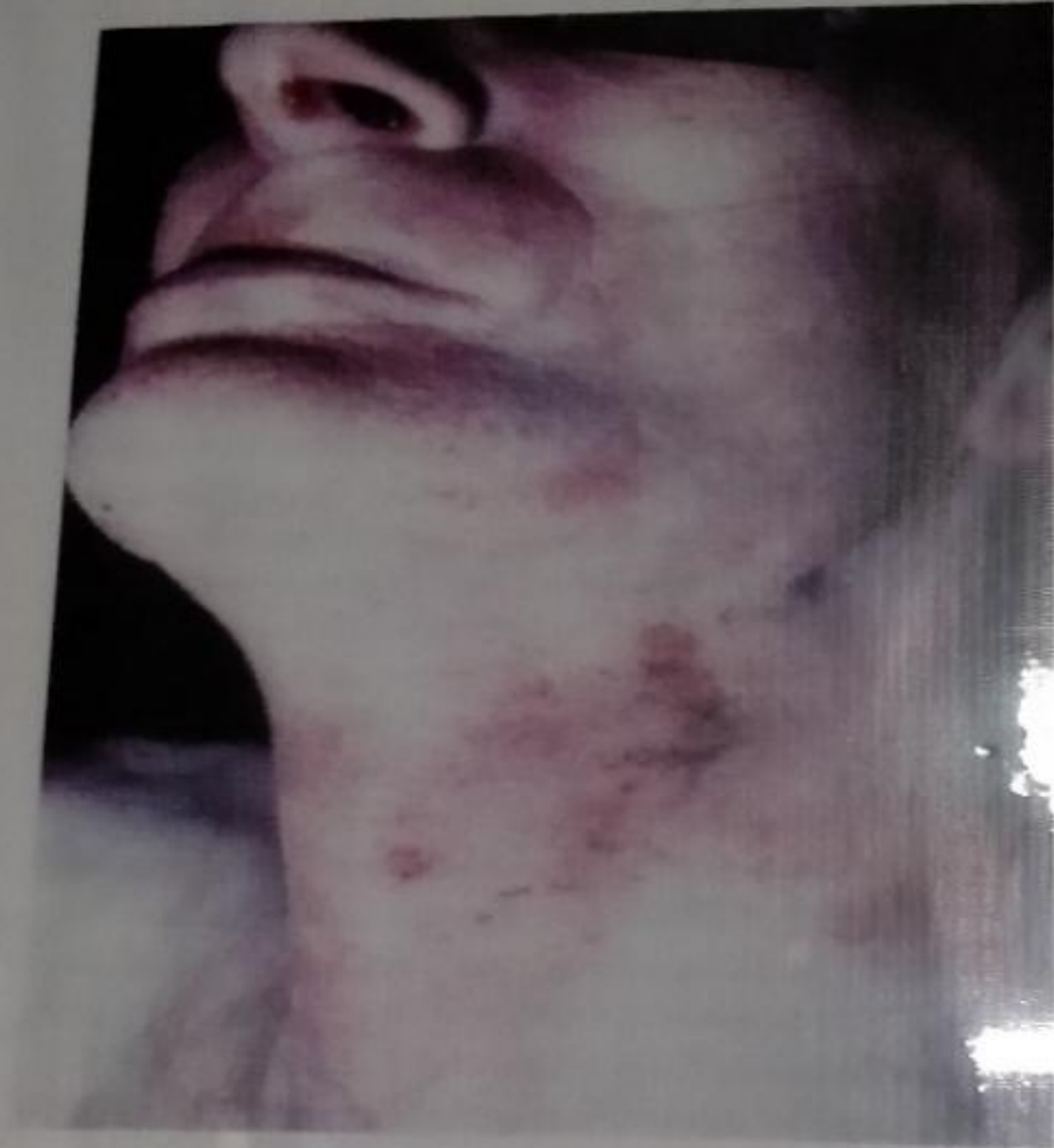

NECK STRUCTURES COMMONLY DAMAGED IN THROTTLING

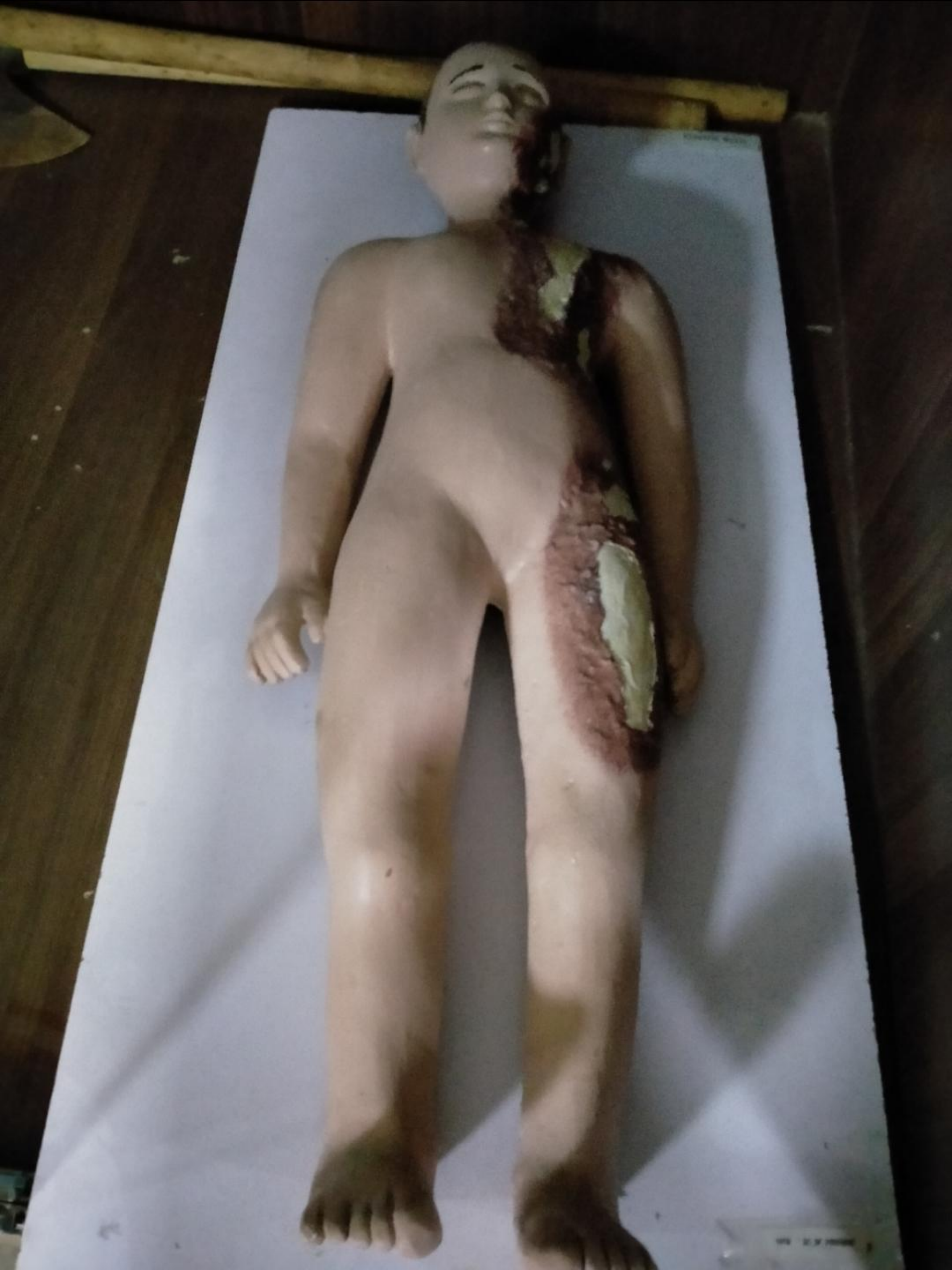

Department of
Forensic Medicine & Toxicology
Azra Naheed Medical College

CASE OF THROTLING SHOWING
ABRASIONS AND BRUISES

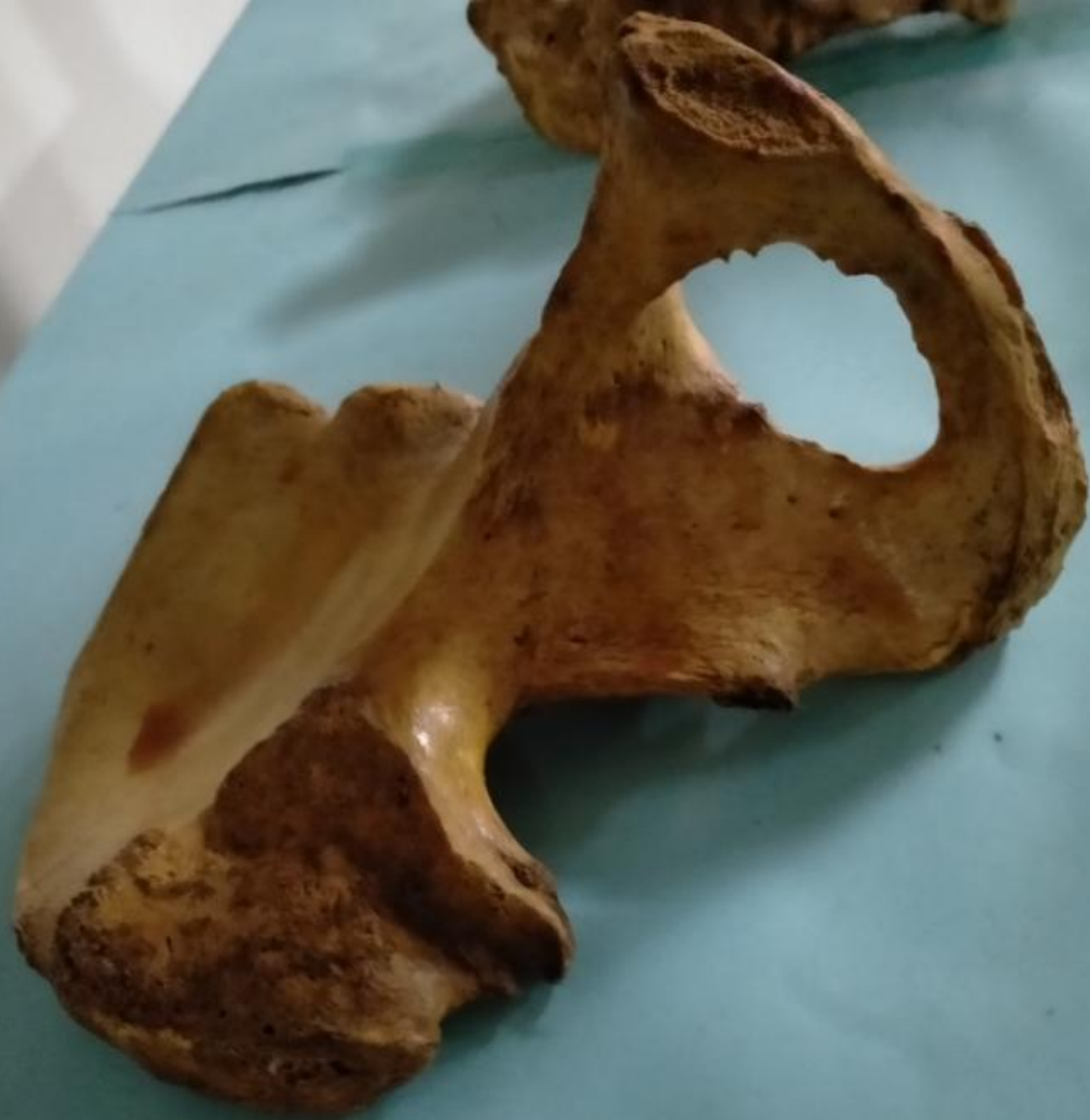

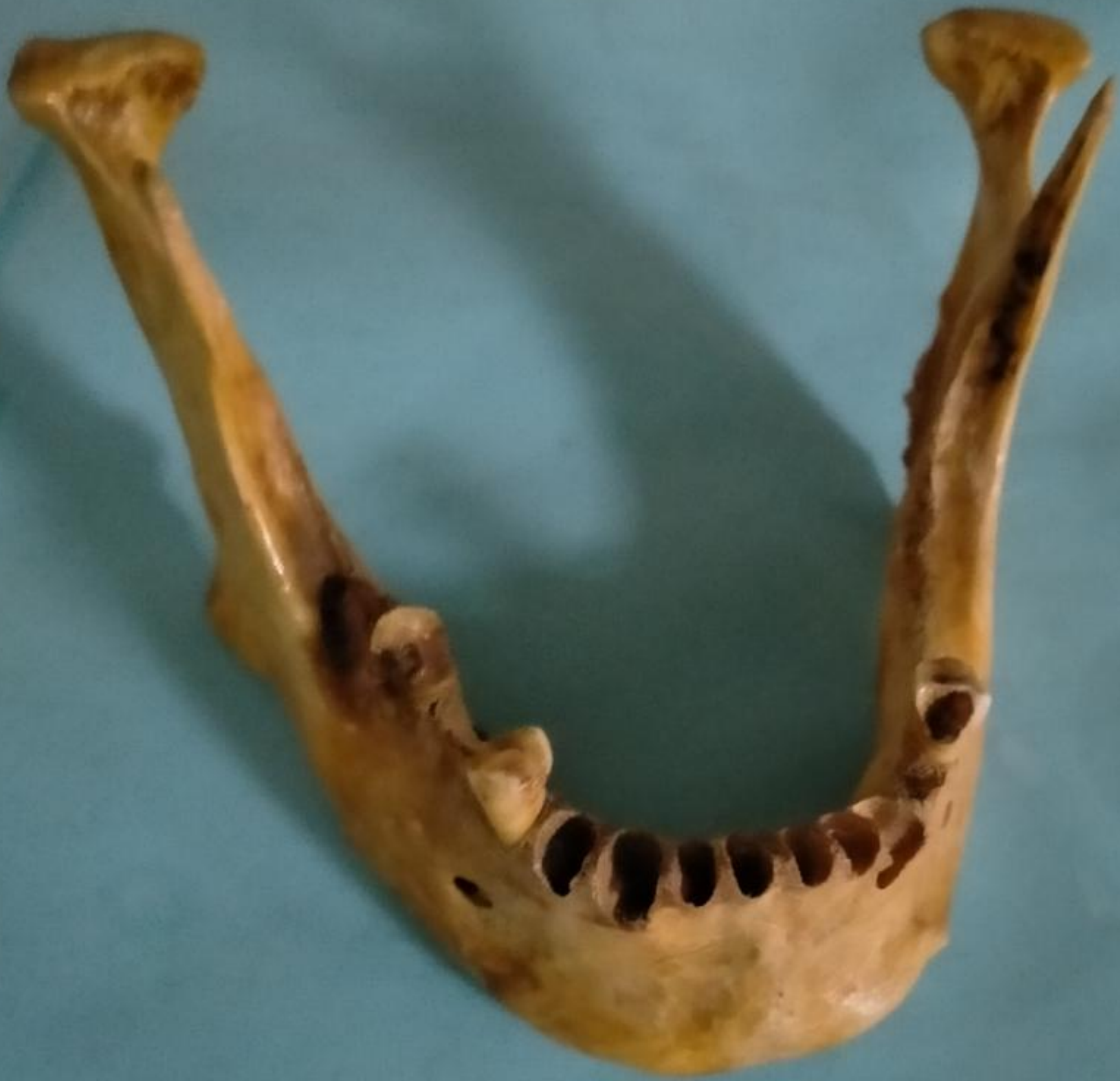Department of
Forensic Medicine & Toxicology
Azra Naheed Medical College



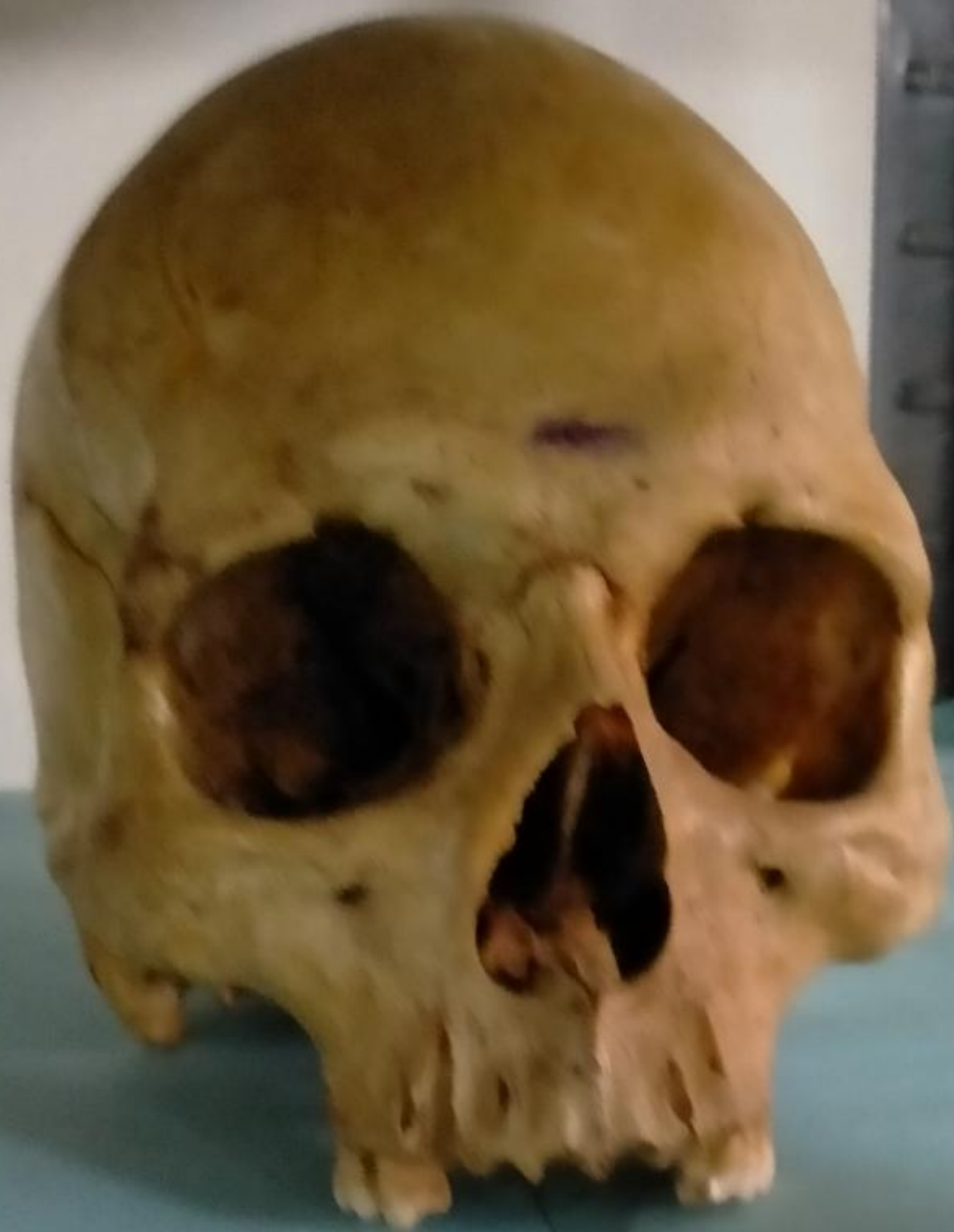




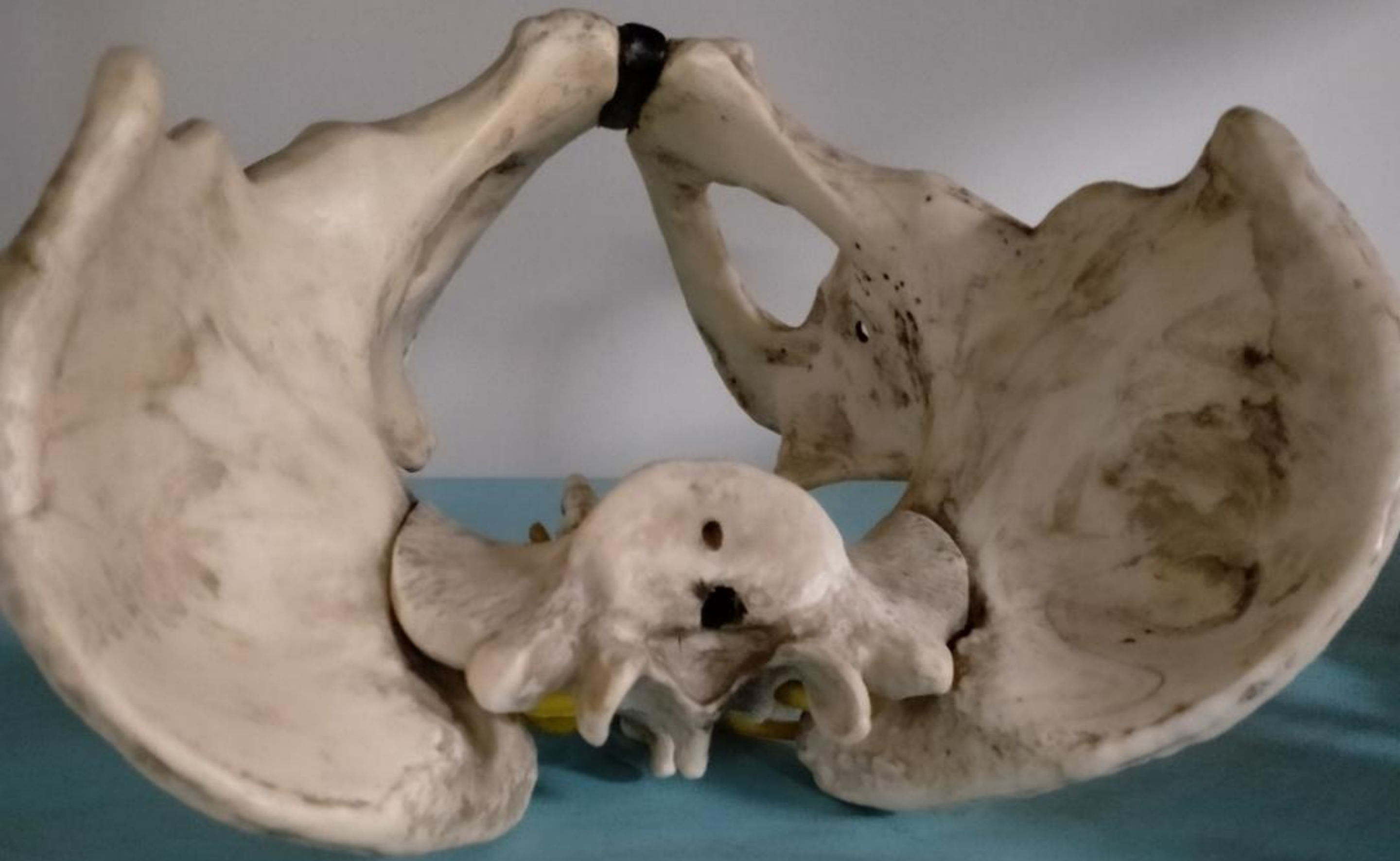


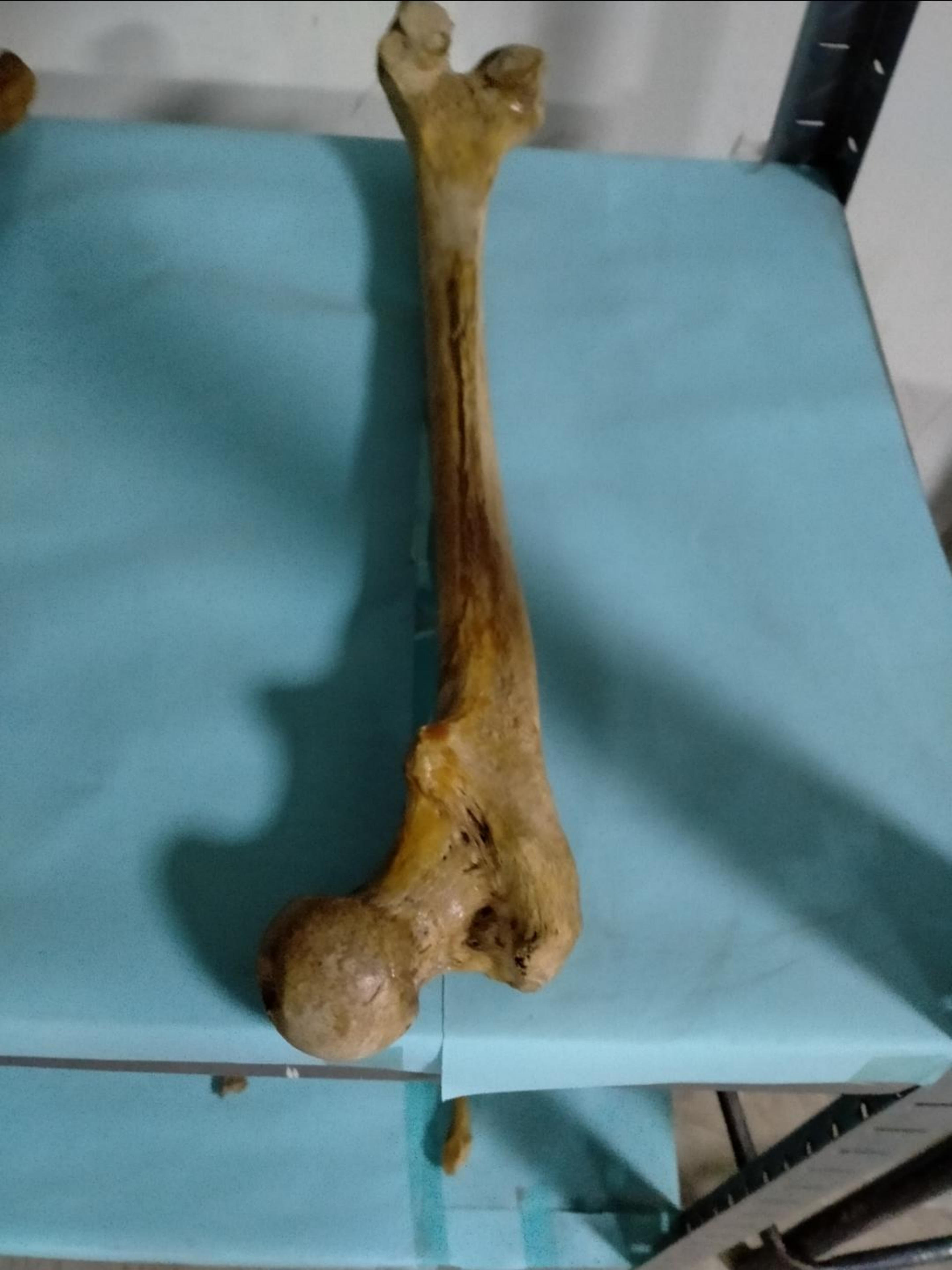



















CERATED WOUND



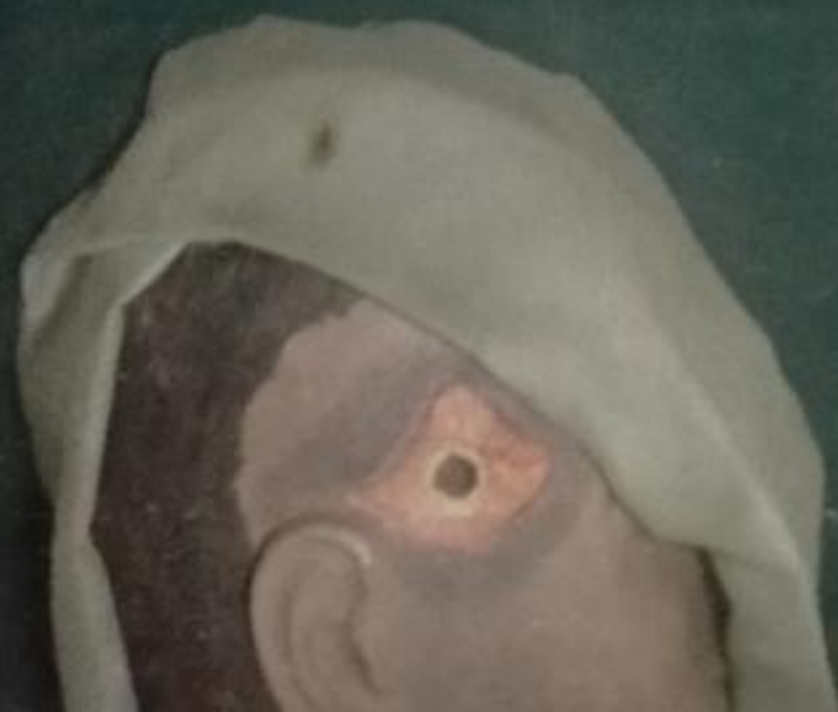144 01 01 FORENSIC



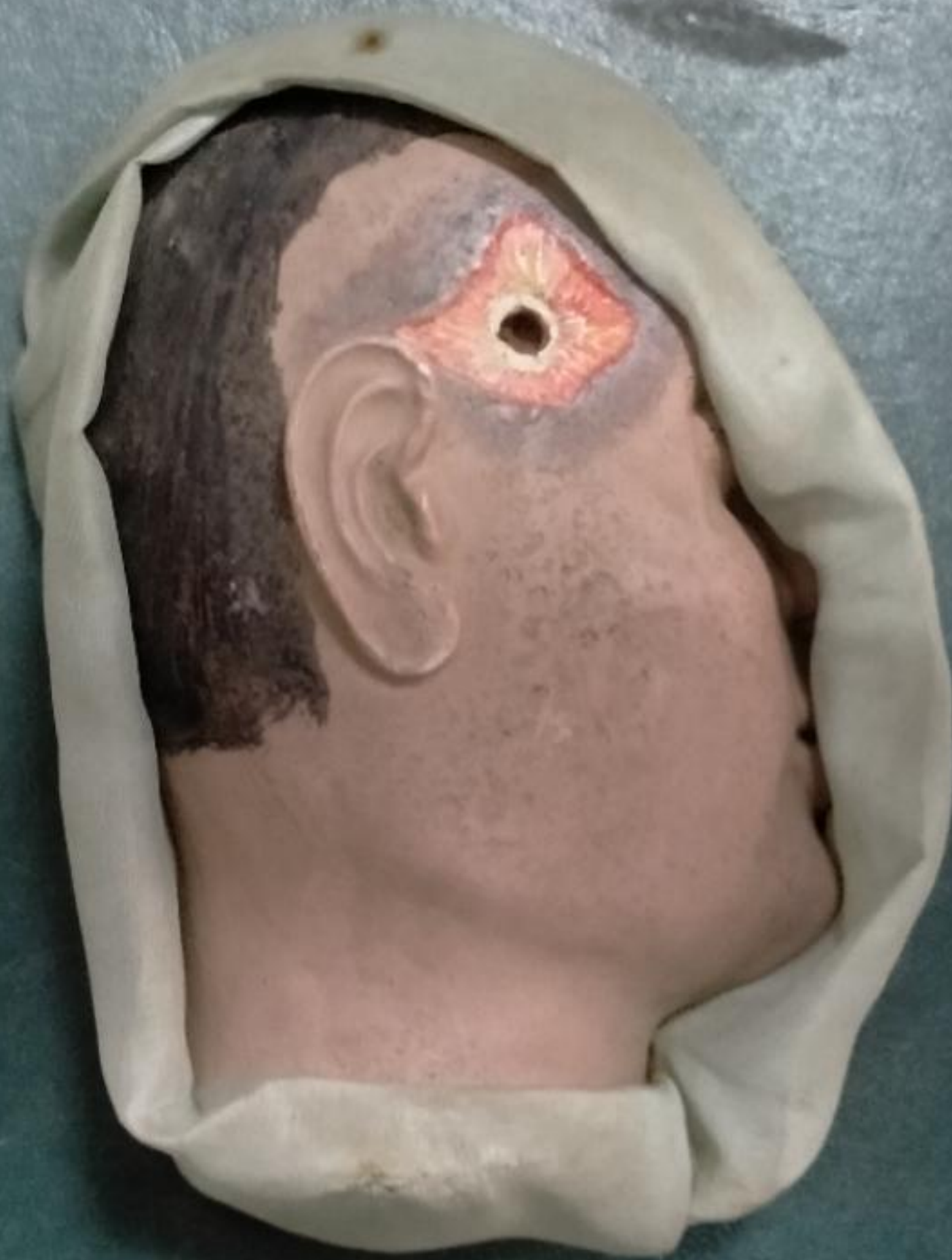1878 DC BY FOWNSIDE



THROTTLING



FIREARM ENTRY WOUND



1010 SC_SF_FORENSIC

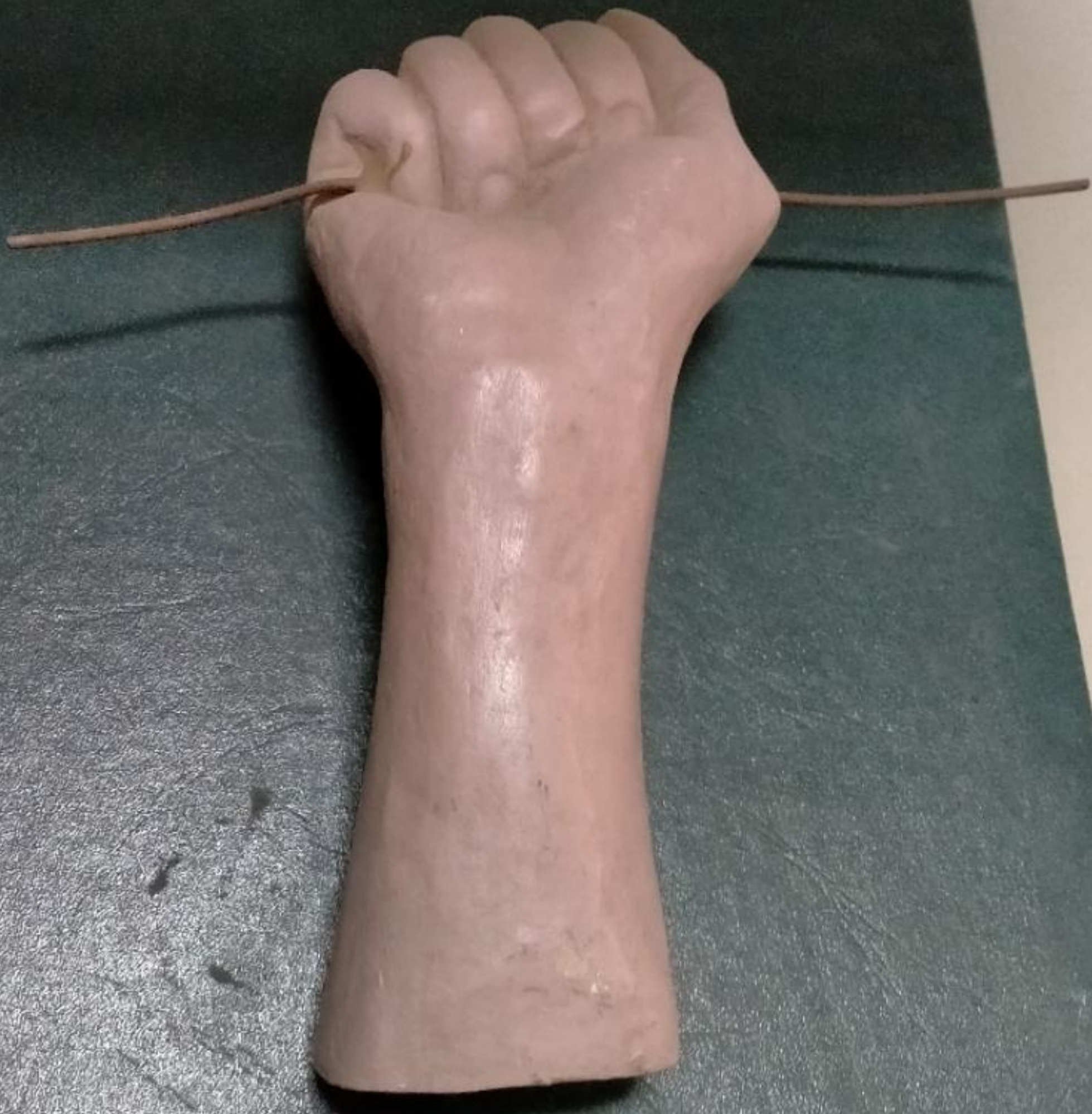ACTION

PUTREFACTION



1012 SC_SF_FORENSIC

1012 SC_SF_FORENSIC

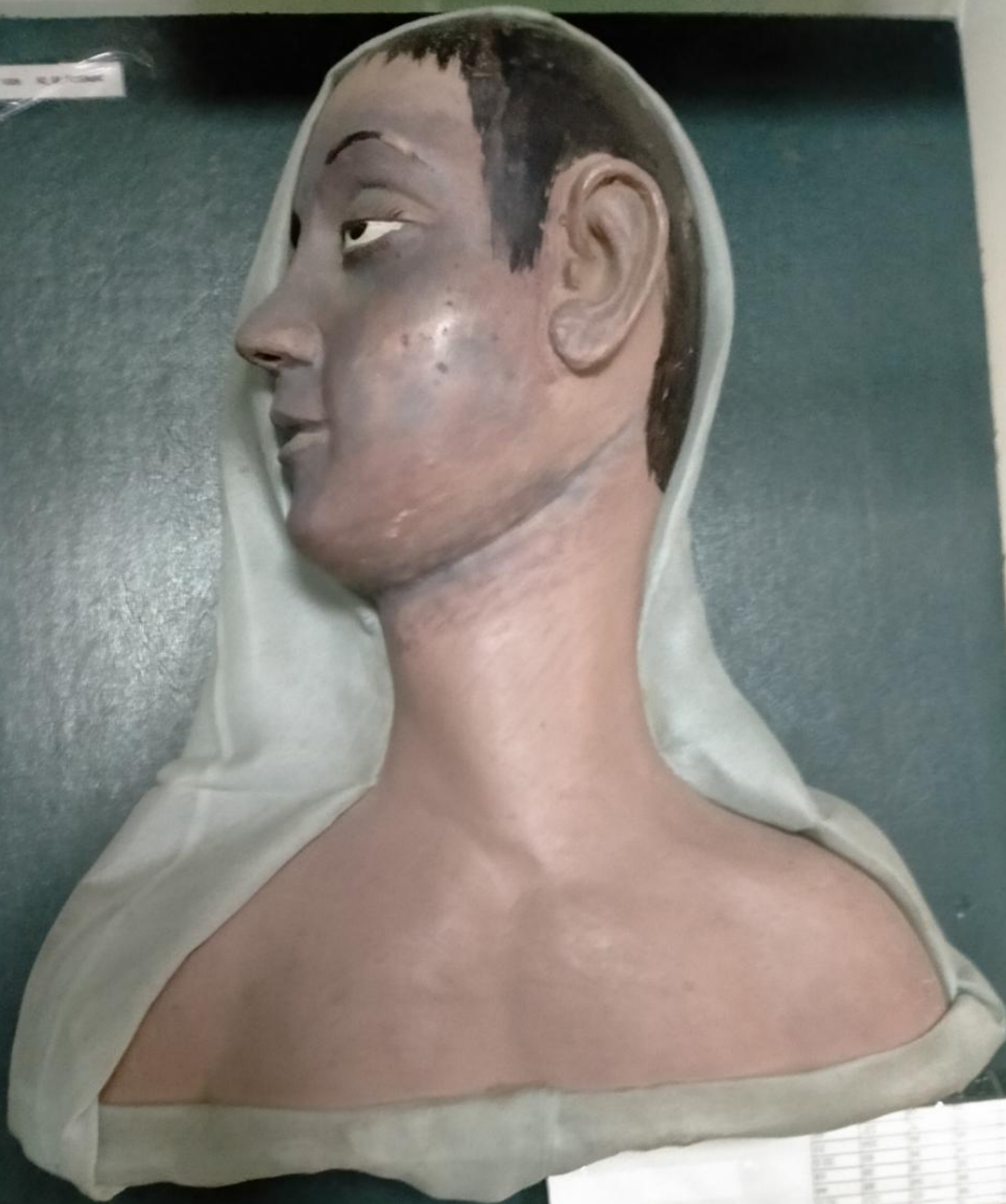

CADAVERIC SPASMI

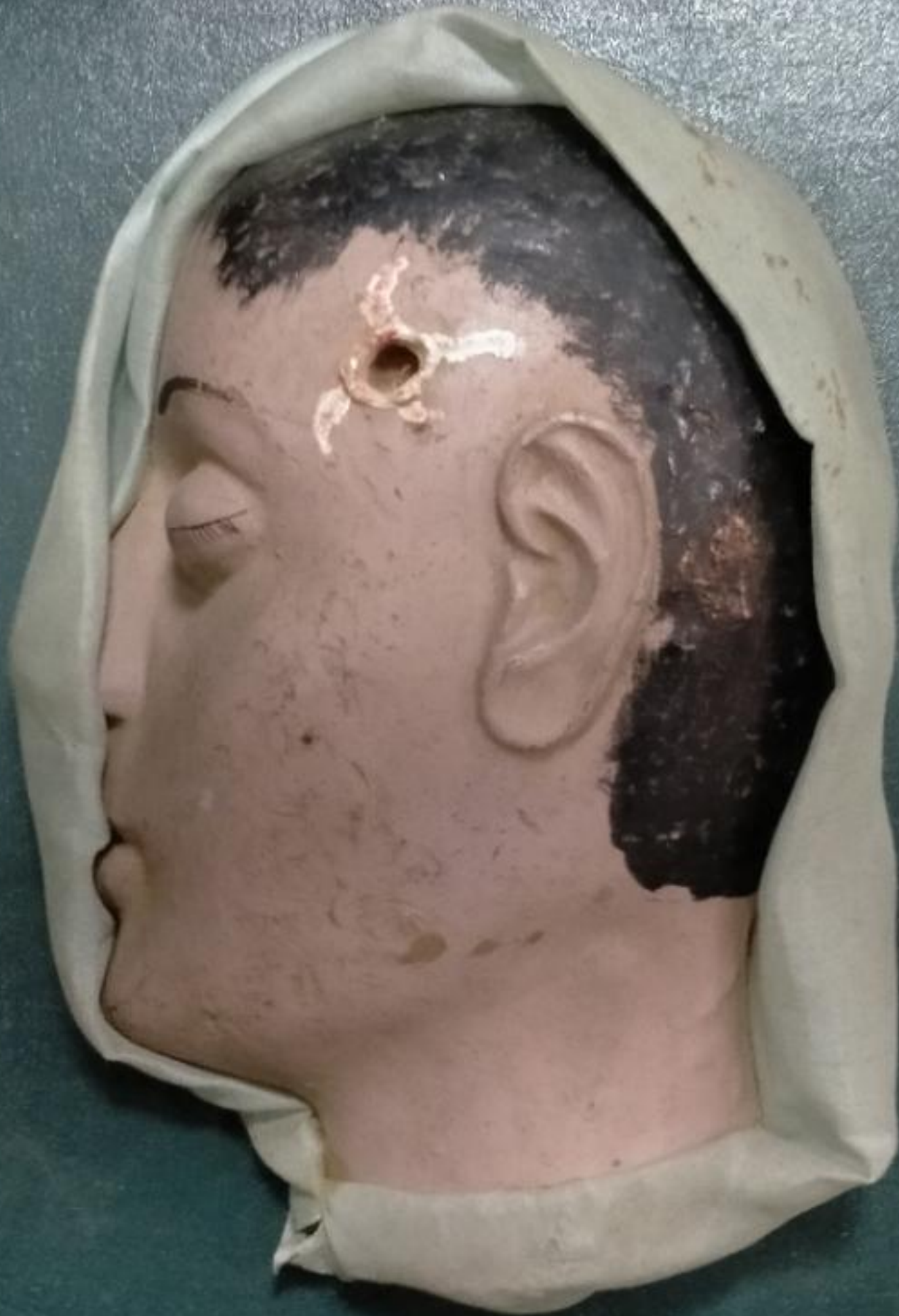1015 SC_SF_FORENSIC

MISAPPE DI VAVAOAD
MISAPPE DI VAVAOAD

100 100 1000



FIREARM EXIT WOUND

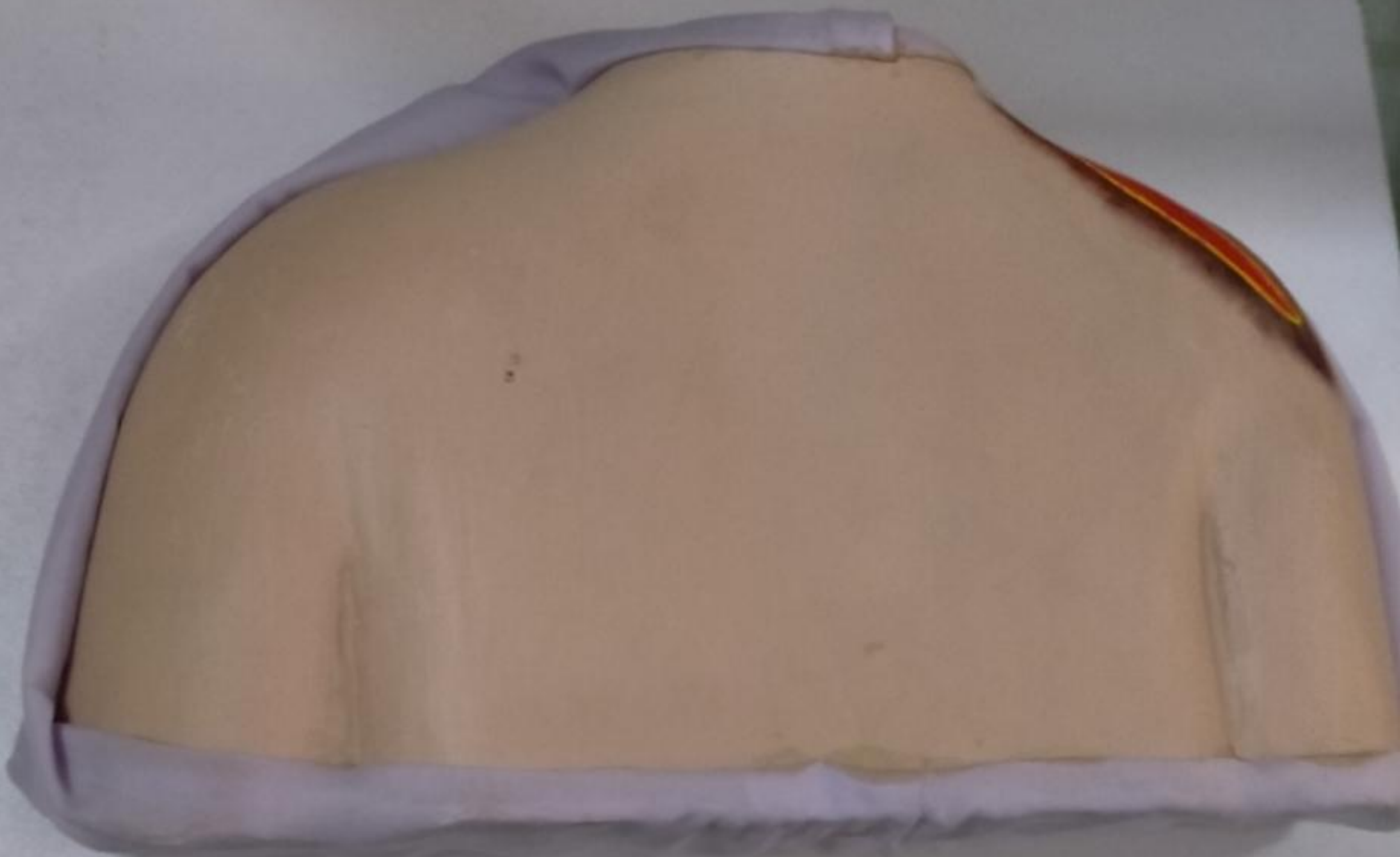

1011 SC_SF_FORENSIC

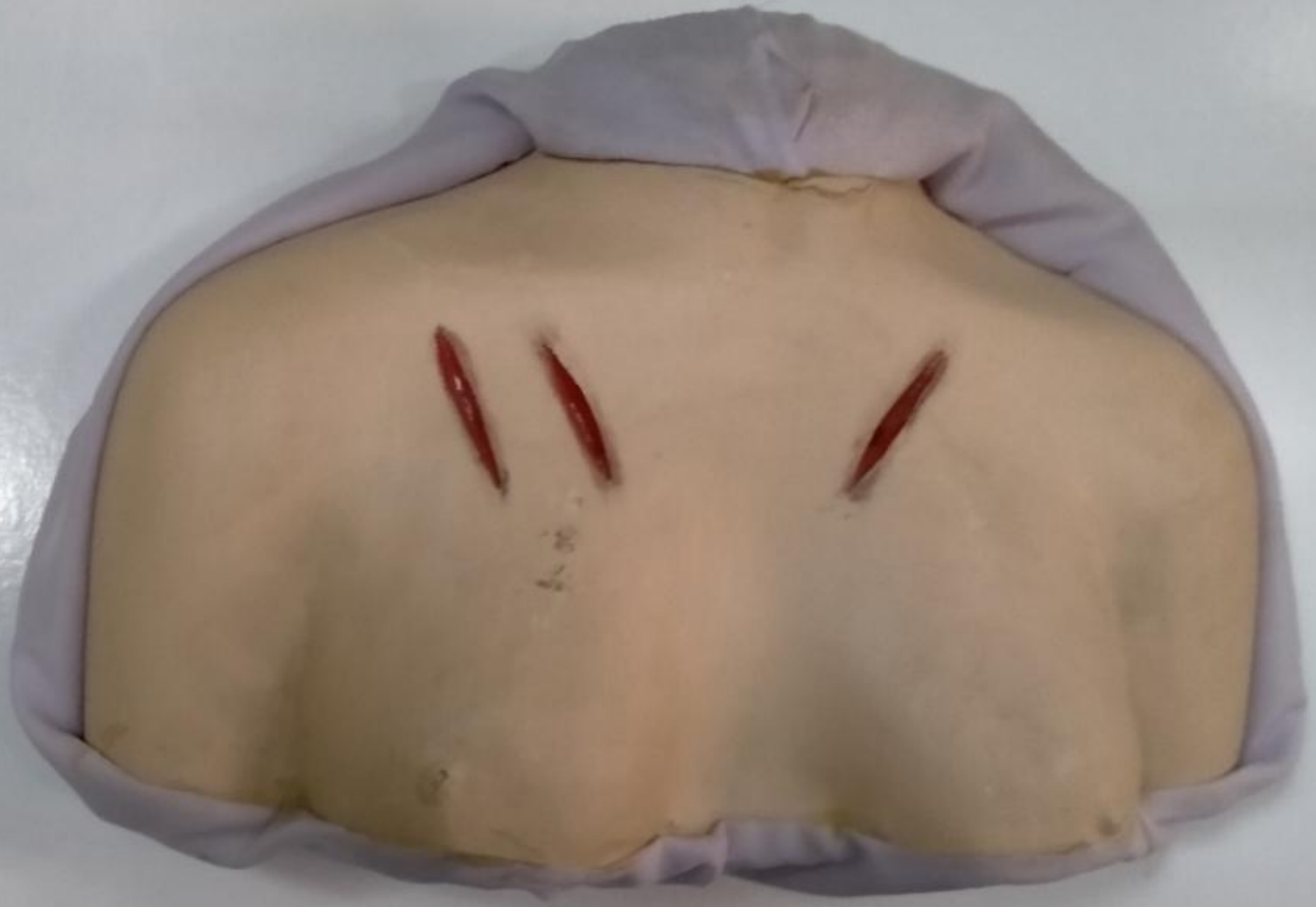STAB WOUND



HEIN 50 50 PAPER

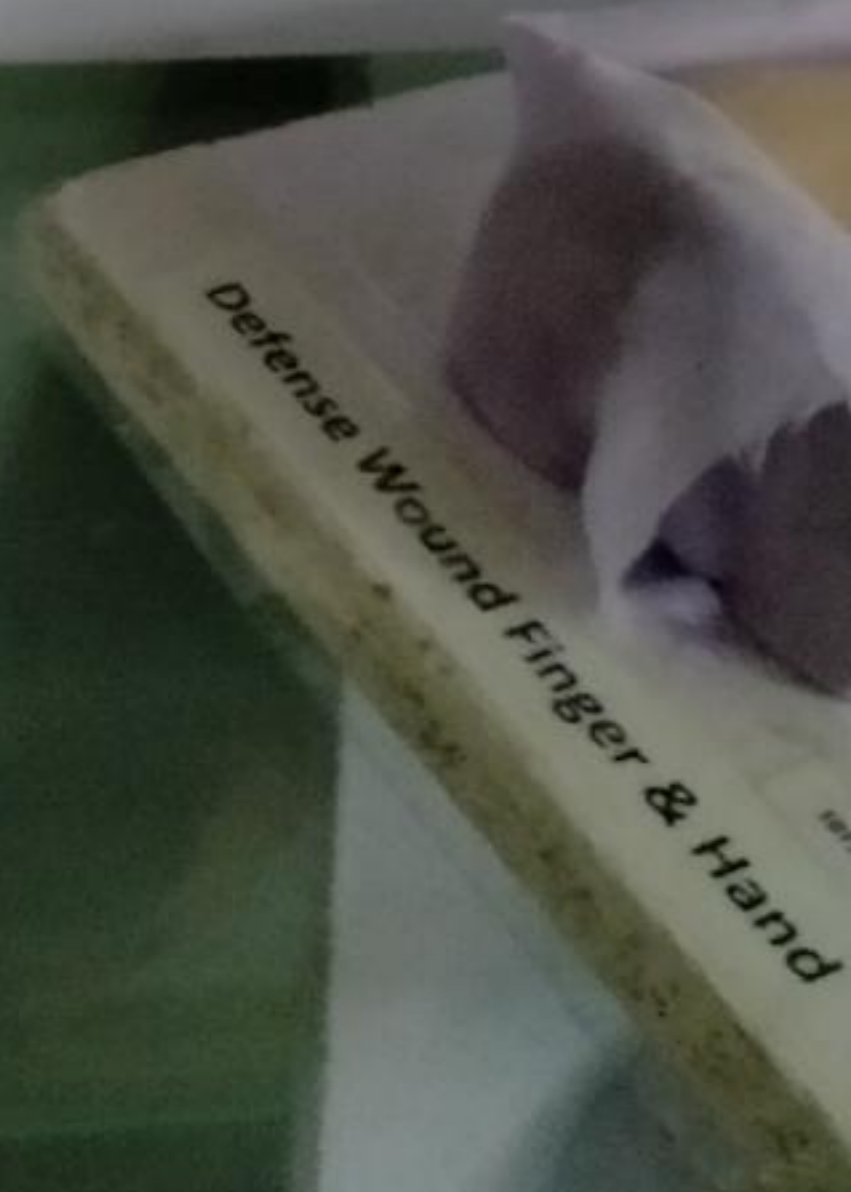

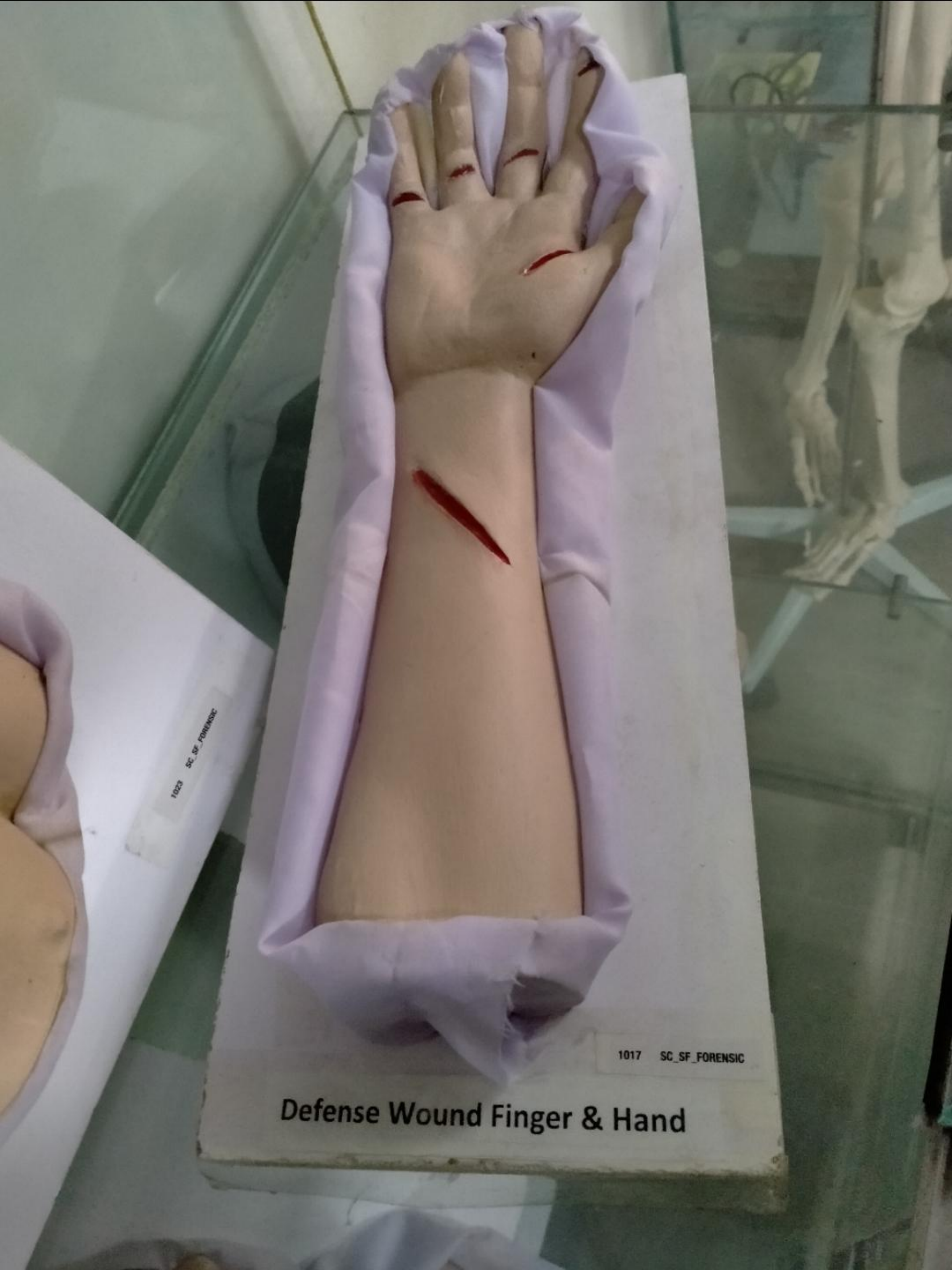Bruise on shoullder



Incised wound on chest

Abrasion on face



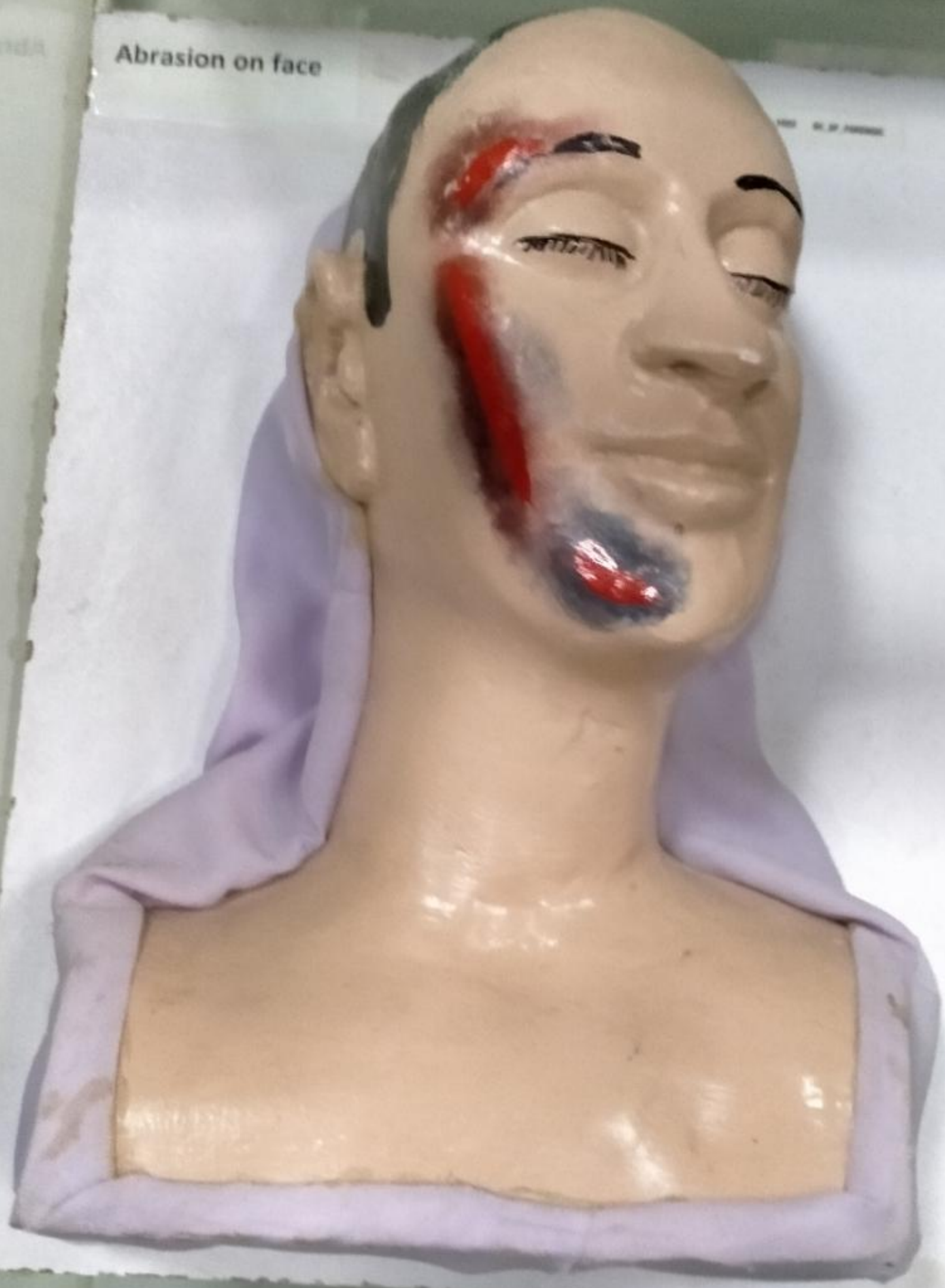

1023 SC_SF_FORENSIC

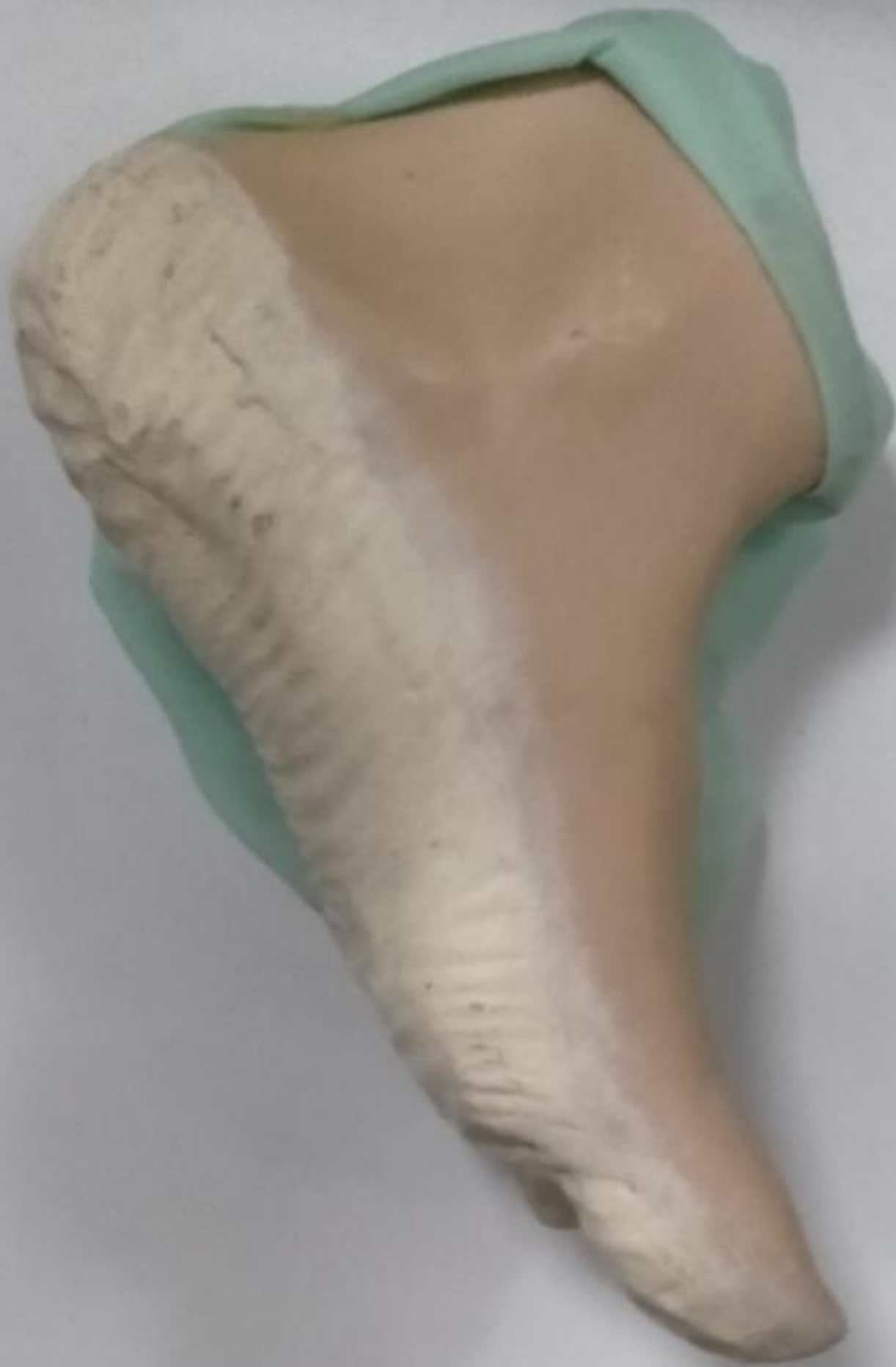1017 SC_SF_FORENSIC

Defense Wound Finger & Hand

Abrasion on face



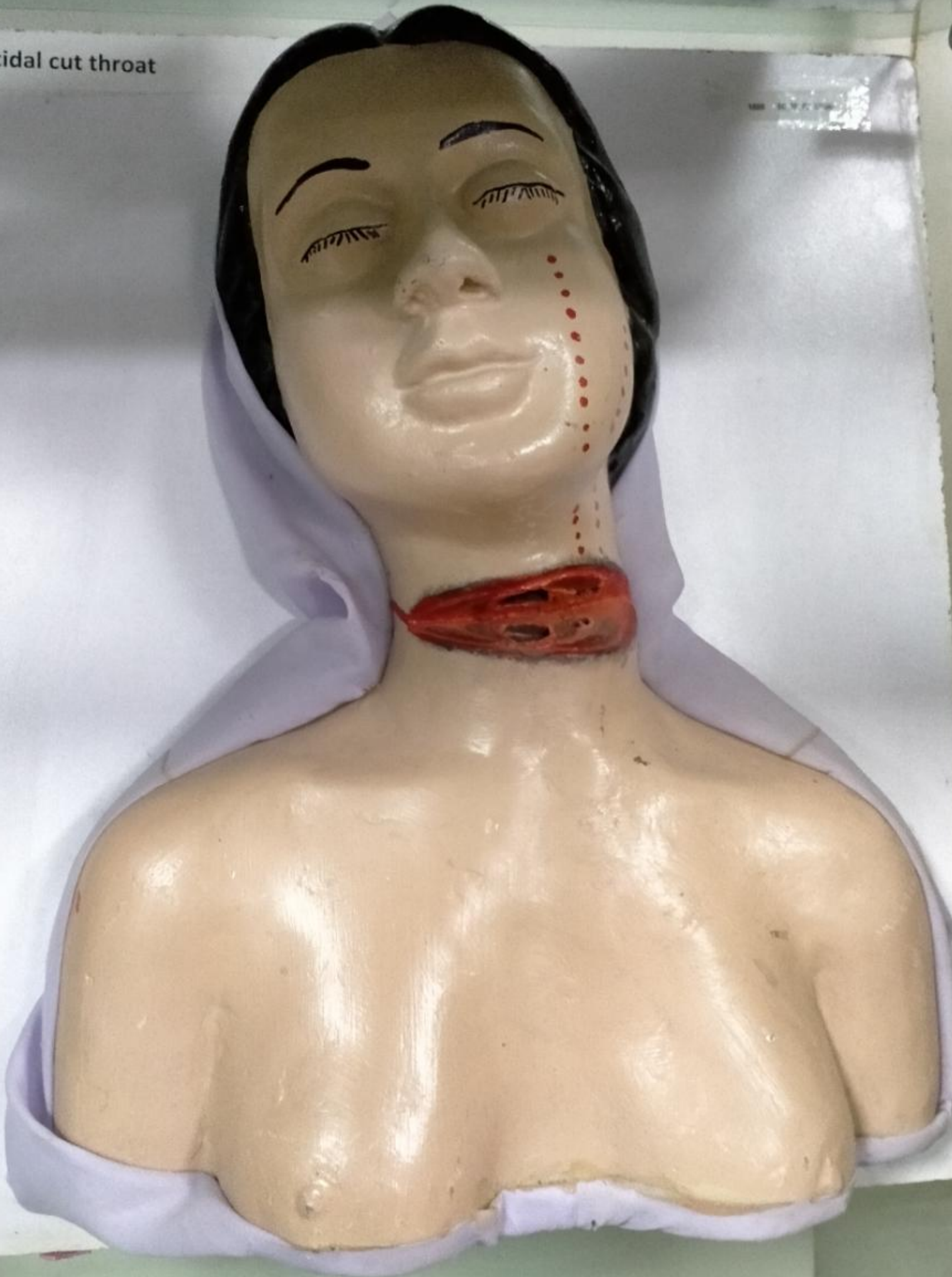Pellet Gun Shot



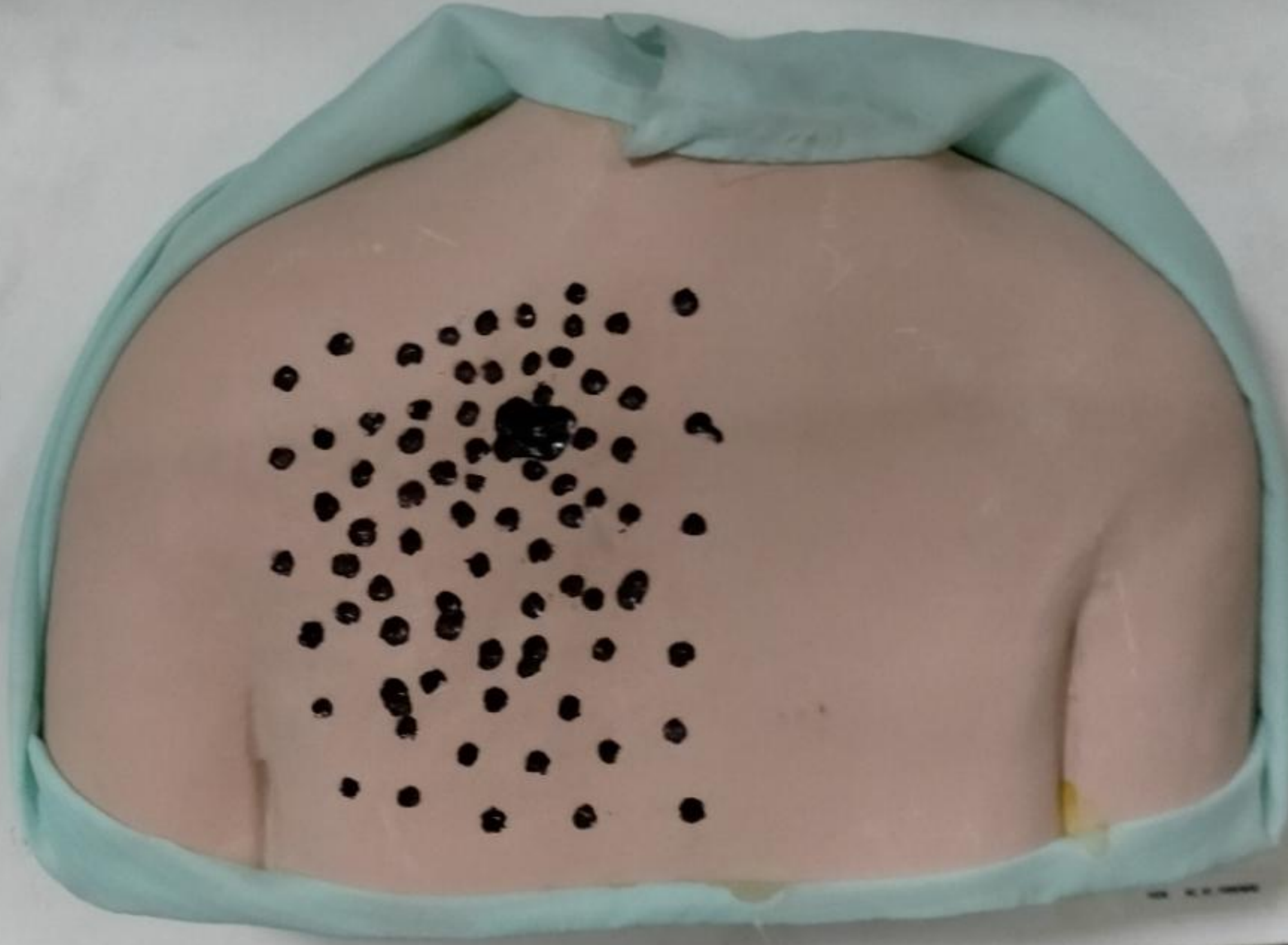
Washer man Foot

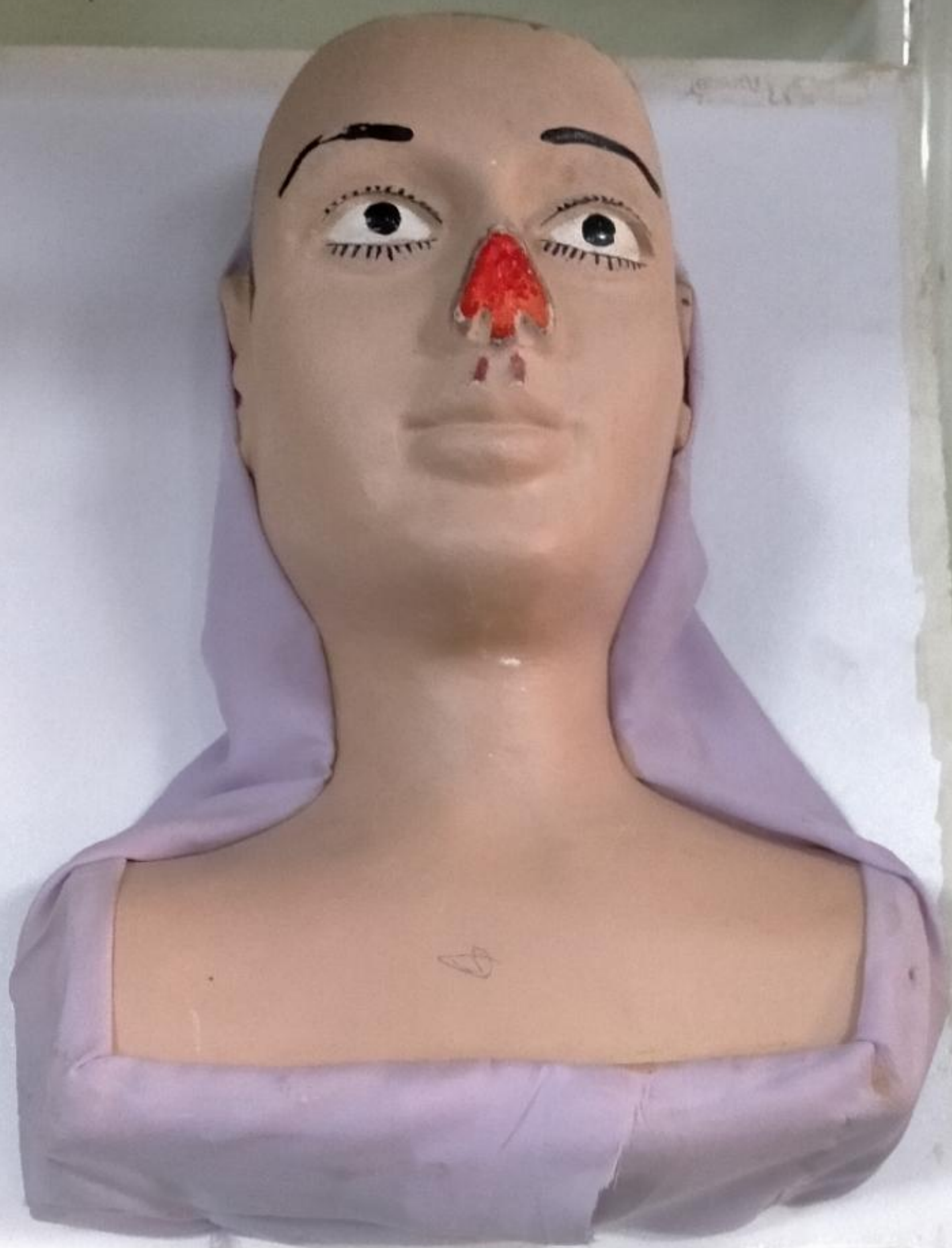Homicidal cut throat

Homicidal cut throat



Pallet Gun Shot






Nose cut with knife

1021 SC SF FORENSIC

Nose cut with knife

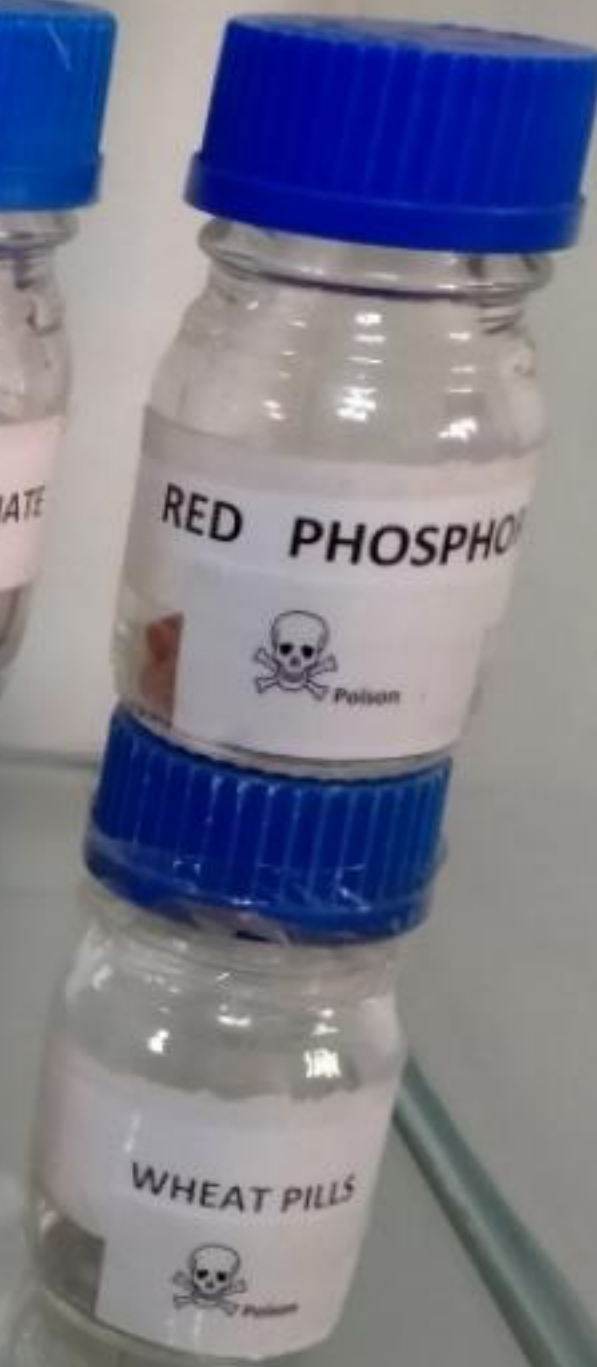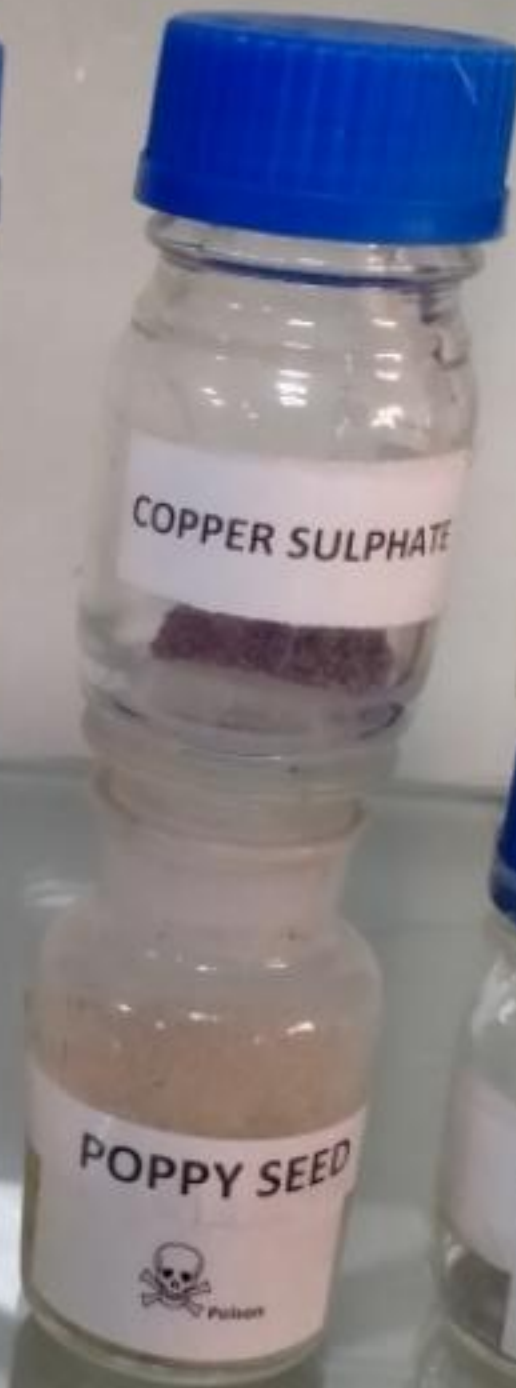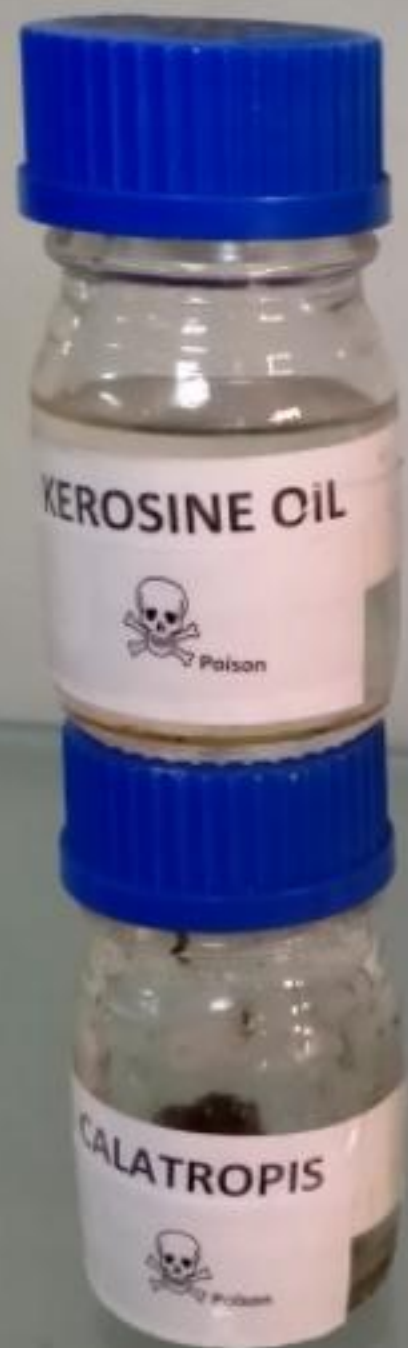Cobra snake

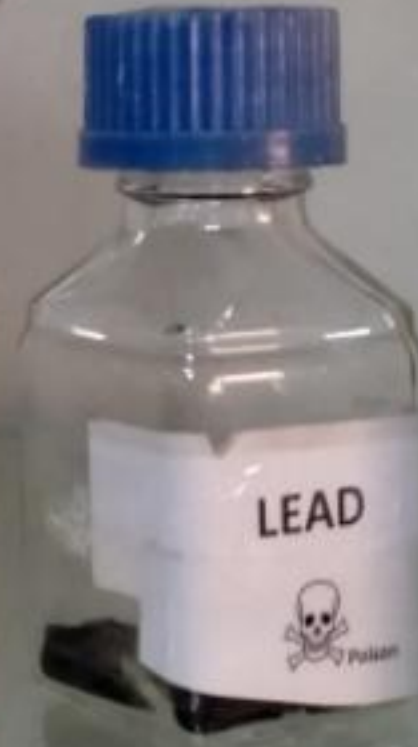
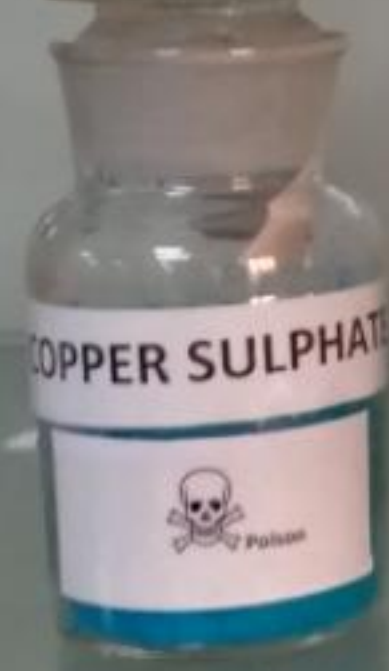
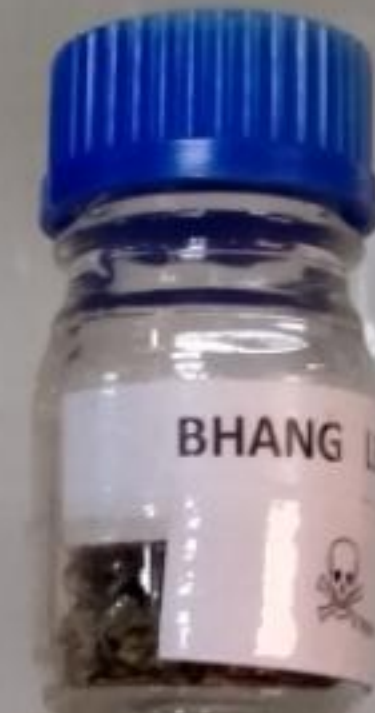
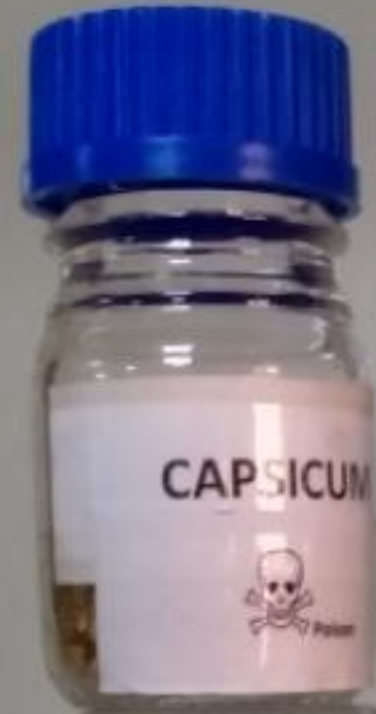

SNAKE







HEAD



CASTOR OIL



5/1/20

LEAD




BHANG

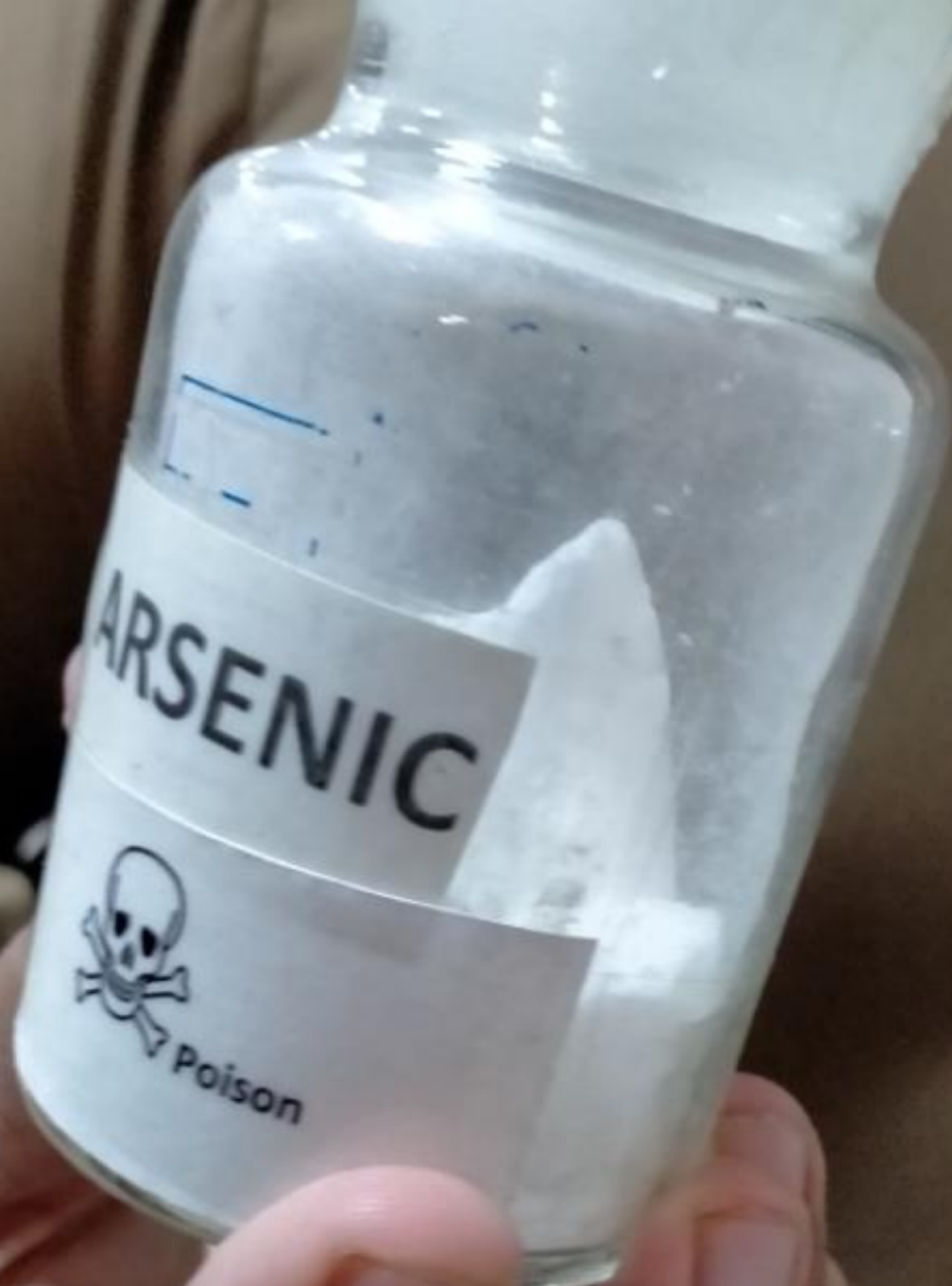


CAPSIC





GENIC





PHATURA SEED



Poison

COPPER SULPHATE





TOBACCO



Poison



CROTON SEEDS



RED PHOS



WHEAT PILLS



Poison

COPPER SULPHATE




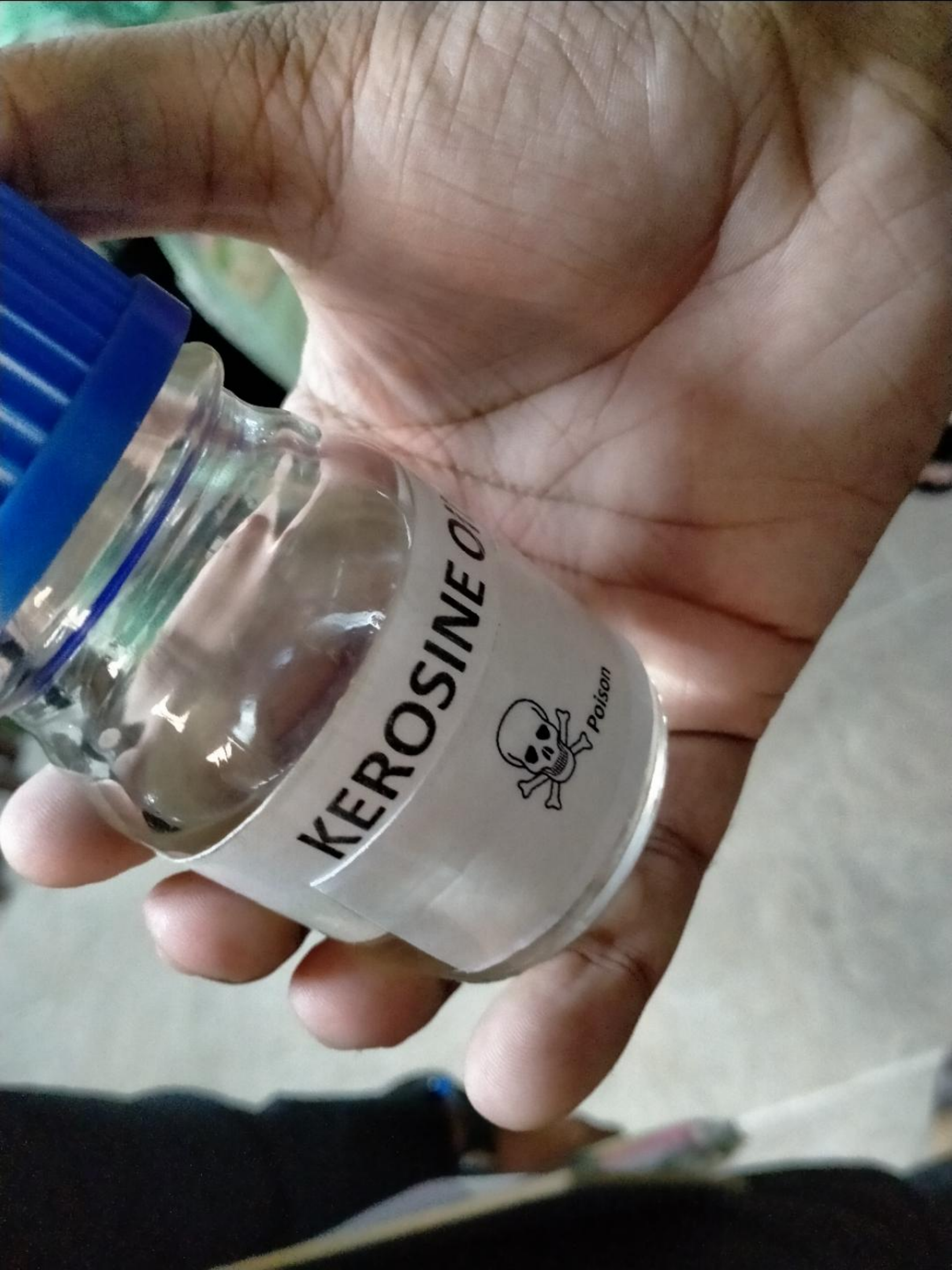
POPPY SEED



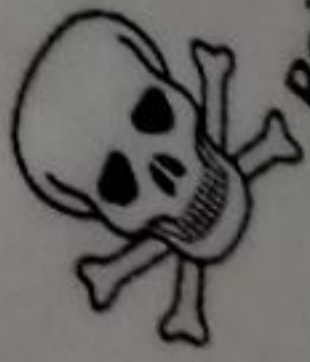Poison

SULPHURIC






KEROPOSINE OIL



Poison

NITRIC






CALATRO



METHYL ALCOHOL



SALICYLIC

