

1 → Ischioanal fossa

2 → Bulbospongiosus

3 → bulb of vestibule

4 → Bartholin's gland

5 → Perineal body

6 → Superficial transverse muscle

7 → Anococcygeal ligament

8 → Gluteus Maximus

9 → Deep transverse perineal muscle

1 → Pubic symphysis

2 → Bladder

3 → Uterus

4 → Urethra

5 → Vagina

6 → Posterior fornix

7 → Cervix

8 → Rectum

9 → Anal Canal

10 → Ischioanal fossa

11 → Ureter

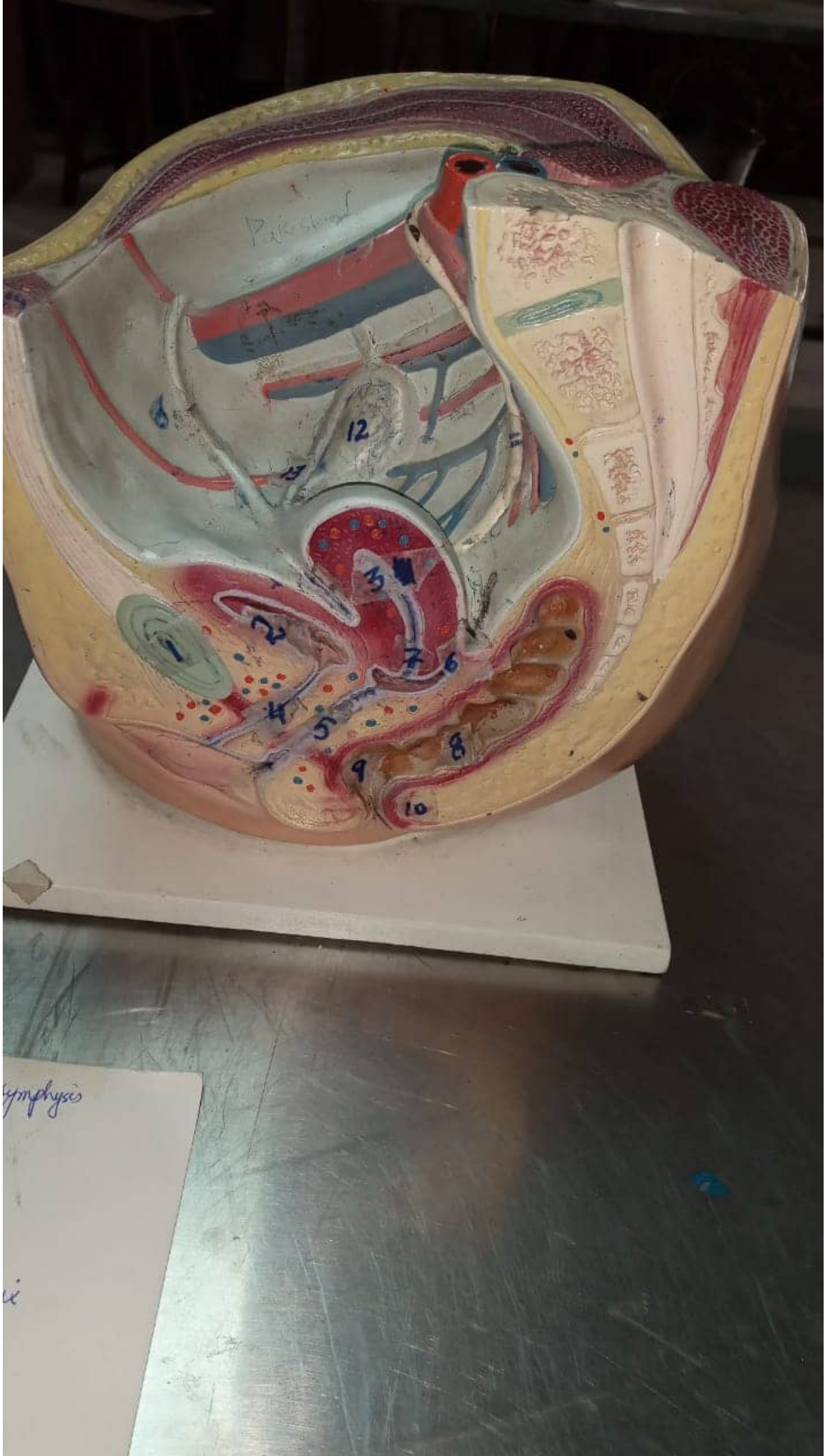
12 → Ovary

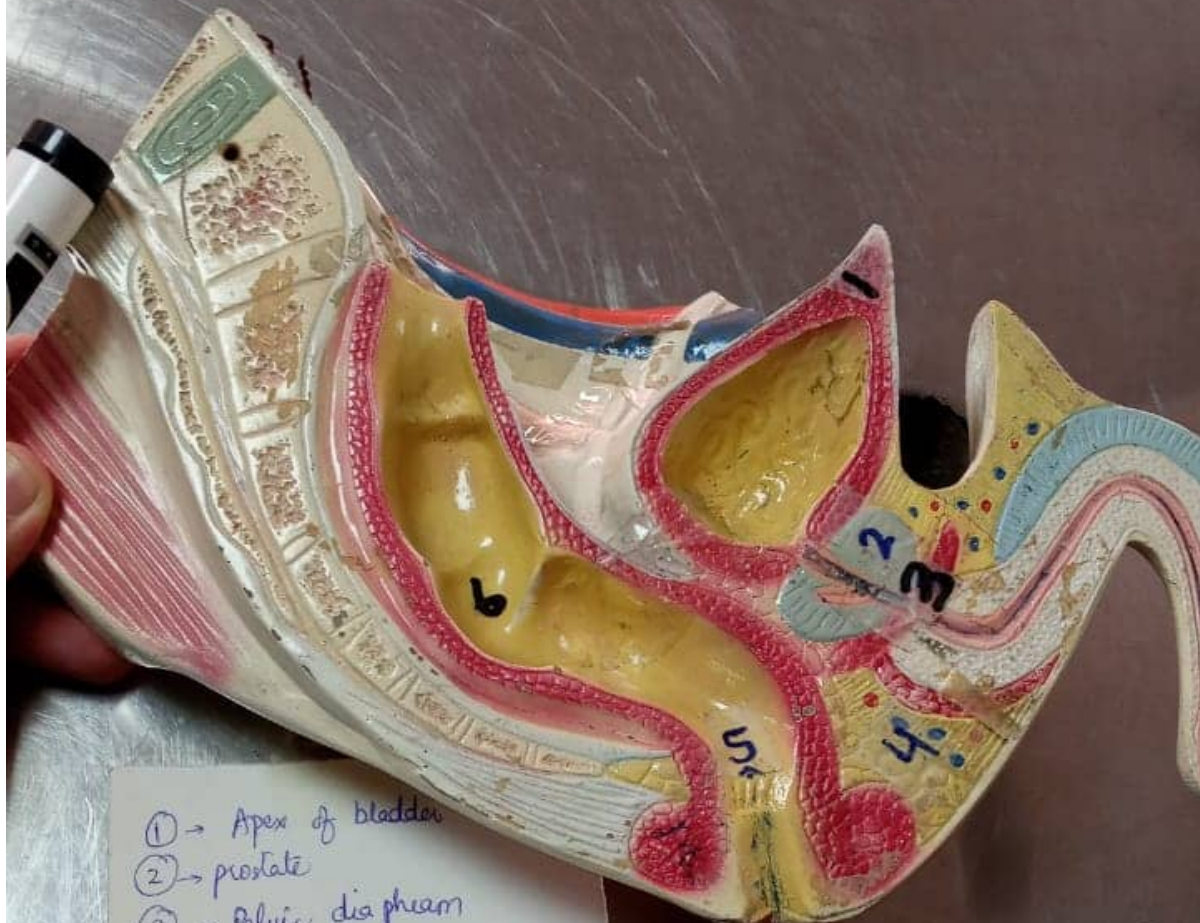13 → Fallopian tube

14 → Rectus Abdominis

15 → External Iliac Artery

16 → Internal iliac vein





- ① → Apex of bladder
- ② → prostate
- ③ → Pelvic diaphragm
- ④ → Ischioanal fossa
- ⑤ → Anal valves
- ⑥ → prostatic part of Urethra